

of factor VIII and it also releases plasminogen activator from endothelial cells.⁹

Vasopressin has been used to control bleeding from oesophageal varices. Its plasma half life is about 24 minutes and it is most effective when given by infusion. The site of action is probably arteriolar smooth muscle, through an increase in the intracellular concentration of inositol phosphates, which mobilise intracellular calcium, causing contraction. The bronchial and mesenteric arteries both arise directly from the aorta. We hoped to reproduce the effect of pressor agents on the mesenteric vasculature in the bronchial circulation. The effect of the pressor agents in stopping pulmonary bleeding may have been fortuitous; but the immediate termination of profuse bleeding on separate occasions, initially with desmopressin and subsequently with a bolus and infusion of vasopressin, was impressive. We are not aware of any publications describing the action of pressor agents on the bronchial circulation in either man or animals (personal communication from Parke Davis).

There was no difficulty in distinguishing between a large haemoptysis and a haematemesis in this patient. He was observed to cough up a large amount of blood and was grossly breathless with a much smaller reduc-

tion in haemoglobin than when he had previously been admitted for haematemesis.

Severe haemoptysis in chronic lung disease is uncommon and pressor agents should not be used routinely owing to the side effects of water retention and bronchoconstriction. They may, however, have a useful conservative role in the management of patients with cystic fibrosis who have severe lung and liver disease.

- 1 Penketh ARL, Wise A, Mearns MB, Hodson M, Batten JC. Cystic Fibrosis in adolescents and adults. *Thorax* 1987; 42:526-32.
- 2 King AD, Cumberland DC, Brennan SR. Management of severe haemoptysis by bronchial artery embolisation in a patient with cystic fibrosis. *Thorax* 1989;44:523-4.
- 3 Sweezey NB, Fellows K. Bronchial artery embolisation for severe Hemoptysis in Cystic Fibrosis. *Chest* 1990; 97:1322-6.
- 4 Stern RC, Wood RC, Boat TF, et al. Treatment and prognosis of massive hemoptysis in cystic fibrosis. *Am Rev Respir Dis* 1978;117:825-8.
- 5 Jones DJ, Davies RJ. Massive haemoptysis. *Br Med J* 1990;300:889-90.
- 6 Correspondence. Massive haemoptysis. *Br Med J* 1990; 300:1270-1.
- 7 Haponik EF, Chin R. Hemoptysis: clinicians' perspectives. *Chest* 1990;97:469-75.
- 8 Salzman EW, Weinstein MJ, Weintraub RM, et al. Treatment with desmopressin acetate to reduce blood loss after cardiac surgery. *N Engl J Med* 1986;314:1402-6.
- 9 Manucci PM, Aberg M, Nilsson M, Robertson B. Mechanisms of factor VIII increase after vasoactive drugs. *Br J Haematol* 1975;30:81-93.

Thorax 1990;45:976-978

Intercostal arteriovenous fistula due to pleural biopsy

J-H Lai, H-C Yan, S-J Kao, S-C Lee, C-Y Shen

Division of Chest Medicine

J-H Lai
H-C Yan
S-J Kao
C-Y Shen

Division of Chest Surgery

S-C Lee
Tri-Service General Hospital, National Defense Medical Center, Taipei, Taiwan, Republic of China

Address for reprint requests:
Division of Chest Medicine,
Tri-Service General Hospital, 622 Ting Chow Road, Taipei, Taiwan, Republic of China
Accepted 11 June 1990

Abstract

A 32 year old woman had a pleural biopsy for a left pleural effusion, which showed caseating granuloma typical of tuberculosis. When the fourth biopsy specimen was removed considerable bleeding occurred from the puncture site. Four days later a bruit was audible over the punctured area, radiating to the back. Eight days after the procedure the patient had a massive bleed into the left pleural space. Selective aortic angiography showed an arteriovenous fistula between the 9th intercostal artery and vein and a pseudoaneurysm in the intercostal punctured area. Thoracotomy showed bleeding from the site of the pleural biopsy. The intercostal vessels

were ligated and pleural decortication was performed, and the patient recovered uneventfully.

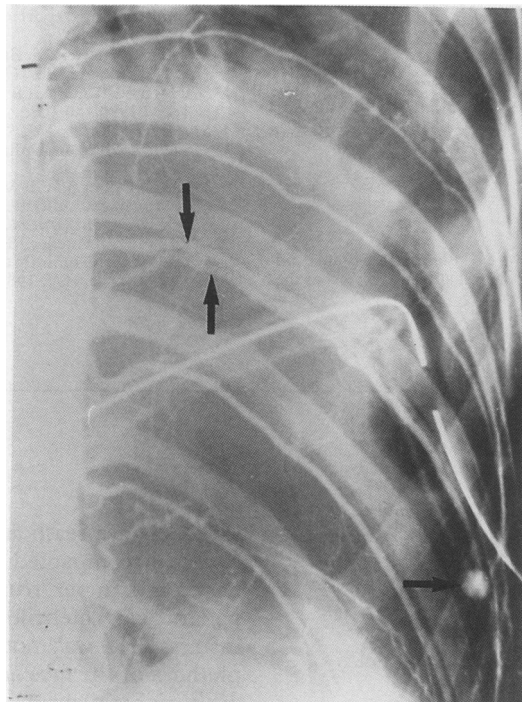
Recently we encountered a previously unreported complication of closed pleural biopsy—namely, the occurrence of a traumatic arteriovenous fistula of the intercostal artery and vein.

Case report

A 32 year old woman was admitted with fever (38.3°C) and a productive cough. There was no history of previous lung disease, chest trauma, or excessive bleeding. She was very slim (36 kg). Physical examination disclosed nothing abnormal apart from dullness to percussion and decreased breath sounds over the left lower lung field. Diagnostic thoracocentesis was performed and 20 ml yellowish serous fluid removed.

The next day a closed pleural biopsy was performed through the 9th intercostal space at the posterior axillary line with a Cope needle. Before biopsy the patient appeared tense and fearful. After injection of a local anaesthetic three pleural specimens were obtained without incident; but when a fourth specimen was

Figure 1 Selective aortic angiogram showing the intercostal artery in 9th intercostal space (↑); the 9th intercostal vein (↓) was opacified during the arterial phase, presumably because of the arteriovenous fistula. The pseudoaneurysm of the intercostal artery is shown (→).



taken blood suddenly gushed from the punctured region and the patient fainted. Her blood pressure was 80/50 mm Hg. After being maintained in the Trendelenburg position for about five minutes she regained consciousness and her blood pressure returned to normal.

Pleural biopsy specimens showed caseating granuloma typical of tuberculosis and antituberculous chemotherapy was started. The patient remained well for four days after the pleural biopsy, though a loud bruit was heard by auscultation over the site of the biopsy, with radiation to the back. The patient refused further invasive diagnostic procedures until eight days after the biopsy, when she fainted suddenly and was found to be hypotensive. A chest radiograph showed that the volume of the left pleural effusion had increased. The haemoglobin concentration had fallen to 7.5 g/dl. Intravenous fluid and a blood transfusion were given, her blood pressure was stabilised, and she regained consciousness. Pleural intubation was accomplished and about 800 ml of grossly blood stained fluid was obtained. Selective aortic angiography disclosed an arteriovenous fistula and a pseudoaneurysm in the 9th left intercostal space at the site of the pleural biopsy (fig 1). A left thoracotomy was performed. A large blood clot and more than 2 litres of fresh blood were found in the pleural cavity. Continuous bleeding was noted at a small puncture site, corresponding to the pleural biopsy area. The intercostal artery and vein were ligated, and pleural decortication performed. The patient recovered uneventfully.

Discussion

Diagnostic thoracocentesis and pleural biopsy have been recognised for decades as valuable invasive diagnostic procedures.¹ Closed pleural biopsy is a blind procedure and traumatic complications are sometimes encoun-

tered. These have included pneumothorax, haemothorax,² pancreatic injury with pseudocyst formation, penetrating injury of the diaphragm or spleen,³ mediastinal emphysema, subcutaneous abscess, subcutaneous haematoma,⁴ empyema,¹ and seeding of malignant cells into the needle tract.⁵ The use of sonographic guided pleural biopsy may reduce these complications, especially for the wall of an encapsulated pleural effusion.⁶

An inadvertent tear of an intercostal artery or vein due to closed pleural biopsy occasionally results in massive haemothorax; but we have been unable to find a report of any similar case of a persistent arteriovenous fistula following pleural biopsy.

Intercostal vessels usually course along the interior aspect of the lower margin of the rib (fig 2). To avoid injury to the intercostal vessels the thoracocentesis or biopsy needle should be inserted immediately above the upper edge of the lower rib and the needle cutting edge should be directed downward.

The specific cause of the intercostal vascular injury in this case is unclear. Movement of the chest wall, unexpected cough, or other mechanical factors could have misdirected the withdrawal channel of the cutting needle. The intercostal arteriogram showed that the intercostal artery and vein were considerably below the inferior margin of the superior (9th) rib, and this may have made these vessels more vulnerable to trauma. It is not clear why the massive intrapleural bleed from the pseudoaneurysm was delayed for eight days. Presumably a haematoma formed initially after the injury to the intercostal artery and vein and this evolved to produce a fistula between the artery and vein, the haematoma producing the pseudoaneurysm. The high pressure within the pseudoaneurysm usually presents some time after the original trauma,

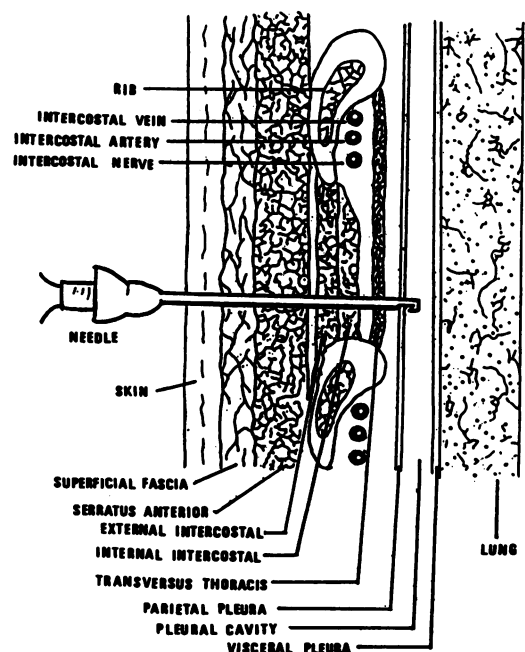


Figure 2 Diagram of the positional relationships between intercostal artery, vein, nerve, ribs, and intercostal space.

and may explain the delayed bleeding in this patient.

This case emphasises the need for care in the selection of a site adjacent to the upper margin of the inferior rib when a pleural biopsy is performed.

- 1 Donohoe RF, Katz S, Matthews MJ. Pleural biopsy as an aid in the etiologic diagnosis of pleural effusion; review of the

literature and report of 132 biopsies. *Ann Intern Med* 1958;48:344-62.

- 2 Morone N, Algranti E, Barreto E. Pleural biopsy with Cope and Abrams needles. *Chest* 1987;92:1050-2.
3 MacDonald RS. Pleural aspiration and biopsy [letter]. *Br Med J* 1980;280:1088.
4 Mestitz P, Purves MJ, Pollard AC. Pleural biopsy in the diagnosis of pleural effusion. A report on 200 cases. *Lancet* 1958;ii:1349-53.
5 Muller NL, Bergin CJ, Miller RR, Ostrow DN. Seeding of malignant cells into the needle tract after lung and pleural biopsy. *J Can Ass Radiol* 1986;37:192-4.
6 O'Moore PV, Mueller PR, Simeone JF, et al. Sonographic guidance in diagnostic and therapeutic intervention in the pleural space. *AJR* 1987;149:1-5.

Thorax 1990;45:978-979

Chylothorax secondary to obstruction of the superior vena cava: a complication of the LeVein shunt

William H Warren, Jeffrey S Altman,
Stephanie A Gregory

Abstract

A case of thrombosis of the superior vena cava was complicated by bilateral chylothoraces and a widened mediastinum. Removal of a clotted LeVein shunt led to prompt resolution of the obstruction and chylothoraces.

Chylothorax is an uncommon result of obstruction of the superior vena cava and other veins, and reported causes include placement of central venous catheters.¹⁻⁶ We describe a case apparently caused by a peritoneovenous shunt.

Case report

A 43 year old man presented in 1984 with pancytopenia and splenomegaly. A diagnosis of hairy cell leukaemia was established by bone marrow biopsy. Splenectomy led to resolution of the pancytopenia. The patient developed malignant ascites and in June 1985 a LeVein peritoneovenous shunt was inserted. The ascites subsequently resolved. The patient was treated with interferon α_2 (3 million units subcutaneously three times a week) from July 1987 to September 1988; haematologically he remained stable and bone marrow biopsy showed evidence of complete remission.

The patient presented to us in September 1988 with a four week history of increasing

shortness of breath and a dry, non-productive cough, accompanied by swelling of the face, neck, and upper trunk. On examination the patient was afebrile and in no respiratory distress. He was noted to have oedema and plethora of the face and upper trunk and signs of a right pleural effusion. There was no abdominal tenderness or clinical evidence of ascites or organomegaly.

Investigations showed a haemoglobin level of 15.5 g/dl, a white cell count of $8.6 \times 10^9/l$ (normal differential count), platelets $440 \times 10^9/l$ and normal serum immunoglobulin concentrations with no monoclonal bands. The prothrombin time and partial thromboplastin time were normal; arterial blood gas analysis with the patient breathing room air showed that pH was 7.40, carbon dioxide tension 5.3 kPa and oxygen tension 10.3 kPa.

A chest radiograph confirmed the large right pleural effusion and showed a small left pleural effusion, a widened superior mediastinum, and the LeVein shunt at the junction of the superior vena cava and the right atrium. Computed tomography of the chest showed a filling defect in the superior vena cava around the shunt. There was no evidence of extrinsic compression of the superior vena cava, though mediastinal and axillary adenopathy was

Department of
Cardiovascular and
Thoracic Surgery
W H Warren

Department of
Hematology
S A Gregory

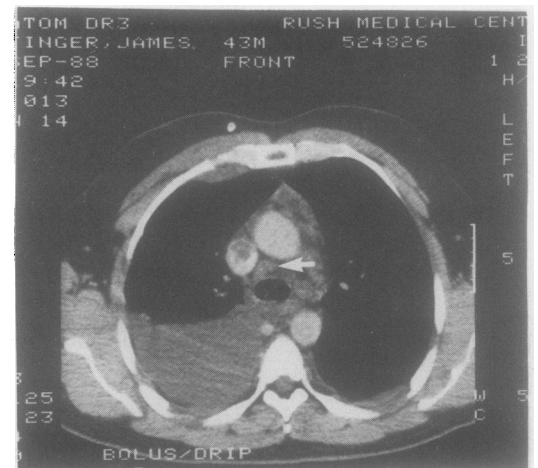
Rush-Presbyterian-
St Luke's Medical
Center

Rush Medical College
J S Altman (medical
student)

Chicago, Illinois, USA

Address for correspondence:
Dr W H Warren,
1725 W Harrison Street,
Chicago, Illinois 60612,
USA.

Accepted 20 June 1990



Computed tomogram showing bilateral chylothoraces, mediastinal lymphoedema, and lymphadenopathy (arrow). Note the thrombus in the lumen of the superior vena cava.