

The use of spacers (static and mobile) in infection knee arthroplasty

Luca Mazzucchelli¹ · Federica Rosso¹ · Antongiulio Marmotti¹ ·
Davide Edoardo Bonasia¹ · Matteo Bruzzone¹ · Roberto Rossi¹

Published online: 22 September 2015
© Springer Science+Business Media New York 2015

Abstract Revision total knee arthroplasty (TKA) is the treatment of choice in patients with periprosthetic joint infection. It may be performed in either a single stage or two stages. In the latter option, between stages, an antibiotic-loaded spacer may be used to maintain a certain amount of joint stability and mobility after the infected implant is removed, adding an intra-articular concentration of antibiotics. There are two types of antibiotic-loaded cement spacers: static and dynamic. Static spacers basically create a temporary arthrodesis with antibiotic-loaded cement and usually are handmade within the surgical field. Dynamic spacers can be created intraoperatively by using different tools or may be prepackaged by the manufacturer; they allow range of motion between stages. In this article, the authors review the indications, surgical

techniques, and results for static and dynamic spacers in two-stage revision TKA.

Keywords Revision total knee arthroplasty · Infection · Spacer · Cement · Treatment

Introduction

Periprosthetic joint infection (PJI), a complication much feared by the orthopedic surgeon, is now one of the most common indications for revision in total knee arthroplasty (TKA) [1, 2].

The latest and best accepted definition of PJI is based on two major criteria: two positive periprosthetic cultures with phenotypically identical organisms and the presence of a sinus tract communicating with the joint. Furthermore, PJI is diagnosed if at least three of six minor criteria are present: elevated serum C-reactive protein (CRP) and erythrocyte sedimentation rate (ESR), elevated synovial fluid white blood cell count (WBC), elevated synovial fluid polymorphonuclear neutrophil percentage (PMN%), positive histologic analysis of periprosthetic tissue, or a single positive culture [3, 4, 5].

Revision surgery in infected TKA may be very challenging for the orthopedic surgeon and result in inferior clinical outcomes compared with primary TKA [6]. Furthermore, compared with revision TKA from other causes, surgery performed for septic loosening results in higher costs [7]. Revision TKA for PJI may be performed as either a one- or two-stage procedure. One-stage revision TKA exposes the patient to only one operation consisting of removal of the old prosthesis, aggressive and complete tissue debridement, and immediate positioning of the new implant [8]. Several authors have reported decreased morbidity, reduced health

This article is part of the Topical Collection on *Revision Knee Arthroplasty*

Investigation was performed at the Hospital Mauriziano “Umberto I”, Torino, Italy.

✉ Roberto Rossi
rossir@fastwebnet.it

Luca Mazzucchelli
lucamazzucchelli@hotmail.it

Federica Rosso
federica.rosso@yahoo.it

Antongiulio Marmotti
antonio.marmotti@inwind.it

Davide Edoardo Bonasia
davidebonasia@virgilio.it

Matteo Bruzzone
matteo.bruzzone@fastwebnet.it

¹ Department of Orthopedic Surgery, Osp. Mauriziano, Largo Turati, 62, Torino 10100, Italy

care costs, and improved functional results as major advantages of one-stage revision TKA [9, 10].

Two-stage revision TKA, on the other hand, begins with surgery to expose the knee articulation, remove the infected components, completely debride the infected tissue, and implant an antibiotic-loaded cement spacer. Patients receive specific oral or intravenous antibiotic therapy, or both, targeted toward bacteria isolated during the first-stage surgery [11]. Although the ideal duration for antibiotic therapy is not defined, most of the recent literature recommends a 6- to 12-week course [12–15]. Once the infection is eradicated, and CRP and ESR levels return to normal, the second surgery is performed to remove the spacer and implant the revision prosthesis. The latter approach may be performed in most cases of PJI [16, 17] and has a success rate ranging from 37.1 to 100 % [18–20].

In this article, we focus on antibiotic-loaded cement spacers and review the literature regarding indications and results.

Antibiotic-loaded cement spacers

Antibiotic-loaded cement spacers are used routinely in two-stage revision TKA. The goal of two-stage revision TKA is to radically eliminate the infection and to create the healthiest tissue possible for the new implant [21]. Between the two stages, the surgeon's main goal is to prevent soft tissue contraction, which may be difficult to treat during the second-stage implantation [22]. Therefore, it is crucial for the surgeon to maintain a sufficient grade of joint stability while adding an intra-articular concentration of antibiotics and keeping the patient's knee joint free of any foreign infected prosthetic material [23, 24].

Antibiotic-loaded cement spacers may be classified in two types:

1. Static spacers, which do not allow motion through the knee joint
2. Articulating or dynamic spacers, which allow range of motion (ROM) of the knee

Static cement spacers

Definition

Static spacers keep the knee joint in full extension or minimal flexion. Although they prevent movement of the knee, they preserve the joint space and deliver local antibiotic. The static spacer may be considered a temporary antibiotic-loaded knee arthrodesis.

Indications and contraindications

Some authors state that static spacers provide greater relief to infected and congested soft tissues, allowing for better

eradication of the infection [25]. Others report that these devices cost significantly less than articulating spacers [26]. However, several disadvantages have been described that affect both the patient postoperatively and the surgeon intraoperatively during the second stage of the revision.

The main drawback of static spacers is joint stiffness with poor ROM after the second stage of the revision; however, instability and wound healing problems also have been associated with static spacers [27], although less frequently than with use of dynamic spacers. Technical concerns also exist, such as accurate insertion of the rods into the intramedullary canals, the failure of which is associated with exposure difficulty during revision surgery [28]. Furthermore, some authors assert that static spacers usually do not restore the normal anatomic joint contours, particularly in heavier patients, leading to significant bone loss with a higher risk for spacer displacement [29].

Considering all the advantages and disadvantages of static spacers, these devices may be indicated in patients with ligamentous instability, insufficient extensor mechanism, and massive bone loss after infected prosthesis removal, or in cases of a compromised overlying soft tissue envelope [30–32].

Surgical technique

The surgical approach to an infected knee is similar to most revision procedures and is the same for static and dynamic spacers [33]. After the patient is given anesthesia and intravenous prophylactic antibiotics, the knee is prepared for surgery. A longitudinal incision is made along the previous scar, and a medial parapatellar arthrotomy is performed. Tissue and fluid samples should be obtained from representative areas; tissue cultures are preferable because of their increased sensitivity (93 vs. 70 %) and specificity (98 vs. 89 %) compared with swab cultures [34]. Although there is no consensus regarding the number of samples to be taken, sensitivity and specificity are greater with three to six periprosthetic swabs, preferably obtained from the bone interface [35]. Culture specificity should not be reduced by taking more than five samples, especially in cases of less virulent organisms or in patients with recent antibiotic treatment, in whom up to 10 samples may be collected [36]. After samples are obtained, wide surgical debridement and complete synovectomy are performed and all previous components and any remaining cement and necrotic bone are removed [28, 37].

The first step in implanting a static antibiotic-loaded cement spacer is to construct it, a procedure that may be done directly in the surgical field. The typical static spacer consists of two rods fitting in both the femoral and tibial canals and overlapping across the joint space, as well as a parallelepiped cement block to fill the joint space left empty after the implant is removed. For the intramedullary rods, two large Steinman 3-mm pins are completely covered by cement; then, the correct-sized static element is assembled with a cement spacer

block and positioned between the femoral and tibial surfaces. More antibiotic-loaded cement is applied to the femoral surface of the suprapatellar pouch to minimize the quadriceps tendon from scarring down to the distal femur. To obtain the volume of cement needed, two to three 40-g bags of cement typically are required (a total of 80 to 120 g); however, there is no consensus regarding the best method of preparing high-dose antibiotic cement spacers. The cement spacer should have enough antibiotic agent to deliver relatively high doses to local tissues. At the same time, the antibiotic dose should be low enough to prevent weakening of the cement's mechanical properties [38]. Most infections can be treated with a spacer containing vancomycin (1 to 4 g per 40-g package of cement) and gentamicin or tobramycin (2.4 to 4.8 g per 40-g package of cement) [23]. It is crucial to achieve the right tension on the soft tissues, ensuring the implant is neither too loose nor too tight, thus avoiding the increased risk of bone loss during the second step (Fig. 1). A drain is positioned intra-articularly and left in situ for 24 h after surgery.

Articulating cement spacers

Definition

The main characteristic of dynamic antibiotic-loaded cement spacers is that they allow flexion and extension of the knee between the two surgical stages. As with static spacers, maintenance of the joint space and local delivery of antibiotic are the main functions.

Indications and contraindications

The main advantage of an articulating spacer is that it efficiently eradicates infection while allowing range of knee motion during the interval between surgical stages [39].

Revision surgery in patients with an articulating spacer may be easier than in those with a static one [39, 40]. Allowing motion during the surgical stages is useful in

maintaining adequate length and elasticity of the extensor mechanism, preventing scar tissue formation around the knee joint, quadriceps shortening, and capsular thickening and contracture [41], all of which may explain the easier reimplantation during revision surgery [42]. Moreover, the patient's ability to bend the knee increases his or her quality of life between stages, especially if a long period of antibiotic therapy is necessary to eradicate the infection.

No clear contraindications exist regarding the use of an articulating spacer, except in cases in which there is concern over wound healing. Disadvantages of commercially available off-the-shelf dynamic spacers include a limited choice of implant sizes and antibiotic dosages. Handmade mobile spacers also have drawbacks, such as difficulty in maintaining stability and a well-shaped and congruent articular surface [37].

Surgical techniques

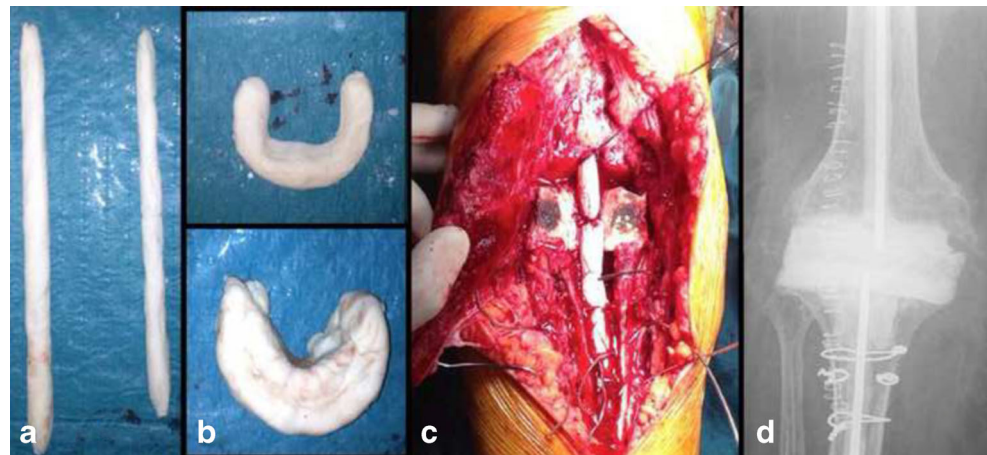
Several techniques have been described for creating a dynamic spacer using different types of interfaces, including cement-on-cement, prosthesis-on-polyethylene, and metal-on-polyethylene constructs [23]. The first steps are the same as those described for static spacer implantation: the surgical approach, extended debridement, synovectomy, and removal of components, with particular care taken to preserve as much healthy bone as possible.

Cement-on-cement interface: molded or preformed spacers

Cement-on-cement spacers fall into two major categories: molded and preformed [43].

Different molds are available commercially in various sizes and dimensions. Custom-made molds can be assembled with standard posterior stabilized TKA provisional components (trials) the same size as the original prosthesis [44]. The cement is loaded with gentamicin (0.5 g per 40-g package) or vancomycin antibiotic powder (3 g per 40-g package); usually, two to three cement packages are enough to complete the

Fig. 1 Antibiotic-loaded cemented static spacer. **a** Handmade intramedullary rods. **b** Handmade spacers for maintaining joint tension. **c** Definitive static spacers. **d** Postoperative radiograph, anteroposterior view



spacer, depending on the requested size. After the correct mold is chosen, the antibiotic-loaded cement is poured into the mold in the late doughy phase until polymerization is achieved. Finally, the mold is removed carefully and the spacers are ready to be implanted [29].

Preformed gentamicin- and/or vancomycin-loaded cement knee spacers (Spacer-K[®] or Vancogenx-Space Knee[®], Tecres, Sommacampagna, Italy) are another valid option. These spacers are available in four different femoral and tibial sizes (small, medium, large, and extra large, respectively, of 60-, 70-, 80-, and 90-mm tibial plateau dimensions) that may be selected intraoperatively. The cement is preloaded with antibiotics by the manufacturer [45].

Regardless of whether the molded or the preformed construct is used, the tibial component is inserted first and cemented to the proximal tibia with additional antibiotic-loaded cement in efforts to preserve the joint line. The femoral unit then is positioned and cemented to the distal femur with more antibiotic-loaded cement. The spacer must adhere strongly to the bone surface while the cement is still in a doughy state, remaining in position until the cement is completely polymerized [46]. At the same time, excessive penetration of the cement into the surrounding bone must be avoided, because it may further damage residual bone stock when the spacer is removed during the second stage.

ROM, patellar tracking, and knee stability are checked carefully [47]. Following the same technique described for static spacers, a drain is inserted in articulation to reduce post-operative hematoma formation.

A slight variation in this technique consists of screwing two 3-mm K-wires in the middle of both femoral and tibial components and covering them with antibiotic-loaded cement. The cement-loaded K-wires act as prosthetic stems and are inserted into the femoral and tibial intramedullary canals. Only the prosthetic components and the proximal part of the stems are then cemented to the articular surfaces, whereas the rest of the stems are left uncemented (Fig. 2). There are two rationales for this slightly different technique. First, it has been demonstrated that up to about one third of infectious processes of the knee are expanded along the intramedullary femoral and tibial canals; therefore, placing a cemented intramedullary stem may help control the infection at this level [48]. Second, in some cases, the lack of a stem may lead to dislocation of the components, eventually leading to wound and vascular problems [49].

In some cases, the premolded spacers may be adapted. Figure 3 shows a premolded articulating spacer used in a case of uni-compartmental knee arthroplasty septic loosening.

Prosthesis-on-polyethylene interface: the Hofmann technique

The history of articulating cement spacers of the knee began in 1995 with Hofmann and colleagues, who described this self-named technique [50].

After standard exposure, irrigation, debridement of all dead tissue, synovectomy, and removal of all components and cement, the infected femoral prosthesis is cleaned and sent for autoclaving [27]. A new tibial all-polyethylene insert is placed on the tibial plateau and in same surgical time; when the femoral component returns from sterilization, it is reimplanted and articulated with the polyethylene insert. Both components then are cemented in place loosely to avoid rigid fixation [50].

Metal-on-polyethylene interface: PROSTALAC[®]

The metal-on-polyethylene technique consists of a special dynamic knee spacer called PROSTALAC[®] (acronym for *prosthesis with antibiotic-loaded acrylic cement*; DePuy Synthes, Warsaw, IN) made up of two parts: a femoral and a tibial component. Each component contains antibiotic-loaded cement, associated with a bicondylar metal shell on the femoral component and a complementary polyethylene section on the tibial one. These spacers are available in different sizes and thicknesses and result in low-friction articulation of metal on polyethylene [51]. This system, developed in 1987, is derived from a posterior-stabilized design that currently is in use [52].

Results of static versus articulating spacers

The literature contains many studies comparing the results of static versus dynamic spacers in terms of ROM, clinical function scores, infection eradication rate, amount of bone loss, surgical ease, and complications.

In the past decades, two-stage knee revision surgeries in patients with PJI were performed using static spacers and a less than satisfactory knee ROM was observed [53]. In 2013, Voleti et al. [30] presented a systematic review comparing outcomes from the use of static and articulating spacers. They evaluated reinfection rates, ROM after second-stage surgery, functional scores, and wound-related and spacer-related problems. The authors analyzed combined level III and level IV comparative studies including a total of 1526 patients, 654 of whom were treated with static spacers and 872 of whom were treated with articulating ones. None of the studies demonstrated a statistically significant difference in terms of reinfection rates between the two treatment groups (mean of 12 % for static and 8 % for articulating spacers, with $P=0.1$ and confidence intervals set to 95 %). However, the authors noted a statistically significant variation in knee ROM after second-stage surgery, with better ROM in the articulating spacer group (91° vs. 101°). Despite this difference in terms of motion, though, no significant differences were detected in functional outcomes assessment (Hospital for Special Surgery Score [HSS] and Knee Society Scoring [KSS]) or wound-related complications (8 % in static spacers and 2 % in dynamic ones) among the different spacers. However, because of the low rate of complications in the analyzed studies, the

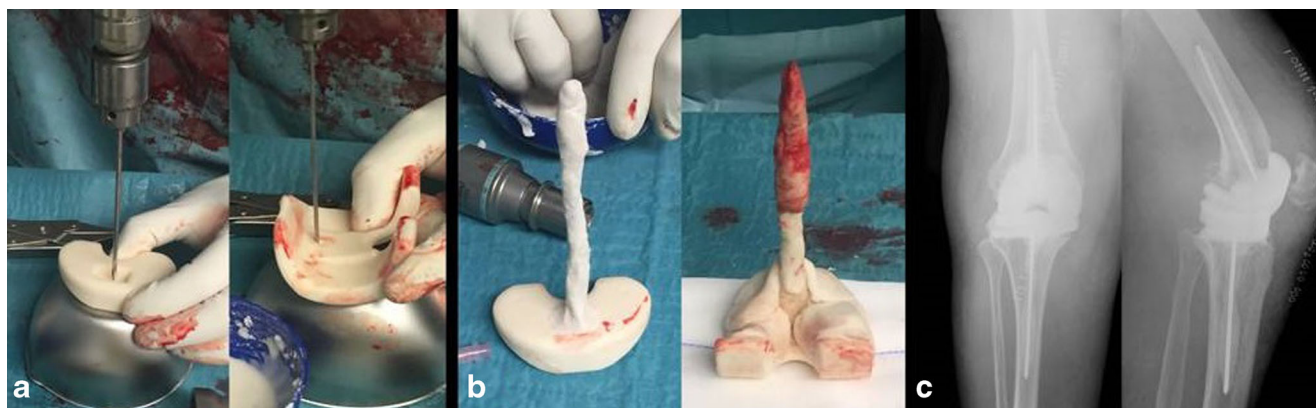


Fig. 2 Antibiotic-loaded dynamic cement spacer. **a** Preparing the intramedullary rods using a K-wire. **b** The intramedullary handmade rod is covered by antibiotic-loaded cement. **c** Postoperative anteroposterior and lateral view radiographs

review was underpowered for evaluating a significant difference in complication rates after static or mobile spacer implantation.

Pivec et al. [54] studied a population of 707 patients with static spacers and 962 with articulating spacers and detected a statistically significant difference in the average ROM finally achieved by the patients. However, they found no statistically significant differences in KSS between the groups. Regarding infection eradication rate and mean percentage of reinfection (PRI) between the two groups, the authors noted no statistically significant differences (mean PRI, 9.7 % for static and 7.9 % for articulating spacers; $P=0.35$). In this casuistry, the most relevant complications resulted in delayed wound healing, aseptic loosening, deep venous thrombosis, and

patellar injuries, with no statistically significant differences between static and articulated spacers (10.7 % for the statics, 6.9 % for the complex articulating spacers, and 5.8 % for the articulating spacers). Furthermore, no differences in terms of additional complications were detected between the groups (2 vs. 3 % reoperation rate).

In their systematic review, Guild et al. [55] found comparable results regarding ROM but slightly different outcomes in reinfection rates. The authors analyzed 47 studies, including 2011 two-stage revision TKAs, 924 using static and 1087 using dynamic spacers. A subanalysis was added to the study that separated complex cases (positive culture for a virulent organism such as methicillin-resistant *Staphylococcus aureus*, Gram negative or polymicrobial; Anderson Orthopaedic

Fig. 3 Antibiotic-loaded cemented dynamic spacer used as a uni-compartmental spacer. **a** Preoperative X-rays (anteroposterior and lateral view). **b** Intraoperative preparation of the uni-compartmental spacer dividing the premolded one in two parts. **c** Intraoperative picture showing the mono-compartmental spacer in situ. **d** Postoperative X-rays of the dynamic mono-compartmental spacer (anterior and lateral views)

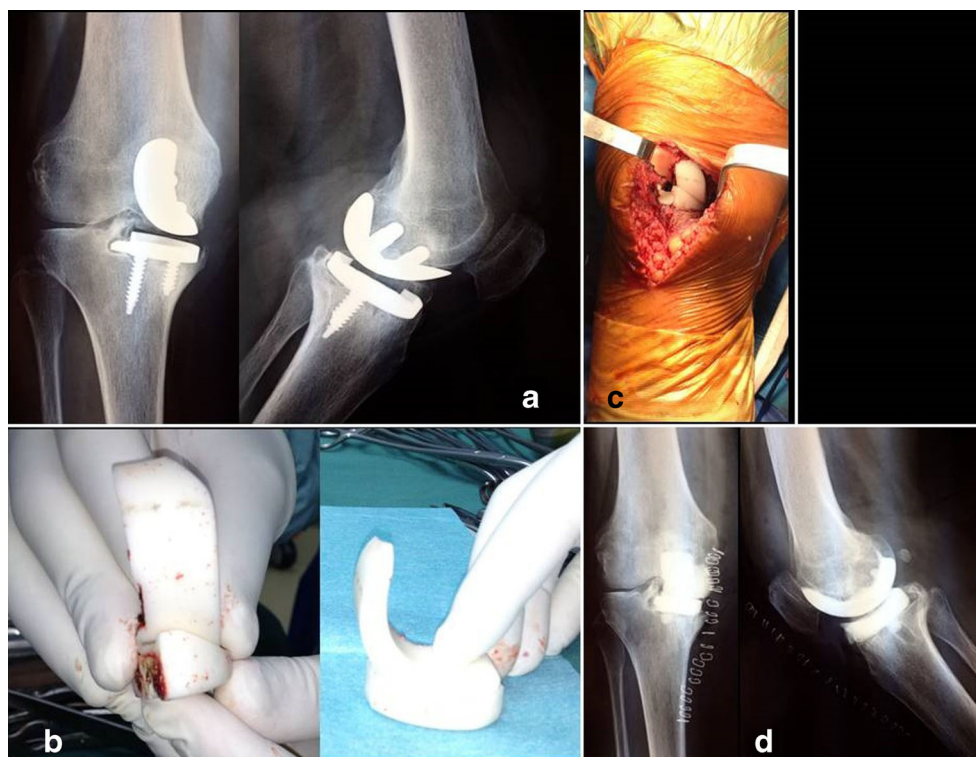


Table 1 Summary of the most recent and relevant literature on outcomes of antibiotic-loaded cement spacers

Author	Year	Knees	Spacers (A or S)	Average ROM at follow-up	Infection eradication rate (%)	Complications
Anderson et al. [57]	2009	25	A	115°	96	No mention
Cai et al. [42]	2012	23	A	100°	91,3	No complications
Chiang et al. [58]	2011	43	22 A 21 S	113° in A 85° in S	95 in A 90 in S	Lower incidence and easier re-implant in A
Choi et al. [40]	2012	47	14 A 33 S	Improved	71 in A 67 in S	Less frequent extensile surgical approaches in A
Cuckler et al. [59]	2005	44	A	110°	97	No mention
Durbhakula et al. [46]	2004	24	A	104°	92	No mention
Emerson et al. [60]	2002	48	22 A 26 S	107,8° in A 93,7° in S	91 in A 92,4 in S	Late reinfection rate of 23% in S
Evans et al. [61]	2004	31	A	Improved	93,5	No mention
Fehring et al. [62]	2000	55	30 A 25 S	105° in A 98° in S	93 in A 88 in S	Important bone losses in S and easier re-implant in A
Freeman et al. [63]	2007	76	48 A 28 S	108° in A 98° in S	94,7 in A 92,1 in S	Less frequent extensile surgical approaches in A
Gacon et al. [26]	1997	29	S	95°	82	No mention
Garg et al. [43]	2011	36	A	Improved	100	Two fracture of the spacers
Gooding et al. [51]	2011	115	A	93,2°	98	Surgical complications in 17% of cases
Haddad et al. [52]	2000	45	A	94,5°	91	Related to the extensor mechanism and stability of the knee between stages
Haleem et al. [64]	2004	96	S	No mention	90 at 5 years 77,3 at 10 years	Modest rate of late recurrent infection or mechanical implant failure
Hart et al. [65]	2006	48	A	92°	88	No mention
Hoad-Reddick et al. [66]	2005	59	S	No mention	89	No mention
Hofmann et al. [27]	2005	50	A	104°	90	One patient had a fusion
Hofmann et al. [50]	1995	26	A	106°	100	No mention
Hsu et al. [67]	2008	32	S	88°	86	37.5% of VY quadricepsplasty, 15.6% of quadriceps snip, 10% of patella baja, 10% of extension lag
Hsu et al. [39]	2007	28	21 A 7 S	95° in A 78° in S	91 in A 86 in S	28% of S vs 5% of A required a more extensile approach. 100% bone loss in S 14% of S vs 1% of A of common peroneal nerve palsy
Huang et al. [68]	2006	21	A	97,6°	95	Sic cases of VY quadricepsplasty
Hwang et al. [69]	2012	30	A	No mention	93	One arthrodesis
Jaekel et al. [70]	2012	36	22 A 14 S	No mention	No mention	No mention
Jämsen et al. [71]	2006	34	24 A 10 S	103,7° in A 92° in S	91 in A 75 in S	One amputation in S
Jia et al. [72]	2012	21	A	94,3°	100	No complications
Johnson et al. [49]	2012	115	81 A 34 S	99° in A 95° in S	83 in A 83 in S	More complications in A (subluxation, mechanical failure, fractured component)
Kalore et al. [73]	2012	53	A	96,3°	88,6	No mention
Kohl et al. [74]	2011	16	A	102°	100	No complications
Kotwal et al. [31]	2012	58	S	No mention	83,8	5,4% of quadriceps snips
Lee et al. [75]	2012	20	A	107,6°	95	No complications
MacAvoy et al. [76]	2005	13	A	98°	69	No mention
Macheras et al. [77]	2011	34	A	No mention	91,1	One aseptic loosening
Macmull et al. [32]	2010	19	A	No mention	63	Two amputations
Meek et al. [78]	2004	54	A	87,1°	96	One cement spacer broke
Ocguder et al. [79]	2010	17	A	95°	94,1	Six femoral components broke
Park et al. [28]	2010	36	16 A	108° in A 92° in S	93,7 in A	75% of bone losses in S vs 0% in A

Table 1 (continued)

Author	Year	Knees	Spacers (A or S)	Average ROM at follow-up	Infection eradication rate (%)	Complications
Pascale et al. [80]	2007	14	20 S A	120°	85 in S 100	No mention
Pietsch et al. [81]	2006	33	A	No mention	91	One dislocation of the spacer, one tibia fracture
Pitto et al. [44]	2005	19	A	94°	100	No complications
Qiu et al. [82]	2010	10	A	110°	90	One arthrodesis
Shaikh et al. [83]	2014	15	A	115°	100	One secondary debridement
Shen et al. [29]	2010	17	A	96,7°	94,1	One arthrodesis and one amputation
Siebel et al. [84]	2002	10	A	No mention	100	No mention
Souillac et al. [85]	2006	18	A	Improved	85,7	One dislocation of the spacer
Su et al. [86]	2009	15	A	110°	93,3	No complications
Thabe et al. [41]	2007	20	A	107°	100	No mention
Tigani et al. [19]	2013	38	A	101°	76,4	No mention
Trezies et al. [87]	2006	11	A	No mention	90,9	No mention
Van Thiel et al. [88]	2011	60	A	101,3°	88	One femoral component broke
Villanueva-Martinez et al. [89]	2008	30	A	80°	100	No mention
Wan et al. [45]	2012	33	A	No mention	90,9	No signs of breakage or loosening

A articulated spacers, S static spacers, ROM range of motion

Research Institution [AORI] grade II or III bone loss; or the presence of a draining sinus tract) from the simple ones. The results showed a statistically significant difference in suitability favoring static spacers for use in complex cases. With regard to HSS and KSS function scores, however, there was no significant difference between the static and mobile spacer groups, either preoperatively or postoperatively. Similar to the previously mentioned review, a statistically significant difference in ROM was reported in favor of dynamic spacers ($100.1^{\circ} \pm 1.6^{\circ}$ vs. $89.7^{\circ} \pm 2^{\circ}$). The Guild group also evaluated infection eradication rates and reported a statistically significant difference in favor of articulating spacers. Furthermore, the authors noted a minor adoption of associated technique, such as quadriceps snips or tibial tubercle osteotomies, during the second-stage surgery after use of an articulated spacer. Regarding further bone loss during the period of cement spacer use, the authors noted a highly remarkable lack of extra bone loss with dynamic spacer use (3.3 % of additional bone deficit detected vs. 47.4 %).

Romanò et al. [18] in 2012 presented a review that showed a better infection eradication rate for articulating spacers compared with static ones (91.2 vs. 87 % at 43.5 ± 20.1 months of follow-up).

Table 1 summarizes the most recent and relevant literature on static and dynamic spacers.

At the end of July 2013 in Philadelphia, Dr. Javad Parvizi of the Rothman Institute in Philadelphia and Dr. Thorsten Gehrke of the ENDO Clinic in Germany led a special conference on PJI. After deep analysis and evaluation of all the

available literature on the topic, the participants drafted and finalized a consensus document. Among the various topics covered, the one concerning antibiotic-loaded cement spacers showed some interesting results [56•]. Strong consensus emerged regarding the existence of a functional difference in the use of nonarticulating versus articulating spacers in two-stage exchange arthroplasty, with a superior outcome observed in patients receiving articulating spacers. Functional differences also were evaluated 2 years after reimplantation, resulting in a nonsignificant tendency toward an ROM increase after use of articulating spacers compared with static ones. The technical ease of reimplantation surgery also was debated, and despite the lack of studies making direct comparisons, based on anecdotal reports, it appears that use of a dynamic spacer might facilitate second-stage surgery. With the agreement of 89 % of the participants (strong consensus), it appears the type of spacer implanted does not influence the infection eradication rate in TKA revision for infection. Also, among the various types of mobile spacers in use (PROSTALAC, Hofmann technique, cemented molds, and Spacer-K), control of infection does not appear to differ significantly, even between manufactured spacers and surgeon-made dynamic spacers.

Conclusions

Antibiotic-loaded cement spacers are fundamental in two-stage revision TKA. They help maintain a grade of joint

stability, add an intra-articular concentration of antibiotics, and keep the patient's knee joint free of any foreign infected prosthetic material during infection eradication. Both static and dynamic spacers are effective in eradicating the infection.

According to the literature, no clear differences exist between the two types of spacers; however, articulating spacers appear to have superior functional outcomes and result in easier reimplantation, allowing a degree of ROM between the stages. There is some agreement in the literature regarding the conclusion that the type of spacer implanted does not influence the infection eradication rate in TKA revision for infection.

Compliance with Ethics Guidelines

Conflict of Interest The authors have no conflict of interests.

Human and Animal Rights and Informed Consent This article does not contain any studies with human or animal subjects performed by any of the authors.

References

Papers of particular interest, published recently, have been highlighted as:

- Of importance

1. Parvizi J, Adeli B, Zmistowski B, Restrepo C, Greenwald AS. Management of periprosthetic joint infection: the current knowledge: AAOS exhibit selection. *J Bone Joint Surg (Am Vol)*. 2012;94:e104.
2. Bozic KJ, Kurtz SM, Lau E, Ong K, Chiu V, Vail TP, et al. The epidemiology of revision total knee arthroplasty in the United States. *Clin Orthop Relat Res*. 2010;468:45–51.
3. Parvizi J, Zmistowski B, Berbari EF, Bauer TW, Springer BD, Della Valle CJ, et al. New definition for periprosthetic joint infection: from the Workgroup of the Musculoskeletal Infection Society. *Clin Orthop Relat Res*. 2011;469:2992–4. **This milestone paper defines the term periprosthetic joint infection.**
4. Workgroup Convened by the Musculoskeletal Infection S. New definition for periprosthetic joint infection. *The Journal of arthroplasty*. 2011;26:1136–8
5. Della Valle C, Parvizi J, Bauer TW, DiCesare PE, Evans RP, Segreti J, et al. American Academy of Orthopaedic Surgeons clinical practice guideline on: the diagnosis of periprosthetic joint infections of the hip and knee. *J Bone Joint Surg (Am Vol)*. 2011;93:1355–7.
6. Lombardi Jr AV, Berend KR, Adams JB. Why knee replacements fail in 2013: patient, surgeon, or implant? *J Bone Joint*. 2014;96-B: 101–4.
7. Oduwole KO, Molony DC, Walls RJ, Bashir SP, Mulhall KJ. Increasing financial burden of revision total knee arthroplasty. *Knee Surg Sports Traumatol Arthrosc*. 2010;18:945–8.
8. Jansen E, Stogiannidis I, Malmivaara A, Pajamaki J, Puolukka T, Konttinen YT. Outcome of prosthesis exchange for infected knee arthroplasty: the effect of treatment approach. *Acta Orthop*. 2009;80:67–77.
9. Oussedik SI, Dodd MB, Haddad FS. Outcomes of revision total hip replacement for infection after grading according to a standard protocol. *J Bone Joint Surg Br Vol*. 2010;92:1222–6.
10. Singer J, Merz A, Frommelt L, Fink B. High rate of infection control with one-stage revision of septic knee prostheses excluding MRSA and MRSE. *Clin Orthop Relat Res*. 2012;470: 1461–71.
11. Osmon DR, Berbari EF, Berendt AR, Lew D, Zimmerli W, Steckelberg JM, et al. Diagnosis and management of prosthetic joint infection: clinical practice guidelines by the Infectious Diseases Society of America. *Clin Infect Dis*. 2013;56:e1–25.
12. Dubee V, Zeller V, Lhotellier L, Kitzis MD, Ziza JM, Mamoudy P, et al. Continuous high-dose vancomycin combination therapy for methicillin-resistant staphylococcal prosthetic hip infection: a prospective cohort study. *Clin Microbiol Infect*. 2013;19:E98–105.
13. Esposito S, Esposito I, Leone S. Considerations of antibiotic therapy duration in community- and hospital-acquired bacterial infections. *J Antimicrob Chemother*. 2012;67:2570–5.
14. Bernard L, Legout L, Zurcher-Pfund L, Stern R, Rohner P, Peter R, et al. Six weeks of antibiotic treatment is sufficient following surgery for septic arthroplasty. *J Infect*. 2010;61:125–32.
15. Whittaker JP, Warren RE, Jones RS, Gregson PA. Is prolonged systemic antibiotic treatment essential in two-stage revision hip replacement for chronic Gram-positive infection? *J Bone Joint Surg Br Vol*. 2009;91:44–51.
16. Cooper HJ, Della Valle CJ. The two-stage standard in revision total hip replacement. *J Bone Joint*. 2013;95-B:84–7.
17. Masters JP, Smith NA, Foguet P, Reed M, Parsons H, Sprowson AP. A systematic review of the evidence for single stage and two stage revision of infected knee replacement. *BMC Musculoskelet Disord*. 2013;14:222.
18. Romanò CL, Gala L, Logoluso N, Romanò D, Drago L. Two-stage revision of septic knee prosthesis with articulating knee spacers yields better infection eradication rate than one-stage or two-stage revision with static spacers. *Knee Surg Sports Traumatol Arthrosc*. 2012;20:2445–53.
19. Tigani D, Trisolino G, Fosco M, Ben Ayad R, Costigliola P. Two-stage reimplantation for periprosthetic knee infection: Influence of host health status and infecting microorganism. *Knee*. 2013;20:9–18.
20. Stammers J, Kahane S, Ranawat V, Miles J, Pollock R, Carrington RW, et al. Outcomes of infected revision knee arthroplasty managed by two-stage revision in a tertiary referral centre. *Knee*. 2015;22: 56–62.
21. Iarikov D, Demian H, Rubin D, Alexander J, Nambiar S. Choice and doses of antibacterial agents for cement spacers in treatment of prosthetic joint infections: review of published studies. *Clin Infect Dis*. 2012;55:1474–80.
22. Antoci V, Phillips MJ, Antoci Jr V, Krackow KA. The treatment of recurrent chronic infected knee arthroplasty with a 2-stage procedure. *J Arthroplast*. 2009;24(159):e13–7.
23. Jacobs C, Christensen CP, Berend ME. Static and mobile antibiotic-impregnated cement spacers for the management of prosthetic joint infection. *J Am Acad Orthop Surg*. 2009;17:356–68.
24. Incavo SJ, Russell RD, Mathis KB, Adams H. Initial results of managing severe bone loss in infected total joint arthroplasty using customized articulating spacers. *J Arthroplast*. 2009;24:607–13.
25. Faschingbauer M, Bieger R, Reichel H, Weiner C, Kappe T. Complications associated with 133 static, antibiotic-laden spacers after TKA. *Knee Surg, Sports Traumatol Arthrosc* 2015.
26. Antoci V, Phillips MJ, Antoci Jr V, Krackow KA. Using an antibiotic-impregnated cement rod-spacer in the treatment of infected total knee arthroplasty. *Am J Orthop*. 2009;38:31–3.
27. Hofmann AA, Goldberg T, Tanner AM, Kurtin SM. Treatment of infected total knee arthroplasty using an articulating spacer: 2- to 12-year experience. *Clin Orthop Relat Res*. 2005;430:125–31.

28. Park SJ, Song EK, Seon JK, Yoon TR, Park GH. Comparison of static and mobile antibiotic-impregnated cement spacers for the treatment of infected total knee arthroplasty. *Int Orthop*. 2010;34:1181–6.
29. Shen H, Zhang X, Jiang Y, Wang Q, Chen Y, Wang Q, et al. Intraoperatively-made cement-on-cement antibiotic-loaded articulating spacer for infected total knee arthroplasty. *Knee*. 2010;17:407–11.
30. Voleti PB, Baldwin KD, Lee GC. Use of static or articulating spacers for infection following total knee arthroplasty: a systematic literature review. *J Bone Joint Surg Am Vol*. 2013;95:1594–9.
31. Kotwal SY, Farid YR, Patil SS, Alden KJ, Finn HA. Intramedullary rod and cement static spacer construct in chronically infected total knee arthroplasty. *J Arthroplast*. 2012;27:253–9. e4.
32. Macmull S, Bartlett W, Miles J, Blunn GW, Pollock RC, Carrington RW, et al. Custom-made hinged spacers in revision knee surgery for patients with infection, bone loss and instability. *Knee*. 2010;17:403–6.
33. Silvestre A, Almeida F, Renovell P, Morante E, Lopez R. Revision of infected total knee arthroplasty: two-stage reimplantation using an antibiotic-impregnated static spacer. *Clin Orthop Surg*. 2013;5:180–7.
34. Aggarwal VK, Higuera C, Deirmengian G, Parvizi J, Austin MS. Swab cultures are not as effective as tissue cultures for diagnosis of periprosthetic joint infection. *Clin Orthop Relat Res*. 2013;471:3196–203.
35. Atkins BL, Athanasou N, Deeks JJ, Crook DW, Simpson H, Peto TE, et al. Prospective evaluation of criteria for microbiological diagnosis of prosthetic-joint infection at revision arthroplasty. The OSIRIS Collaborative Study Group. *J Clin Microbiol*. 1998;36:2932–9.
36. Zappe B, Graf S, Ochsner PE, Zimmerli W, Sendi P. *Propionibacterium* spp. in prosthetic joint infections: a diagnostic challenge. *Arch Orthop Trauma Surg*. 2008;128:1039–46.
37. Burnett RS, Kelly MA, Hanssen AD, Barrack RL. Technique and timing of two-stage exchange for infection in TKA. *Clin Orthop Relat Res*. 2007;464:164–78.
38. Paz E, Sanz-Ruiz P, Abenojar J, Vaquero-Martin J, Forriol F, Del Real JC. Evaluation of elution and mechanical properties of high-dose antibiotic-loaded bone cement: comparative “in vitro” study of the influence of vancomycin and cefazolin. *J Arthroplast*. 2015;30:1423–9.
39. Hsu YC, Cheng HC, Ng TP, Chiu KY. Antibiotic-loaded cement articulating spacer for 2-stage reimplantation in infected total knee arthroplasty: a simple and economic method. *J Arthroplast*. 2007;22:1060–6.
40. Choi HR, Malchau H, Bedair H. Are prosthetic spacers safe to use in 2-stage treatment for infected total knee arthroplasty? *J Arthroplast*. 2012;27:1474–9. e1.
41. Thabe H, Schill S. Two-stage reimplantation with an application spacer and combined with delivery of antibiotics in the management of prosthetic joint infection. *Oper Orthop Traumatol*. 2007;19:78–100.
42. Cai P, Hu Y, Xie L, Wang L. Two-stage revision of infected total knee arthroplasty using antibiotic-impregnated articulating cement spacer. *zhongguo Xiu Fu Chong Jian Wai Ke Za Zhi*. 2012;26:1169–73.
43. Garg P, Ranjan R, Bandyopadhyay U, Chouksey S, Mitra S, Gupta SK. Antibiotic-impregnated articulating cement spacer for infected total knee arthroplasty. *Indian J Orthop*. 2011;45:535–40.
44. Pitto RP, Castelli CC, Ferrari R, Munro J. Pre-formed articulating knee spacer in two-stage revision for the infected total knee arthroplasty. *Int Orthop*. 2005;29:305–8.
45. Wan Z, Karim A, Momaya A, Incavo SJ, Mathis KB. Preformed articulating knee spacers in 2-stage total knee revision arthroplasty: minimum 2-year follow-up. *J Arthroplast*. 2012;27:1469–73.
46. Durbhakula SM, Czajka J, Fuchs MD, Uhl RL. Antibiotic-loaded articulating cement spacer in the 2-stage exchange of infected total knee arthroplasty. *J Arthroplast*. 2004;19:768–74.
47. Villanueva M, Rios A, Pereiro J, Chana F, Fahandez-Saddi H. Hand-made articulating spacers for infected total knee arthroplasty: a technical note. *Acta Orthop*. 2006;77:329–32.
48. Hanssen AD, Spangehl MJ. Practical applications of antibiotic-loaded bone cement for treatment of infected total replacements. *Clin Orthop Relat Res*. 2004;427:79–85. **This article presents good clinical guidelines for application of antibiotic-loaded cemented spacers.**
49. Johnson AJ, Sayeed SA, Naziri Q, Khanuja HS, Mont MA. Minimizing dynamic knee spacer complications in infected revision arthroplasty. *Clin Orthop Relat Res*. 2012;470:220–7.
50. Hofmann AA, Kane KR, Tkach TK, Plaster RL, Camargo MP. Treatment of infected total knee arthroplasty using an articulating spacer. *Clin Orthop Relat Res*. 1995;321:45–54.
51. Gooding CR, Masri BA, Duncan CP, Greidanus NV, Garbus DS. Durable infection control and function with the PROSTALAC spacer in two-stage revision for infected knee arthroplasty. *Clin Orthop Relat Res*. 2011;469:985–93.
52. Haddad FS, Masri BA, Campbell D, McGraw RW, Beauchamp CP, Duncan CP. The PROSTALAC functional spacer in two-stage revision for infected knee replacements. *Prosthesis of antibiotic-loaded acrylic cement*. *J Bone Joint Surg Br Vol*. 2000;82:807–12.
53. Wang CJ, Hsieh MC, Huang TW, Wang JW, Chen HS, Liu CY. Clinical outcome and patient satisfaction in aseptic and septic revision total knee arthroplasty. *Knee*. 2004;11:45–9.
54. Pivec R, Naziri Q, Issa K, Banerjee S, Mont MA. Systematic review comparing static and articulating spacers used for revision of infected total knee arthroplasty. *J Arthroplast*. 2014;29:553–7. e1.
55. Guild 3rd GN, Wu B, Scuderi GR. Articulating vs. static antibiotic impregnated spacers in revision total knee arthroplasty for sepsis. A systematic review. *J Arthroplast*. 2014;29:558–63.
56. Parvizi J, Gehrke T, Chen AF. Proceedings of the international consensus on periprosthetic joint infection. *J Bone Joint*. 2013;95-B:1450–2. **This article presents some of the most important guidelines on which current practice is based.**
57. Anderson JA, Sculco PK, Heitkemper S, Mayman DJ, Bostrom MP, Sculco TP. An articulating spacer to treat and mobilize patients with infected total knee arthroplasty. *J Arthroplasty*. 2009;24:631–5.
58. Chiang ER, Su YP, Chen TH, Chiu FY, Chen WM. Comparison of articulating and static spacers regarding infection with resistant organisms in total knee arthroplasty. *Acta Orthop*. 2011;82:460–4.
59. Cuckler JM. The infected total knee: management options. *J Arthroplasty*. 2005;20:33–6.
60. Emerson Jr RH, Muncie M, Tarbox TR, Higgins LL. Comparison of a static with a mobile spacer in total knee infection. *Clin Orthop Relat Res*. 2002;404:132–8.
61. Evans RP. Successful treatment of total hip and knee infection with articulating antibiotic components: a modified treatment method. *Clin Orthop Relat Res*. 2004;427:37–46.
62. Fehring TK, Odum S, Calton TF, Mason JB. Articulating versus static spacers in revision total knee arthroplasty for sepsis. The Ranawat Award. *Clin Orthop Relat Res*. 2000;380:9–16.
63. Freeman MG, Fehring TK, Odum SM, Fehring K, Griffin WL, Mason JB. Functional advantage of articulating versus static spacers in 2-stage revision for total knee arthroplasty infection. *J Arthroplasty*. 2007;22:1116–21.
64. Haleem AA, Berry DJ, Hanssen AD. Mid-term to long-term followup of two-stage reimplantation for infected total knee arthroplasty. *Clin Orthop Relat Res*. 2004;428:35–9.
65. Hart WJ, Jones RS. Two-stage revision of infected total knee replacements using articulating cement spacers and short-term antibiotic therapy. *J Bone Joint Surg (Br)*. 2006;88:1011–5.

66. Hoad-Reddick DA, Evans CR, Norman P, Stockley I. Is there a role for extended antibiotic therapy in a two-stage revision of the infected knee arthroplasty? *J Bone Joint Surg (Br)*. 2005;87:171–4.
67. Hsu CS, Hsu CC, Wang JW, Lin PC. Two-stage revision of infected total knee arthroplasty using an antibiotic-impregnated static cement-spacer. *Chang Gung Med J*. 2008;31:583–91.
68. Huang HT, Su JY, Chen SK. The results of articulating spacer technique for infected total knee arthroplasty. *J Arthroplasty*. 2006;21:1163–8.
69. Hwang BH, Yoon JY, Nam CH, Jung KA, Lee SC, Han CD, et al. Fungal peri-prosthetic joint infection after primary total knee replacement. *J Bone Joint Surg (Br)*. 2012;94:656–9.
70. Jaekel DJ, Day JS, Klein GR, Levine H, Parvizi J, Kurtz SM. Do dynamic cement-on-cement knee spacers provide better function and activity during two-stage exchange? *Clin Orthop Relat Res*. 2012;470:2599–604.
71. Jämsen E, Sheng P, Halonen P, Lehto MU, Moilanen T, Pajamäki J, et al. Spacer prostheses in two-stage revision of infected knee arthroplasty. *Int Orthop*. 2006;30:257–61.
72. Jia YT, Zhang Y, Ding C, Zhang N, Zhang DL, Sun ZH, et al. Antibiotic-loaded articulating cement spacers in two-stage revision for infected total knee arthroplasty: individual antibiotic treatment and early results of 21 cases. *Chin J Traumatol*. 2012;15:212–21.
73. Kalore NV, Maheshwari A, Sharma A, Cheng E, Gioe TJ. Is there a preferred articulating spacer technique for infected knee arthroplasty? A preliminary study. *Clin Orthop Relat Res*. 2012;470:228–35.
74. Kohl S, Evangelopoulos DS, Kohlhof H, Krueger A, Hartel M, Roeder C, et al. An intraoperatively moulded PMMA prostheses like spacer for two-stage revision of infected total knee arthroplasty. *Knee*. 2011;18:464–9.
75. Lee JK, Choi CH. Two-stage reimplantation in infected total knee arthroplasty using a re-sterilized tibial polyethylene insert and femoral component. *J Arthroplasty*. 2012;27:1701–6.
76. MacAvoy MC, Ries MD. The ball and socket articulating spacer for infected total knee arthroplasty. *J Arthroplasty*. 2005;20:757–62.
77. Macheras GA, Kateros K, Galanakos SP, Koutsostathis SD, Kontou E, Papadakis SA. The long-term results of a two-stage protocol for revision of an infected total knee replacement. *J Bone Joint Surg (Br)*. 2011;93:1487–92.
78. Meek RM, Dunlop D, Garbuz DS, McGraw R, Greidanus NV, Masri BA. Patient satisfaction and functional status after aseptic versus septic revision total knee arthroplasty using the PROSTALAC articulating spacer. *J Arthroplasty*. 2004;19:874–9.
79. Ocguder A, Firat A, Tecimel O, Solak S, Bozkurt M. Two-stage total infected knee arthroplasty treatment with articulating cement spacer. *Arch Orthop Trauma Surg*. 2010;130:719–25.
80. Pascale V, Pascale W. Custom-made articulating spacer in two-stage revision total knee arthroplasty. An early follow-up of 14 cases of at least 1 year after surgery. *HSS J*. 2007;3:159–63.
81. Pietsch M, Hofmann S, Wenisch C. Treatment of deep infection of total knee arthroplasty using a two-stage procedure. *Oper Orthop Traumatol*. 2006;18:66–87.
82. Qiu XS, Sun X, Chen DY, Xu ZH, Jiang Q. Application of an articulating spacer in two-stage revision for severe infection after total knee arthroplasty. *Orthop Surg*. 2010;2:299–304.
83. Shaikh AA, Ha CW, Park YG, Park YB. Two-stage approach to primary TKA in infected arthritic knees using intraoperatively molded articulating cement spacers. *Clin Orthop Relat Res*. 2014;472:2201–7.
84. Siebel T, Kelm J, Porsch M, Regitz T, Neumann WH. Two-stage exchange of infected knee arthroplasty with an prosthesis-like interim cement spacer. *Acta Orthop Belg*. 2002;68:150–6.
85. Souillac V, Costes S, Aunoble S, Langlois V, Dutronc H, Chauveaux D. Evaluation of an articulated spacer for two-stage reimplantation for infected total knee arthroplasty: 28 cases. *Rev Chir Orthop Reparatrice Appar Mot*. 2006;92:485–9.
86. Su YP, Lee OK, Chen WM, Chen TH. A facile technique to make articulating spacers for infected total knee arthroplasty. *J Chin Med Assoc*. 2009;72:138–45.
87. Van Thiel GS, Berend KR, Klein GR, Gordon AC, Lombardi AV, Della Valle CJ. Intraoperative molds to create an articulating spacer for the infected knee arthroplasty. *Clin Orthop Relat Res*. 2011;469:994–1001.
88. Trezies A, Parish E, Dixon P, Cross M. The use of an articulating spacer in the management of infected total knee arthroplasties. *J Arthroplasty*. 2006;21:702–4.
89. Villanueva-Martinez M, Rios-Luna A, Pereiro J, Fahandez-Saddi H, Villamor A. Hand-made articulating spacers in two-stage revision for infected total knee arthroplasty: good outcome in 30 patients. *Acta Orthop*. 2008;79:674–82.