

Review

Endoscopic palliation of tracheobronchial malignancies

M R Hetzel, S G T Smith

Abstract

The prognosis for tracheobronchial tumours remains poor. Most patients can be offered only palliation. When the main symptom is breathlessness or refractory haemoptysis from a large airway tumour endoscopic treatment may be very effective. Over the last decade most attention has focused on the neodymium YAG laser. This often produces dramatic effects but has some important limitations. In the last few years better techniques for stenting and intrabronchial radiotherapy (brachytherapy) have also been developed.

This article discusses the range of techniques now available and aims to help clinicians decide which patients may benefit from referral to centres providing these techniques.

Selection of cases

To benefit from endoscopic palliation, patients must have a tumour in a major airway that is accessible to bronchoscopy and is causing dyspnoea or haemoptysis. This should be inoperable by conventional surgery. Metastatic disease is not a contraindication provided that the central airway tumour is causing the patient's major symptoms. The ideal tumours for resection techniques are confined to the airway lumen and localised. Many tumours cause extrinsic airway compression in addition, but resection is still beneficial if there is a substantial intraluminal component. Otherwise extrinsic airway compression requires palliation with a stent. Indications for brachytherapy are the same as for resection techniques. Brachytherapy may offer more prolonged but delayed benefit, whereas resection techniques give more immediate relief.

Resection techniques

Resection techniques consist of simple blunt removal of tumour with biopsy forceps alone, diathermy, cryotherapy, and laser photoresection.

BLUNT DISSECTION

Simple removal of tumour with forceps, to judge by anecdotal evidence, saves lives

occasionally but carries a high risk of subsequent asphyxia from haemorrhage. It should be attempted only when no other facilities are available and the patient is judged unlikely to survive the journey to a specialist centre. Cases of successful resection at fiberoptic bronchoscopy have been described in relatively avascular tumours,¹ but we believe that it is practicable only with the rigid bronchoscope, with the use of large biopsy forceps. The rigid bronchoscope can often be pushed past the tumour to establish an airway and it can also be used to tamponade any bleeding from the raw tumour surface.

DIATHERMY

Diathermy has been available for some time, but has received little attention. It is difficult to compare its effectiveness with that of newer techniques. Most workers use a diathermy snare, which can be looped round polypoid tumours. This technique, frequently used in gastroenterology, is unfortunately rarely applicable in the bronchial tree, where truly polypoid tumours are uncommon. The snare is closed with gentle pressure while cutting is performed with the cautery current. Excessive pressure without adequate current may lead to bleeding. More commonly, the snare is closed and used as a diathermy probe, which will vapourise tumour, though smoke production is considerable. Hooper *et al*² described a total of eight cases from their own experience and that of others.³⁻⁵ All treatments were successful, but there was one tracheal fire.

Gerasin *et al*⁶ treated eight benign and six malignant tumours with the diathermy snare. Complete removal of all endobronchial tumour was achieved in 10 cases. Longstanding remission was seen in all cases of benign tumour. In two patients, however, diathermy resection was incomplete and laser resection was used to remove residual tumour. Considerable bleeding occurred in one case, but was satisfactorily controlled. The Storz diathermy resection loop has also been used to debulk tracheal tumours before brachytherapy.⁷

CRYOTHERAPY

Cryotherapy was used as long ago as 1907 in dermatology,⁸ and first applied to the bronchial tree in the mid 1970s.⁹ In Britain the technique has been pioneered by Maiwand.¹⁰ Cryotherapy is performed through a rigid

Department of
Thoracic Medicine,
University College
Hospital, London
WC1E 6AU
M R Hetzel
S G T Smith

Reprint requests to:
Dr Hetzel

bronchoscope with a liquid nitrogen probe to cool the tumour to -70°C ; it is allowed to thaw and then refrozen. Two treatments are given in the first one to two weeks and a further treatment at one month. In a retrospective study of 75 patients (24 tumours of the trachea, 21 of the main bronchus, and 30 of the lobar bronchi), who underwent 202 treatments, 56 were considered to have improved. Eight with a collapsed lung showed persistent re-expansion and a further six showed temporary re-expansion. Twelve did not improve, six deteriorated and one died from other causes. No pulmonary function test data were given. The same group subsequently performed a prospective study in 33 patients with 48 tumour sites (trachea 2, main bronchi 23, lobar bronchi 23).¹¹ Only 19 underwent the intended protocol of three treatments. The other 14 died or were withdrawn, two for further treatment with radiotherapy. Twenty three (70%) reported improvement in symptoms and 19 (58%) showed improvement in at least one pulmonary function test. It was helpful in patients with haemoptysis, causing resolution in four of nine patients with haemoptysis and improvement in two. Seven of the 29 patients with a collapsed lobe improved. There were no appreciable complications and no deaths. The principal disadvantage of this technique appears to be the need for repeated treatments, because the authors considered that attempts to clear the airway in a single treatment would carry a risk of perforation. A probe with an angled tip was used for access to the upper lobes. Flexible probes for easier access to the upper lobes have been described.¹²

LASER PHOTORESECTION

The carbon dioxide laser was used in laryngeal surgery in the early 1970s and was the first laser adapted to tumours in the bronchial tree.¹³⁻¹⁵ The first treatment of a tracheal tumour is usually attributed to La Foret *et al*

in 1976.¹⁶ The carbon dioxide laser (wavelength 10 600 nanometres, invisible near infrared) penetrates to about 1 mm from the tumour surface and its energy is absorbed into cell water. It cuts cleanly, but its coagulating effect is inferior to that of the neodymium YAG laser.¹⁷ It can be transmitted only through rigid optical systems and has to be aligned accurately down the barrel of a rigid bronchoscope.¹⁷ It is now largely confined to ear, nose, and throat surgery.¹⁷ Gilmartin *et al*, however, found a mean improvement in FEV₁ from 52% to 63% predicted and in peak expiratory flow (PEF) from 45% to 53% predicted in 20 patients with central tumours.¹⁸

The argon laser (wavelength 514 nm, visible blue-green) can be transmitted through optical fibres and has been used effectively in the bronchial tree.¹⁹ Because of its blue colour, however, much of its energy is absorbed by haemoglobin, so any blood on the tumour surface greatly reduces its efficiency. The neodymium YAG laser (wavelength 1060 nm, invisible near infrared) is currently the most suitable laser for endobronchial resection. It can be transmitted through optical fibres and penetrates to about 6 mm. It will coagulate vessels of up to 2 mm diameter. It has a destructive effect. Tumour at the centre of the beam is vaporised, but more peripherally carbonisation occurs and vessels shrink and blanch. Debris must be removed rapidly so that anatomical landmarks are not obscured (fig 1). Recently machines with a wavelength of 1320 nm have been introduced. These have theoretical advantages because of higher absorption in water, less absorption in blood, less scattering in tissues,²⁰ greater penetration in vascular tissue, and a better demarcated thermal effect.²¹ No studies comparing it with the 1060 μm laser have been reported.

Many studies have been published on neodymium YAG laser bronchoscopy. Regrettably few obtained objective data. These studies have been concerned with advanced malignant disease, where it is ethically difficult to use control groups, and we are unaware of any studies with untreated control subjects. Many patients have been selected for laser resection because of failure of radiotherapy and chemotherapy, so little objective or randomised comparison with other treatments has been possible. Many studies have combined their results for palliation of malignant disease and for treatment of benign conditions, such as granulation tissue at anastomosis sites after surgical resection. This may make interpretation of the data difficult. All workers have recruited patients with histologically varied lesions. Most authors use symptoms or endoscopic appearance at the end of treatment, or both, as their criterion for success. This is obviously open to considerable bias in uncontrolled studies. Many studies contain small numbers of patients and describe the learning curve of new groups who have established the technique in their own hospital.

The role of laser photocoagulation specifically for haemoptysis is also difficult

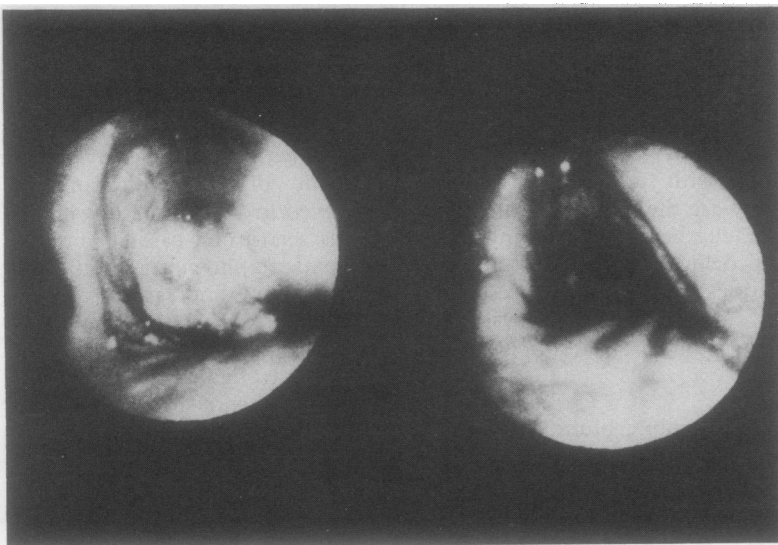


Figure 1 Neodymium YAG laser resection of tumour totally obstructing right main bronchus. Left: laser resection is in progress, with the tip of the laser catheter visible in the 3 o'clock position. Right: the patent right main bronchus can now be seen after clearance of all the tumour by vaporisation and removal of debris with forceps.

Laser palliation of tracheobronchial malignancies

Ref*	n†	Tumours and indication‡	Previous treatment§	Technique	Response			Complications and deaths	Survival	
					Dyspnoea	Physiological	Haemoptysis			
19 (U)	34	34 P C H	19 9 6	16 6 5	LA	14/19 3/9	10/19 0/9 (PEF > 25%)	4/6	C 4/34 M 0/34	1-48 wk 3-60 wk 3-40 wk
22 (J)	15	7 A H	6 1	5	LA	2/6	— —	1/1	M 2/7	—
23 (J)	22	16 A H	13 3	—	LA	12/19**	ABG 1/1	2/3	—	—
24 (F)	200	116			RGA LA	105/116	—	—	—	10/22 at 1 y††
26 (U)	14	14 P C H	8 5 1	7	LA	5/8 3/5	3/8 0/5 (PEF > 25%)	0/1	C 0/14 M 0/14	1-48 wk 3-20 wk 32 wk
27 (U)	100	100 P C H	59 17 24	74	LA RGA	45/59 7/17	37/59 5/17 (PEF > 25%)	14/24	C 1/100 M 2/100	Median 12 wk
28 (A)	22	21		—	LA	20/22	—	—	C 6/22 M 2/22	—
29 (A)	20	20 A H	17 3	15	ETLA ETGA	15/20	ABG 2/4** FEV ₁ 2/3**	3/3	C 6/20 M 2/20	—
30 (A)	55	45		32	ETGA	34/45	FEV ₁ 10/15** FVC 8/15**	—	C 2/55** M 2/55**	Mean 210 d
31 (A)	22	21		—	ETGA	29/32††	—	—	C 7/22** M 2/22**	—
32 (F)	111	63		—	RGA LA	59/63	—	—	C 0/111 M 0/111	—
33 (F)	164	82		“Nearly all”	RGA	74/82	—	—	C 2/164** M 2/164**	9/48 at 1 y**
35 (F)	1310	700**		—	RGA	—	—	—	C 27/700 M 16/700	25% at 1 y**
36 (FIA)	839	—		—	RGA LA	— —	— —	— —	M 7/1503†† C 25/1503††	—
37 (I)	1000	713**		—	RGA LA	612/713*	—	—	C 22/1000 M 5/1000	26%/333 at 1 y
40 (A)	40	38		34	LA RGA	32/40	—	—	C 4/38 M 0/38	—
41 (A)	116	107 P C H	106†† 52†† 30††	77%	ETGA LA	70/106 30/ 52	—	19/30	C 23/176†† M 3/176††	36% 1 y Median 216 d
42 (A)	46	46 P C	27 19	60%	LA RGA	23/27 6/19	FEV ₁ 52-74% FEV ₁ 44-48% (mean % predicted)	—	M 5/46	Mean 5 mo
46 (G)	27	23 P C H	7 11 10	—	LA RGA	5/7 7/11	13/17 (FVC and/or PaO ₂)	6/10	C 3/27 M 1/27	Mean 6 mo

*Reference number with country of origin: A—United States; F—France; G—Germany; I—Italy; J—Japan; U—United Kingdom.

†Total number of patients treated, including non-malignant indications.

‡Number of malignancies treated and, when specified, indication for palliation: A—airway obstruction, site unspecified; P—partial airway obstruction; C—complete airway obstruction; H—haemoptysis (some studies include patients under more than one indication).

§Number of patients with previous treatment—one or more of surgery, chemotherapy, radiotherapy.

||Patients improved/patients treated or mean results with test used: ABG—arterial blood gas; PEF—peak expiratory flow rate; FEV₁—forced expiratory volume in one second; FVC—forced vital capacity. PaO₂—arterial oxygen tension.

**Data incomplete, not obtained in all patients, or including non-malignant cases.

††Data refer to total number of treatments.

RGA—rigid bronchoscope and general anaesthesia; LA—fiberoptic bronchoscope and local anaesthesia; ETGA/ETLA—endotracheal tube, fibroscope, and general/local anaesthesia.

to assess. This is rarely an indication for treatment on its own as most patients also have airway obstruction. This is an important question, however, as some clinicians and radiotherapists would be reluctant to consider external beam radiotherapy for haemoptysis

alone. We suspect that laser photocoagulation may be the most logical initial treatment in the uncommon case of a patient with inoperable disease who has haemoptysis as the dominant symptom.

We have attempted to analyse reports on

laser therapy (table), confining the analysis to papers that appear to have made a useful contribution to the technique and those based on large series of cases.

In the early years treatment under local anaesthesia with the fiberoptic bronchoscope was popular because many workers believed that general anaesthesia would be particularly hazardous in these patients with severely compromised pulmonary function. This approach was developed in France, Japan, and the United Kingdom a decade ago.²²⁻²⁶ These studies produced encouraging results, with 50-60% of patients showing substantial improvements, but they also showed the serious limitations inherent in use of the fibroscope. Smoke induces coughing and limits the duration of treatment that patients can tolerate, so repeated treatments are usually required. This detracts from its benefit as palliative treatment. In addition, postoperative oedema in a partially treated tumour may make airways obstruction worse. The fibroscope is a very poor defence against haemorrhage in an already compromised airway. Haemorrhage is clearly the most common cause of operative death in published reports. Removal of debris is also important and this is very slow with the small biopsy forceps of the fibroscope.

Some workers tried to overcome these problems by using the fibroscope through an endotracheal tube under either local or general anaesthesia.²⁹⁻³¹ Response rates do not appear to be any better, however, and some small studies had operative mortalities in the region of 10%.

Modern intravenous anaesthetic techniques have, in fact, proved remarkably safe in these high risk patients. Most workers now prefer to use the rigid bronchoscope under general anaesthesia, a technique introduced by French workers. Dumon *et al* use spontaneous ventilation with the laser fibre and a telescope held loose in the bronchoscope tube.^{24 32 36} Toty *et al* use a modified Storz rigid bronchoscope with positive pressure ventilation provided by a Sanders injector, an additional suction channel welded on to the outside of the bronchoscope tube, and the laser fibre manipulated in a rigid articulating device.³³ In Britain Moghissi *et al* developed a similar instrument based on the Negus bronchoscope.³⁴ We prefer to use the fibroscope to manipulate the laser fibre through the rigid bronchoscope.²⁷ This approach combines the safety of the rigid bronchoscope with the manoeuvrability of the fibroscope (fig 2).

As the table shows, rigid bronchoscopy is generally associated with the best results, most studies indicating response rates of over 75% in patients with obstruction of the major airways. We have retrospectively compared the results in our unit for 51 patients treated under local anaesthesia with those for 46 patients treated with rigid bronchoscopy and general anaesthesia and found non-significant trends in favour of rigid bronchoscopy for mean improvement in PEF, interval before relapse, and length of hospital stay.³⁸ There was an important and statistically significant difference in the number of treatments required initially

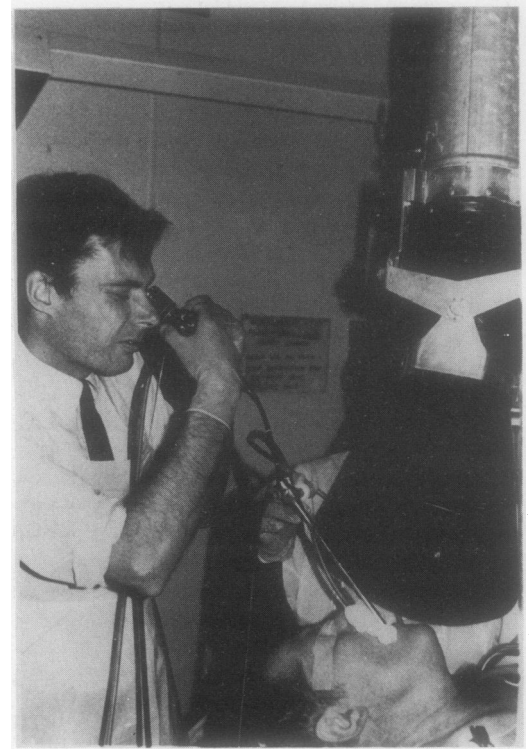

Figure 2 Laser resection by combined use of rigid and fiberoptic bronchoscopes. The laser is aimed by passing it through the biopsy channel of the fiberoptic bronchoscope, which has been fitted with a laser safety filter in the eyepiece. The large suction hood removes smoke exhausted from the rigid bronchoscope.

to clear the airway. This was invariably one with the rigid bronchoscopy, whereas a mean of two treatments was required with the fibroscope. Two operative deaths from haemorrhage occurred with the fibroscope.

Thus treatment with the rigid bronchoscope is more efficient and safer. Some large studies using predominantly rigid bronchoscopy suggest very low operative mortality rates, in the range of 0.3-2.7%.³⁵⁻³⁷ Authors have probably varied, however, in their enthusiasm for reporting complications and in their views on what constitutes an important complication. We recently attempted a more critical review of complications and mortality in 200 consecutive patients treated at University College Hospital; the first 33 were treated under local anaesthesia before we adopted general anaesthesia as our preferred technique.³⁹ This study also favours rigid bronchoscopy. Perioperative mortality (dying during treatment or before leaving hospital) was 6% for local and 1.5% for general anaesthesia. Complications occurred in a third of patients having local anaesthesia and in 9% of those having general anaesthesia. The complications resulted in a longer hospital stay but did not detract from the eventual palliative benefit. Deaths were mainly due to haemorrhage and infection. The main complications were haemorrhage (5%), infection (5%), fibrinous exudate requiring repeat bronchoscopy (2.5%), cardiac (3%) and neurological complications (2.5%), and transient pulmonary oedema (2%). Pneumothorax was surprisingly rare (four cases). These figures all represent results per patient. As most patients undergo at

least one further treatment for relapse during their survival period, the "per treatment" risk is reduced by about half. Arguably this may give more sensible figures for patients to consider when deciding whether they want to accept an initial attempt at palliation with the laser.

A few studies have attempted measurement of pulmonary function for objective confirmation of response. We used PEF and visual analogue scores in an early study of 34 patients and a later study of 100 patients.^{19,27} In the larger study an improvement in PEF of at least 25% was seen in 37 of 59 (63%) cases of partial airways obstruction. Symptomatic improvement as expressed by visual analogue scores was greater at 76%. Of 17 patients with collapse of a lung, re-expansion occurred in only five (29%).

Gelb and Epstein studied FEV₁ and vital capacity (VC) systematically in their patients.⁴² Symptoms improved in 23 of 27 cases of incomplete airway obstruction, FEV₁ rising from 52% to 74% of predicted values and VC from 64% to 77%. Symptoms improved in six of 19 patients with complete collapse of a lung and FVC rose from 46% to 59% predicted. Some workers could obtain lung function data both before and after operation in only a few of their patients. Nevertheless, in most patients with an improvement in dyspnoea this is apparently reflected in the results of simple lung function tests.^{23,29,30}

The table shows only a few patients treated exclusively for haemoptysis, but it suggests a response rate in the region of 60%. Many methods have been used to describe survival and few studies have used survival curves. The very variable survival times also reflect the fact that all studies have included tumours of varying histological type though squamous cell carcinoma always predominates. Many patients clearly survive for six months to a year or more and the palliative benefit of laser resection in improving their quality of life during this time is a very compelling reason for laser treatment.

Laser resection is particularly valuable in re-establishing an airway in patients with a tracheal tumour. In a study of 21 patients with a tracheal tumour (10 primary tumours) 14 presented with life threatening stridor; in 11 of these emergency laser resection achieved improvements in PEF ranging from 26% to 512%.⁴³ The remaining patients, with mainly extrinsic tumour, did not respond to other treatments either and died within a few days. In seven patients who presented less acutely elective laser resection produced an improvement in PEF that ranged from 18% to 117%. Subsequently, five patients underwent radiotherapy with prolonged palliation. The remainder were controlled with laser resection alone. The estimated one year survival was 80% for patients with a primary tumour, 20% for those with a secondary tumour, and 40% for patients presenting as an emergency. In addition to providing rapid palliation of stridor, laser resection of tracheal or carinal tumours occasionally facilitates subsequent

staging, which may then lead to curative surgical resection.⁴⁴

Re-expansion of a collapsed lung by laser resection is difficult because anatomical landmarks are lost and the quality of the underlying lung is unknown. Results are much improved by preoperative bronchography. The fibroscope is used to push an angiography catheter through the tumour and contrast is injected with the aim of identifying distal airways. In a study of 17 cases this technique located a distal airway in 16.⁴⁵ Treatment was attempted in only 15 patients, in whom re-expansion was seen at the first attempt in nine and in three of the four patients in whom a second attempt was made. Thus a positive bronchogram led to successful treatment in 12 of 15 cases. This response rate of 80% compares favourably with those of studies of laser resection without bronchography of—29%,²⁷ 47%,⁴² and 64%.⁴⁶ Most of these results would appear to be superior to the response rates of 21–23% in studies of re-expansion of collapsed lungs with external beam radiotherapy,^{47,48} though one study achieved a rate of 61%.⁴⁹

Infection in re-expanded lungs may lead to fatal pneumonia. This appears to be due to organisms lying dormant in the collapsed lung. Studies of aspirates taken at laser resection show that these grow the same pathogen if clinically significant infection subsequently ensues. It is therefore important to take these specimens so that appropriate antibiotics can be given promptly.⁵⁰

Improving the airway to a completely or partially obstructed lung could have an adverse effect if ventilation alone were improved because the physiological shunt would then increase. Ventilation-perfusion lung scans have therefore been studied before and after laser resection.⁵¹ In a study of 28 patients 21 had a main bronchial occlusion and seven a more distal airway occlusion. Ventilation and perfusion improved in 23 patients (82%). Mean ventilation score (mean counts in treated lung as a percentage of the sum of counts in both lungs) rose from 24 to 36 and perfusion score from 25 to 31. The greatest improvement was seen in cases of main bronchial obstruction where no previous radiotherapy had been given. The poorer response in perfusion suggests that impaired perfusion may be due to the combined effects of reflex vasoconstriction from hypoxia and local invasion or compression of vessels by tumour. Obviously laser resection could improve only the former. Thus laser resection confers a true physiological benefit and these observations may explain why some patients show improvements in symptoms without improved spirometric values.^{27,42} In a similar study using the carbon dioxide laser less improvement was seen in ventilation-perfusion scans, possibly as a result of less good access to more distal airways with the carbon dioxide laser.¹⁸

PHOTODYNAMIC THERAPY

Photodynamic therapy has been studied in similar patients with advanced airway obstruction. Haematoporphyrin derivative is given

intravenously and is retained by tumour cells. Fibreoptic bronchoscopy is performed 72 hours later and red light from an argon dye or gold vapour laser (wavelength 630 and 628 nm) is shone on to the tumour with an optical fibre. Haematoporphyrin derivative has an absorption peak close to these wavelengths and on being activated exerts a cytotoxic effect through formation of singlet oxygen.⁵² Over the next few days tumour sloughs off and has to be removed during follow up bronchoscopy. This technique is expensive and skin photosensitisation is a problem. Studies of the technique do not suggest any superiority over the neodymium YAG laser.⁵³⁻⁵⁵ Moreover, fatal postoperative haemorrhage may occur.⁵⁵ Photodynamic therapy is more valuable for small tumours, in which total ablation may be possible.⁵⁶ Such small tumours can usually be resected surgically, but some studies suggest that for those not suitable for surgery cures or remissions of at least five years are possible with photodynamic therapy.⁵⁷

Which is best?

No comparative studies of laser treatment, diathermy, and cryotherapy have been published. The numerous reports on neodymium YAG laser treatment indicate its popularity despite its much greater capital cost. This popularity is perhaps justified by the data shown in the table, which if pooled suggest an average symptomatic response rate of about 80% in a total of over 2000 patients with malignant airway obstruction. We suspect that the laser is also the easiest instrument to use. For the referring clinician, however, the resection technique used is probably not important.

BRACHYTHERAPY

External beam radiotherapy can treat a relatively large tumour mass, but its palliative value is limited by the cumulative toxicity to surrounding lung, mediastinal structures, and spinal cord, so that a total dose of about 60 Gy cannot normally be exceeded. In brachytherapy isotopes are placed bronchoscopically, producing intense but very localised radiation (the term originates from *brachus*, the Greek for "short"—in this context referring to short distance). Obstructing tumours can thus be repeatedly treated with minimal toxicity to other structures. Isotopes with a short half life can be placed permanently in the airway to decay naturally, but patients then represent a biohazard. Afterloading techniques minimise this by enabling the isotope to be removed after the required exposure time.

Brachytherapy for bronchial tumours has been available since the 1950s. Early work at the Sloan-Kettering Memorial Cancer Center⁵⁸ started with radon-222 and subsequently used iodine-125. In 91 patients treated during 1961-84 with these isotopes the response rate was about 60%, with an average survival of 10 months. The uneven radiation from this source caused appreciable complications, however, particularly haemorrhage and oedema.⁵⁹

Radioactive gold (¹⁹⁸Au) was also introduced

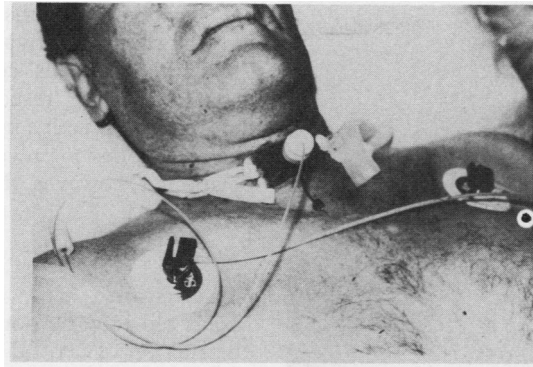
in the 1950s.^{59,60} It has a half life of 2.7 days and emits gamma radiation at 411 KeV. Unwanted beta rays are contained by shielding the gold pellets in platinum. They are usually injected through a long, rigid needle with the rigid bronchoscope. About 14 grains are injected to give a dose of about 60 Gy. After treatment patients must be kept in a side room with lead shields around the bed. Grains may become dislodged, so sputum must be checked with a Geiger counter. It is difficult to space the grains evenly. Nevertheless, Law *et al* achieved good results.⁶¹ Ten of 11 patients with bronchial tumours and distal collapse had substantial re-expansion and palliation was maintained until death in nine cases. Little benefit was seen in five patients with tracheal tumours, however. The same workers subsequently achieved similar results in a further study of 15 patients, but in eight cases of tracheal tumour preliminary debulking with the diathermy snare improved the response. In 11 patients surviving at least one month improvements in FEV₁ ranged from 30% to 120%.⁷

The Sloan-Kettering group in 1984 introduced afterloading with iridium-192 (placing a catheter in a tumour and then loading it temporarily with high activity isotope). They used a Gamma Med II afterloading machine, which drives a high energy iridium source out of a safe and down an afterloading tube.⁵⁸ This was positioned through an endotracheal tube with the use of a fibreoptic bronchoscope into the tumour. A stepping device was used to treat the tumour progressively to a uniform dose (20 Gy at 1 cm delivered in four or five fractions). The response rate was 80%. Macha *et al*, using similar equipment in 56 patients (7.5 Gy 1 cm from the source in four treatments),⁶² obtained a response in 44 patients (79%) and radiological improvement in 22 of 25 with collapse or atelectasis. In 20 patients who underwent spirometry mean FEV₁ improved from 1.6 to 2.1 litres and VC from 2.6 to 3.3 l.

Both these groups use preliminary laser resection in most of their patients to achieve immediate improvement and facilitate placement of the isotope. Mehta *et al* achieved radiological improvement in 73% of 52 patients,⁶³ and improved spirometric values in 14 patients in whom it was measured (increase in FEV₁ from 1.5 to 2.1 litres). The 12 patients who underwent preliminary laser resection apparently had higher complications rates. The authors conclude that brachytherapy alone may be more successful; the laser, however, was probably used in patients with more severe airway obstruction, who might have been expected to do less well.

Burt *et al* used brachytherapy alone, positioning the afterloading catheter with a fibreoptic bronchoscope under local anaesthesia.⁶⁴ An iridium-192 (10 Ci) source was used in a micro-Selection high dose rate afterloading machine with a single exposure of 15-20 Gy 1 cm from the source. Forty six of 50 patients were alive six weeks after treatment. At this time effective palliation had been achieved for haemoptysis (24 of 28 patients—86%);

Figure 3 Manual afterloading technique with low energy iridium-192 wire. A catheter containing iridium wire is passed through a mini tracheostomy. A compression joint is used to secure the catheter in the mini tracheostomy and prevent movement during exposure.



dyspnoea (21 of 33 patients—64%) and cough (nine of 18). Improvement was usually maintained for at least four months; only four patients had needed further radiotherapy at the time of follow up. Radiological collapse resolved in 11 of 24 patients (46%), a result suggesting that preliminary laser resection with bronchography might have improved response rates.⁴⁵

Brachytherapy with afterloading machines is ideal because the brief exposure of 15–20 minutes means that patients can be treated as day cases. The equipment, however, is very

expensive (about £120 000). There are much cheaper alternatives, but the exposure times are longer. Caesium-137 has been used with the Curietron machine (normally used for gynaecological tumours)⁶⁵ with the afterloading catheter placed through a minitracheostomy; exposures of 5–7.5 hours were required. Six of seven patients had immediate benefit and three survived 14–30 weeks. Several workers have used lower energy isotopes, which can be safely handled manually for the brief time needed to insert and remove them. Boedker *et al* used a caesium-137 source in a modified endotracheal tube, with three hour exposures.⁶⁶ Schray *et al* found, remarkably, that most patients could tolerate a catheter passed transnasally by fiberoptic bronchoscope to position low activity iridium-192, which required exposures of 30–60 hours.⁶⁷ Minor haemoptysis caused some problems and one catheter became displaced. Thirteen patients had 18 treatments. Seven of nine patients who had bronchoscopy three months later still had good palliation. Allen *et al* preferred transcrioid placement of the afterloading catheter, using a Seldinger technique.⁶⁸ Apart from two cases of spontaneously resolving surgical emphysema, this was well tolerated with good results in 15 patients. We have recently developed a similar technique (unpublished data), inserting a catheter through a minitracheostomy with an iridium-192 wire (activity 10 mCi/cm) (fig 3). Doses of 30–40 Gy at 1 cm are given and exposure time does not exceed 48 hours. This has been very well tolerated and early results are encouraging. The technique is within the scope of any hospital with an enthusiastic radiation physics department.

Most of the studies cited have used preliminary laser resection and we believe that the two techniques are complementary: laser has the advantage of immediate effect and will give a safe airway, but brachytherapy will usually maintain a longer response. This view is to some extent supported by a study by Jain *et al*, who compared laser resection with external beam radiotherapy.⁶⁹ The two techniques together proved better than radiotherapy alone, and laser was more effective when given before radiotherapy in improving response rates and survival. This study, however, was retrospective with very small numbers (7–9 in each group).

ENDOBONCHIAL STENTS

The use of endobronchial stents is indicated for severe compression of large airways by extrinsic tumour. Preliminary resection of associated intraluminal tumour may sometimes facilitate insertion. Until recently only silastic tube stents were available; long stents required a tracheostomy for insertion and patients had to suck out secretions via a side arm because the mucociliary escalator is compromised. Montgomery developed the basic design for these tubes, which were initially used for subglottic stenoses.⁷⁰ Clarke modified Souttar's oesophageal stent for airway lesions.⁷¹ Cooper *et al* reported 11 cases of malignant tracheobronchial obstruction with good palliation and a

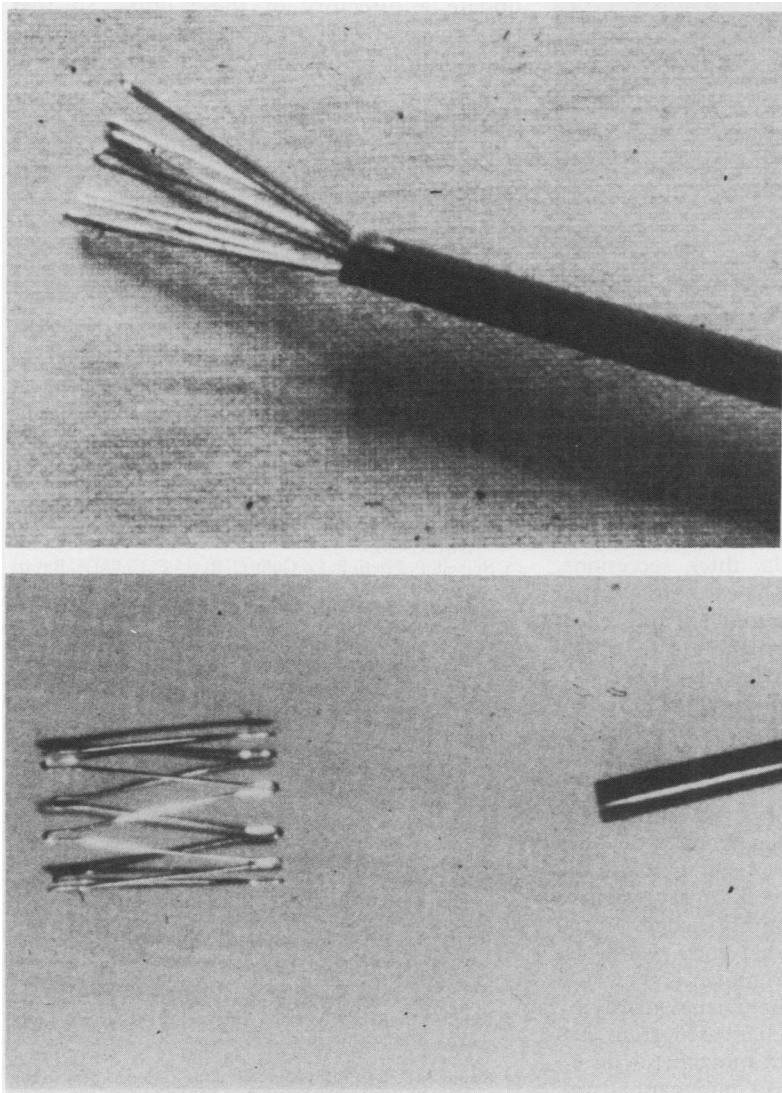


Figure 4 (a) Gianturco stent during release from the catheter. (b) Fully released stent expands to support the airway.

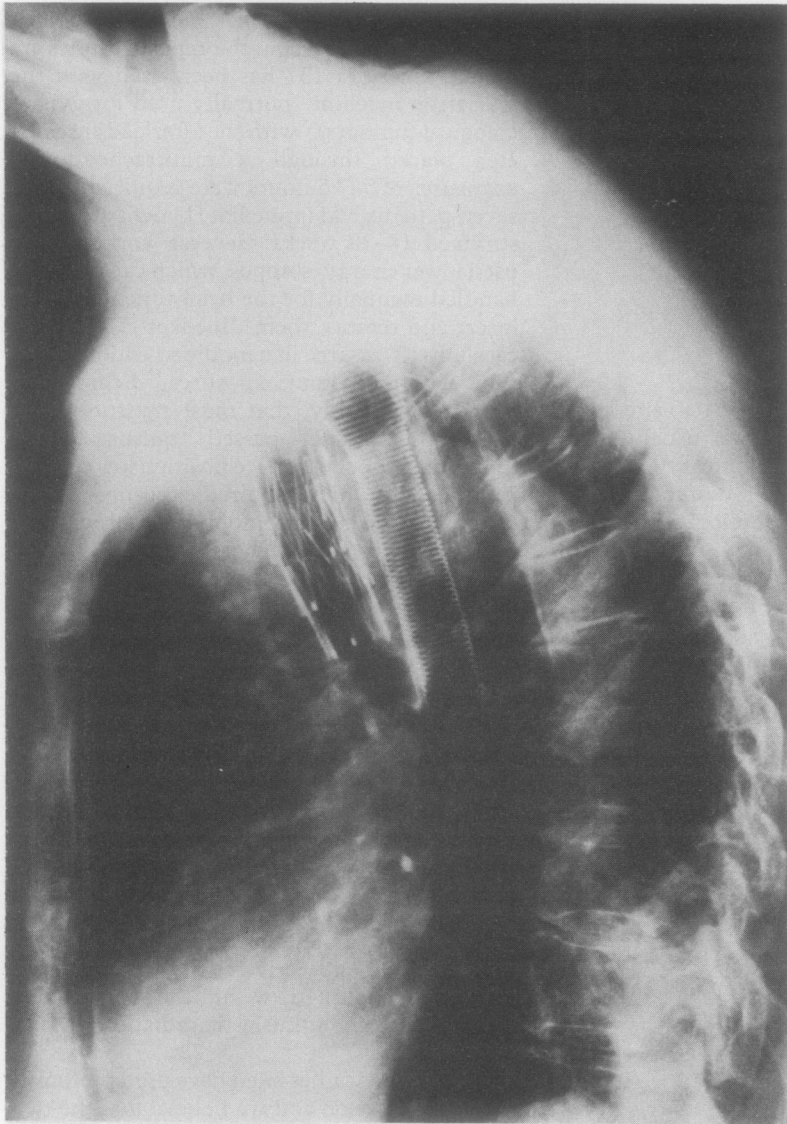

Figure 5 A series of Gianturco stents used to palliate extensive extrinsic tracheal compression from an advanced tracheal carcinoma. This was also causing dysphagia, which has been controlled with an oesophageal stent. This patient gained considerable relief and was able to leave hospital.

mean survival of four months.⁷² Three tubes, however, had to be removed because of tracheo-oesophageal fistula, thick secretions, and interference with the vocal cords. In an emergency even a fenestrated silicone chest drain can be modified to make a satisfactory stent.⁷³ Westaby and Jackson developed a Y shaped tube for carinal and bronchial lesions.⁷⁴

Stainless steel Z stents do not interfere with the mucociliary escalator and a tracheostomy is not required, so they can be inserted by physicians and are more convenient for patients. They are released from a delivery catheter either under direct vision through the rigid bronchoscope or under fluoroscopy with a guide wire placed with the fibroscope. Initial studies in dogs showed that they were well tolerated, but tended to move and would increase the diameter of the normal airway by about one third.⁷⁵ The Gianturco stent has additional hooks to prevent movement (fig 4). Use of these stents in a case of malignant airway obstruction relieved symptoms and improved lung function for four months.⁷⁶ A series of stents can be used to treat strictures of any length (fig 5). If one is accidentally misplaced

across a lobar bronchus this will not be obstructed). Tumour can invade through the mesh of the stent, but this could be controlled by subsequent laser resection. An experimental modified stent with a nylon and PVC cover has been developed to prevent this problem.⁷⁷ Once positioned, however, these stents cannot easily be removed.

Conclusions

Much can now be done to palliate malignant obstruction of central airways. More patients would probably benefit from endobronchial palliation than are currently offered it. These techniques require short admissions to hospital, so patients spend most of their remaining life at home with a good quality of life and reduced cost. These techniques are often best used in combination and we believe that it is important, as in our own unit, to practise all three techniques (resection, brachytherapy, and stenting) so that patients can be rapidly assessed and treatment tailored to the individual case. Currently about a dozen units around the country are using these techniques. With the collaboration of the British Thoracic Society, we hope to establish and regularly update a directory of these units, so that patients can be referred quickly and given the best possible palliation.

Postscript

During the preparation of this review Mr Simon Smith FRCS, research fellow, was tragically killed in a road traffic accident.

- 1 Mehta AC, Livingstone DR. Biopsy excision through a fiberoptic bronchoscope in the palliative management of airway obstruction. *Chest* 1987;91:774-5.
- 2 Hooper RG, Jackson FN. Endobronchial electrocautery. *Chest* 1985;87:712-4.
- 3 Taguchi H, Nagaka T, Kawai H, Saito K, Wakabayashi T. High frequency electrosurgical resection of tracheal obstruction using the flexible bronchoscope. In: Boyd A, Spencer FKC, eds. *Bronchology: research, diagnostic and therapeutic aspects*. The Hague: Nijhoff, 1981:563-5.
- 4 Takizawa N, Oho K, Amemiya R, Hagashi N, Kawachi T, Hayata Y. Electrosurgery via the fiberoptic bronchoscope. In: Boyd A, Spencer FKC, eds. *Bronchology: research, diagnostic and therapeutic aspects*. The Hague: Nijhoff, 1981:559-61.
- 5 Spinelli P, Pizetti P, Lo Gullo C, Rocca F, Gobbi A, Ravari G. Resection of obstructive bronchial fibro-lipoma through the flexible fiberoptic bronchoscope. *Endoscopy* 1982;14:61-3.
- 6 Gerasin VA, Shafirovsky BB. Endobronchial electrosurgery. *Chest* 1988;93:270-4.
- 7 Ledingham SJM, Goldstraw P. Diathermy resection and radioactive gold grains for palliation of obstruction due to recurrence of bronchial carcinoma after external irradiation. *Thorax* 1989;44:48-51.
- 8 Pussey WA. The use of carbon dioxide snow in the treatment of naevi and other lesions of the skin. *JAMA* 1907;49:1354-6.
- 9 Sanderson DR, Neel HB, Payne WS, Woolner LB. Cryotherapy for bronchogenic carcinoma. Report of a case. *Mayo Clin Proc* 1975;50:435-7.
- 10 Maiwand MO. Cryotherapy for advanced carcinoma of the trachea and bronchi. *BMJ* 1986;293:181-2.
- 11 Walsh DA, Maiwand MO, Nath AR, Lockwood P, Lloyd MH, Saab M. Bronchoscopic cryotherapy for advanced bronchial carcinoma. *Thorax* 1990;45:509-13.
- 12 Carpenter RJ, Neil HB, Sanderson DR. Cryosurgery of bronchopulmonary structures. *Chest* 1977;72:279-84.
- 13 Strong MS, Jako GJ. Laser surgery in the larynx. Early clinical experience with continuous CO₂ laser. *Ann Otol Rhinol Laryngol* 1972;81:791-8.
- 14 Strong MS, Jako GJ, Polanyi T, et al. Laser surgery in the aero-digestive tract. *Am J Surg* 1973;126:529-33.
- 15 Strong MS, Vaughan CW, Polanyi T, et al. Bronchoscopic CO₂ laser surgery. *Ann Otol Rhinol Laryngol* 1974;83:769-76.
- 16 La Foret EG, Berger RL, Vaughan CW. Carcinoma obstructing the trachea: treatment by laser resection. *N Engl*

- J Med* 1976;294:941.
- 17 Shapsay M, Bearnis JF. Use of CO₂ laser. *Chest* 1989;95:449-55.
 - 18 Gilmartin JJ, Veale D, Cooper BG, Keavey PM, Gibson GJ, Morrill GN. Effects of laser treatment on respiratory function in malignant narrowing of the central airways. *Thorax* 1987;42:578-82.
 - 19 Hetzel MR, Millard FJC, Ayes R, Bridges C, Nanson EM, Swain CP. Laser treatment for carcinoma of the bronchus. *BMJ* 1983;286:12-6.
 - 20 Frank F, Beck OJ, Hessel S, Keiditsch E. Comparative investigations of the effects of the Nd YAG laser at 1.06 microns and 1.32 microns on tissue. *Lasers in Surgery and Medicine* 1987;6:546-51.
 - 21 Heldwein W, Lehner TP, Wiebecke B, Ruprecht L, Unsold E. Investigation of a new 1.32 nm Nd YAG laser for treatment of bleeding of peptic ulcers—experiments on dog stomach. *Lasers in Medical Science* 1987;2:189-94.
 - 22 Tamada J, Ito M, Teramatsu E. Clinical study of bronchofibrescopic Nd YAG laser surgery. In: Atsumi K, Nimsakul N, eds. *Proceedings of Fourth Congress of International Society for Laser Surgery*. Tokyo: Intergroup Corporation, 1981;14:13-5.
 - 23 Oho K. Laser surgery in the trachea and bronchus via the fiberoptic bronchoscope. In Atsumi K, Nimsakul N, eds. *Proceedings of Fourth Congress of International Society for Laser Surgery* Tokyo: Intergroup Corporation, 1981;14:16-9.
 - 24 Dumon JF, Meric B, Velardachio JM, Garbe L, Saux P. YAG laser resection of tracheo-bronchial lesions. In: Atsumi K, Nimsakul N, eds. *Proceedings of Fourth Congress of the International Society for Laser Surgery*. Tokyo: Intergroup Corporation, 1981:14:28-31.
 - 25 Hetzel MR, Millard FJC, Bridges C, Williams IP. Endoscopic argon laser treatment of bronchial carcinoma—techniques [abstract]. *Thorax* 1981;36:235.
 - 26 Millard FJC, Hetzel MR, Williams IP, Bridges C. Endoscopic argon laser treatment of bronchial carcinoma—results [abstract]. *Thorax* 1981;36:235.
 - 27 Hetzel MR, Nixon C, Edmonstone W, et al. Laser therapy in 100 tracheobronchial tumours. *Thorax* 1985;40:341-5.
 - 28 McDougall JC, Cortese D. Neodymium YAG laser therapy for malignant airway obstruction. *Mayo Clin Proc* 1983;58:35-9.
 - 29 Arabian S, Spagnolo S. Laser therapy in patients with primary lung cancer. *Chest* 1984;86:519-23.
 - 30 Kvale P, Eichendorff M, Radke J, Miks V. Laser photoresection of lesions obstructing the central airways. *Chest* 1985;87:283-8.
 - 31 Warner ME, Warner MA, Lennard PF. Anaesthesia for Nd YAG laser resection of major airway obstructing tumours. *Anaesthesiology* 1984;60:230-2.
 - 32 Dumon JF, Reboud E, Gerbe L, Aucomte F, Meric B. Treatment of tracheo-bronchial lesions by laser photoresection. *Chest* 1982;81:278-84.
 - 33 Toly L, Personne C, Colchen A, Vourc'h G. Bronchoscopic management of tracheal lesions using the Neodymium YAG laser. *Thorax* 1981;36:175-8.
 - 34 Moghissi K, Jessop T, Dench M. A new bronchoscopy set for laser therapy. *Thorax* 1986;41:485-6.
 - 35 Personne C, Colchen A, Leroy M. Indications and technique for endoscopic laser resections on bronchology. *J Thorac Cardiovasc Surg* 1986;91:710-5.
 - 36 Dumon JF, Shapsay S, Bourcereau J, et al. Principles for safety in application of neodymium YAG laser in bronchology. *Chest* 1984;86:163-8.
 - 37 Cavaliere S, Foccoli P, Farina PL. Nd YAG laser bronchoscopy. *Chest* 1988;94:15-21.
 - 38 George PJM, Garrett CPO, Nixon C, Netzel MR, Nanson EM, Millard FJC. Laser treatment for tracheobronchial tumours: local or general anaesthesia? *Thorax* 1987;42:656-60.
 - 39 Smith SGT, Hetzel MR, George PJM. Morbidity and mortality associated with endoscopic laser resection for endobronchial lesions [abstract]. *Thorax* 1989;44:839P.
 - 40 Parr GVS, Unger M, Trout RG, Atkinson WG. One hundred Neodymium YAG laser ablations of obstructing tracheal neoplasms. *Ann Thorac Surg* 1984;38:374-81.
 - 41 Brutinel WM, Cortese DA, McDougall JC, Gillio BG, Bergstralh EJ. A two year experience with the Nd YAG laser in endobronchial obstruction. *Chest* 1987;91:159-65.
 - 42 Gelb AF, Epstein JD. Nd YAG laser in lung cancer. *Ann Thorac Surg* 1987;43:164-7.
 - 43 George PJM, Garrett CPO, Hetzel MR. Role of the neodymium YAG laser in the management of tracheal tumours. *Thorax* 1987;42:440-4.
 - 44 Shankar S, George PJM, Hetzel MR, Goldstraw P. Elective resection of tumours of the trachea and main carina after endoscopic laser therapy. *Thorax* 1990;45:493-5.
 - 45 George PJM, Pearson MC, Edwards D, Rudd RM, Hetzel MR. Bronchography in the assessment of patients with lung collapse for endoscopic laser therapy. *Thorax* 1990;45:503-8.
 - 46 Haussinger K, Held E, Huber R. Endobronchial laser therapy differential therapeutic use and clinical value. *Klin Wochenschr* 1984;62:74-80.
 - 47 Chetty KG, Moran EM, Sassoon CSH, Viravathan AT, Light RW. Effect of radiation therapy on bronchial obstruction due to bronchogenic carcinoma. *Chest* 1989;95:582-4.
 - 48 Slawson RG, Scott RM. Radiation therapy in bronchogenic carcinoma. *Thorax* 1979;32:175-6.
 - 49 Majid DA, Lee S, Khushalani S, Seydel H. The response of atelectasis from lung cancer to radiation therapy. *Int J Radiat Oncol Biol Physiol* 1986;12:231.
 - 50 George PJM, Fenelon L, Ridgeway G, Hetzel MR. Infections in the lung associated with laser bronchoscopy [abstract]. In: *Proceedings of the fifth annual congress of British Medical Laser Association*. Edinburgh: 1987.
 - 51 George PJM, Clarke CG, Tolfree S, Garrett CPO, Hetzel MR. Changes in regional ventilation and perfusion of the lung after endoscopic laser treatment. *Thorax* 1990;45:248-54.
 - 52 Weishaupt K, Gomer CJ, Dougherty TJ. Identification of singlet oxygen as the cytotoxic agent in photo-radiation of a murine tumour. *Cancer Res* 1976;36:2326-9.
 - 53 Cortese DA, Kinsey JM. Endoscopic management of lung cancer with Haematoporphyrin derivative. *Mayo Clin Proc* 1982;57:543-7.
 - 54 Hayata Y, Kato H, Konaka C, Ono J, Takizawa N. Haematoporphyrin derivative and laser photoradiation in the treatment of lung cancer. *Chest* 1982;81:269-77.
 - 55 Vincent RG, Dougherty TJ, Rao U, Boyle DG, Potter WR. Photoradiation therapy in advanced carcinoma of the trachea and bronchi. *Chest* 1984;85:29-33.
 - 56 Hayata Y, Kato H, Konaka C, et al. Photoradiation therapy with Haematoporphyrin derivative in early and stage I lung cancer. *Chest* 1984;86:169-77.
 - 57 Konaka C, Kato H, Hayata Y. Lung cancer treated by photodynamic therapy alone—survival for more than three years. *Lasers in Medical Science* 1987;2:17-9.
 - 58 Nori D, Hilaris B, Martini N. Intraluminal irradiation in bronchogenic carcinoma. *Surg Clin N Am* 1987;67:1093-102.
 - 59 Sinclair WK. Artificial radioactive sources for interstitial therapy. *Br J Radiol* 1952;25:417-9.
 - 60 Henshke UK. Interstitial implantation in the treatment of primary bronchogenic carcinoma. *AJR* 1958;79:981-7.
 - 61 Law MR, Henk JH, Goldstraw P, Hodson ME. Bronchoscopic implantation of radioactive gold grains into endobronchial carcinomas. *Br J Dis Chest* 1985;29:147-52.
 - 62 Macha HN, Coch K, Stadler M, Schumacher W, Krumhaar ED. New technique for testing occlusive and stenosing tumours of the trachea and main bronchi: endobronchial irradiation by high dose iridium 192 combined with laser utilisation. *Thorax* 1987;42:511-5.
 - 63 Mehta M, Shahabi S, Jarjour N, Steinmetz M, Kubsad S. Effect of endobronchial radiation therapy on malignant bronchial obstruction. *Chest* 1990;97:662-5.
 - 64 Burt PA, O'Driscoll BR, Notley HM, Barker PV, Stout R. Intraluminal irradiation for the palliation of lung cancer with the high dose rate micro-Selectron. *Thorax* 1990;45:765-8.
 - 65 George PJM, Mantell BS, Rudd RM. Low dose rate endobronchial therapy using caesium 137 [abstract]. *Thorax* 1990;45:310P.
 - 66 Boedker A, Kald A, Kristensen D. A method for selective endobronchial and endotracheal irradiation. *Thorac Cardiovasc Surg* 1982;84:59-61.
 - 67 Schray MF, McDougall JC, Martinez A, Edmundson G, Cortese D. Management of malignant airway obstruction: clinical and dosimetric considerations using an iridium 192 after loading-technique in conjunction with the neodymium YAG laser. *Int J Radiat Oncol Biol Physiol* 1984;11:403-9.
 - 68 Allen MD, Baldwin C, Fish J, Goffinet S, Cannon B, Mark BD. Combined laser therapy and endobronchial radiotherapy for resectable lung carcinoma with bronchial obstruction. *Am J Surg* 1985;150:71-7.
 - 69 Jain PR, Dedhia HV, Lapp NL, Thompson AB, Frich JC. Nd YAG laser followed by radiation for treatment of malignant airway lesions. *Lasers in Surgery and Medicine* 1985;5:47-53.
 - 70 Montgomery WW. T-tube tracheal stent. *Arch Otolaryngol* 1965;82:320-1.
 - 71 Clarke DB. Palliative intubation of trachea and main bronchi. *J Thorac Cardiovasc Surg* 1980;80:736-41.
 - 72 Cooper JD, Pearson GA, Todd TRJ, Ginsberg RJ, Goldberg M, Walters P. Use of silicone stents in the management of airway problems. *Ann Thorac Surg* 1989;47:371-8.
 - 73 Insall RL, Morrill GN. Use of a fenestrated silicone drain to stent a malignant tracheo-bronchial stenosis. *Thorax* 1990;45:711-3.
 - 74 Westaby S, Jackson K. A bifurcated silicone rubber stent for relief of tracheo-bronchial obstruction. *J Thorac Cardiovasc Surg* 1982;83:414-7.
 - 75 Wallace MJ, Charnsangavej C, Ogawa K, et al. Tracheo-bronchial tree: expandable metallic stents, use in experimental and clinical applications. *Radiology* 1986;158:309-12.
 - 76 Simmons AK, Irving JD, Clarke SW, Dick R. Use of expandable metal stents in the treatment of bronchial obstruction. *Thorax* 1989;44:680-1.
 - 77 George PJM, Irving JD, Mantell BS, Rudd RM. Covered expandable metal stent for recurrent tracheal obstruction. *Lancet* 1990;335:582-4.