

# Deep-seated intramuscular lipoma penetrates the intercostal muscle

Jinwook Hwang, Won-Min Jo, Byoung-Ju Min, Jae Seung Shin

Department of Thoracic and Cardiovascular Surgery, Korea University Ansan Hospital, Korea University College of Medicine, Ansan, Korea

Correspondence to: Won-Min Jo, MD, PhD. Department of Thoracic and Cardiovascular Surgery, Korea University Ansan Hospital, Korea University College of Medicine, 123, Jeokgeum-ro, Danwon-gu, Ansan-si, Gyeonggi-do 425-707, Korea. Email: jowonmin@gmail.com.

**Abstract:** Deep-seated intramuscular lipomas are rare, and most exhibit an infiltrating behavior. This study reports serial radiographs of a lipoma in chest wall muscles which penetrated the intercostal muscle for a 6-year period. Although this lipoma did not involve the parietal pleura, it compressed lung. To the authors' knowledge, the present study is the first report to show the growth of a deep-seated chest wall lipoma into the thoracic cavity through serial radiographs. We consider the surgical treatment is needed before deep-seated intramuscular chest wall lipoma compress intrathoracic structures.

**Keywords:** Tumor; chest wall; thoracic surgery

Submitted Jun 10, 2015. Accepted for publication Sep 18, 2015.

doi: 10.3978/j.issn.2072-1439.2015.10.29

View this article at: <http://dx.doi.org/10.3978/j.issn.2072-1439.2015.10.29>

## Introduction

A lipoma is a benign tumor that generally originates from fat cells in all types of tissue (1,2). Lipomas can be classified into two types according to their location, namely superficial and deep-seated chest wall lipomas (1). Deep-seated intramuscular chest wall lipomas are rarer than superficial lipomas (2), and they can show histologically infiltrative behaviors and have the potential for malignancy, such as liposarcoma (1-3).

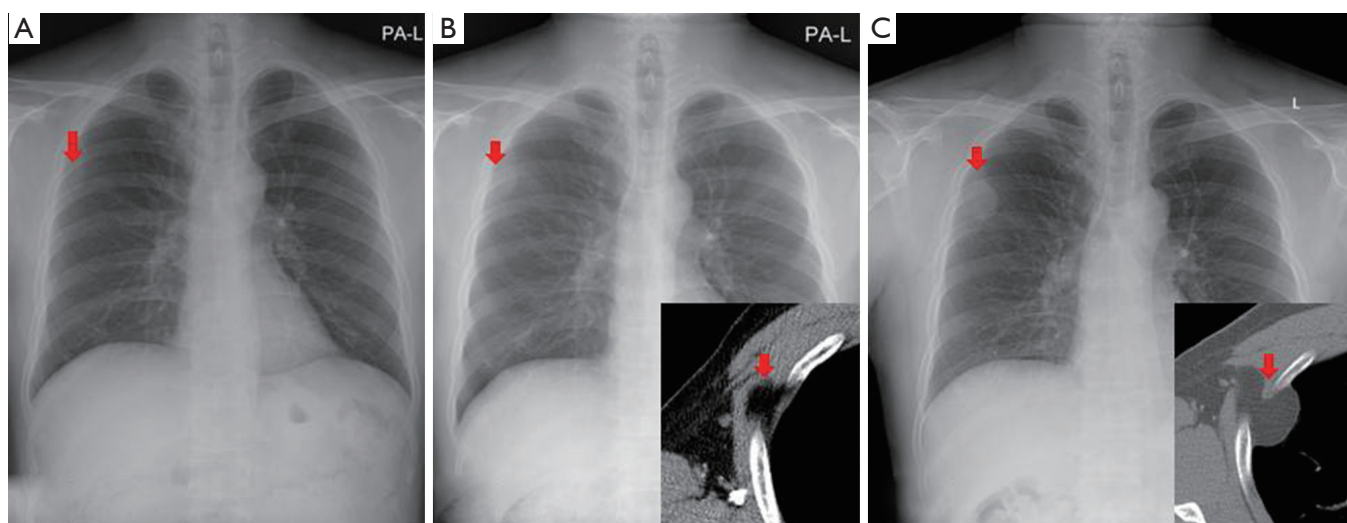
There is no established strategy for the management of asymptomatic lipomas. Also they have no clinical expression, and therefore tend to be neglected unless the mass becomes large enough to cause pain (4-6).

This study reports serial radiographs for a 6-year period for an intramuscular lipoma in the anterior serratus muscle and the surgical excision of the lipoma, which penetrated the intercostal muscle.

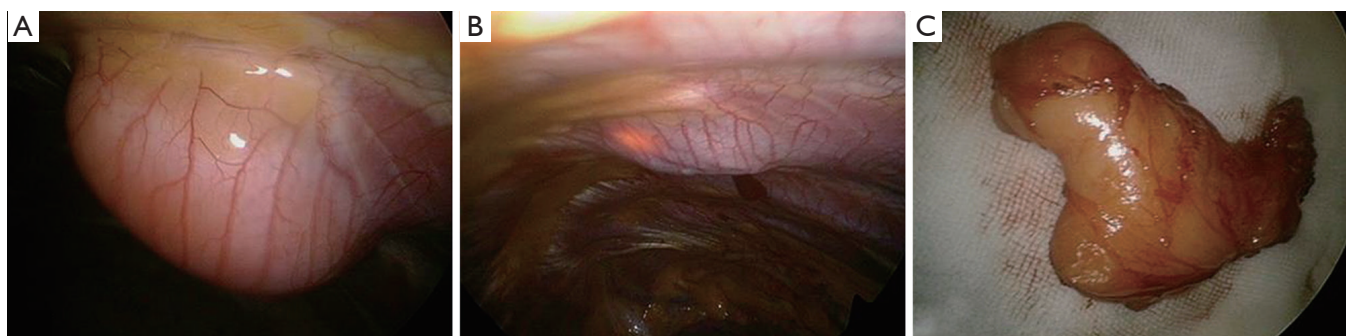
## Case report

A 42-year-old male patient was referred with an asymptomatic and progressively enlarging soft-tissue mass-like lesion in his right axilla based on chest radiography and

CT (*Figure 1*). Six years before, the mass was measured as 2.0 cm × 1.2 cm (*Figure 1A*). However, it was not recognized in his initial routine check-up. Then, 2 years later, the lesion grew to 2.7 cm × 1.8 cm and contained a focal homogeneous fat density inside the right third intercostal space based on his chest radiography and CT (*Figure 1B*). He was followed up without excision. In his latest chest radiographs, the size of the mass was 4.4 cm × 2.9 cm. Chest CT showed that the mass penetrated the thoracic cavity through the third intercostal space, compressing the lung (*Figure 1C*). There was no abnormal finding in his vital signs and laboratory data. He presented no symptom. Elective surgical excision was planned. The thoracic cavity was explored through the port in the seventh intercostal space by using thoracoscopy. In thoracoscopic view, there was a bulging round mass in lateral third intercostal space. The mass did not penetrate the parietal pleura (*Figure 2A*). The mass was returned to the chest wall (*Figure 2B*), and removed through the incision of the axillary skin crease. The tumor was dissected sharply from the chest wall muscle and separated easily from the parietal pleura (*Figure 2B*). In the pathology reports, the tumor was 5.0 cm × 3.0 cm × 1.1 cm, reflecting a well-capsulated lipoma (*Figure 2C*).



**Figure 1** (A) In the initial chest radiograph, a mass was detected in the right upper lung field (arrow); (B) 2 years after A, chest radiographs and CT scans showed a deep-seated intramuscular lipoma originating from the anterior serratus muscle (arrows); (C) 4 years after B, chest wall lipoma penetrated the third intercostal muscle and compressed the lung (arrows).



**Figure 2** (A) The thoroscopic finding showed that the lipoma did not penetrate the parietal pleura; (B) the lipoma was returned and removed with sharp dissection without injury to the parietal pleura; (C) the macroscopic aspect of the lipoma.

The patient was discharged four days after surgery, and there was no recurrence 2 years after surgery.

### Discussion

Deep-seated intramuscular chest wall lipomas are rare but occasionally have various infiltrating features, whereas subcutaneous lipomas generally have a benign clinical course (1,2). In the case of infiltrating lipomas, it is difficult for them to be dissected sharply and removed completely (3).

Deep-seated intramuscular lipomas may have the potential for malignancy, and it is difficult to distinguish a well-differentiated liposarcoma from an in variously

differentiated lipoma through chest radiographs (2). The present case was a well-circumscribed intramuscular lipoma showing transmural penetration through the intercostal muscle based on serial radiographs.

For even asymptomatic and benign-looking lipomas, early surgical treatment is better than radiographic observation. Giant lipomas have been reported to deform or penetrate the chest wall (4-7). Most were neglected by patients themselves (4,5). In the present case, however, an asymptomatic and benign-looking lipoma in the chest wall was routinely followed up by physicians without excision for 6 years. The serial radiologic follow-up revealed a deep-seated intramuscular chest wall lipoma growing into the

intrathoracic space, reflecting the intrathoracic transposition of abdominal organs in the case of a diaphragmatic hernia like. This case implies that neglecting the aggressive behavior of even an asymptomatic and benign lipoma may increase the risk of a herniated chest wall lipoma compressing intrathoracic organs.

Basically, an intramuscular lipoma in the extrathoracic muscle layer, together with its intramuscular fatty tissue, must be removed. The thoracic cavity was explored by thoracoscopy because most of the mass was located in the intrathoracic space and its potential penetration of the parietal pleura could not be ruled out. Previous studies have reported the successful thoracoscopic resection of intrathoracic lipomas as a minimally invasive procedure (8). If a tumor originates deeply inside the extrathoracic muscle layer, then this procedure may be inappropriate.

### Conclusions

To the authors' knowledge, this case report is the first to show the growth of a deep-seated chest wall lipoma into the thoracic cavity through serial radiographs. The results suggest that it is better to treat chest wall lipomas early when they have growing or migrating features. Any surgical excision and histologic confirmation should be done before the tumor penetrates the thoracic cavity.

### Acknowledgements

The authors thank Dr. Ji Young Choo for comments.

**Cite this article as:** Hwang J, Jo WM, Min BJ, Shin JS. Deep-seated intramuscular lipoma penetrates the intercostal muscle. *J Thorac Dis* 2015;7(10):E493-E495. doi: 10.3978/j.issn.2072-1439.2015.10.29

### Footnote

*Conflicts of Interest:* The authors have no conflicts of interest to declare.

### References

1. McTighe S, Chernev I. Intramuscular lipoma: a review of the literature. *Orthop Rev (Pavia)* 2014;6:5618.
2. Bancroft LW, Kransdorf MJ, Peterson JJ, et al. Benign fatty tumors: classification, clinical course, imaging appearance, and treatment. *Skeletal Radiol* 2006;35:719-33.
3. Sakurai H, Kaji M, Yamazaki K, et al. Intrathoracic lipomas: their clinicopathological behaviors are not as straightforward as expected. *Ann Thorac Surg* 2008;86:261-5.
4. Leuzzi G, Cesario A, Parisi AM, et al. Chest wall giant lipoma with a thirty-year history. *Interact Cardiovasc Thorac Surg* 2012;15:323-4.
5. Pop D, Venissac N, Mouroux J. Remodelling acquired chest wall deformity after removal of a large axillary lipoma. *Interact Cardiovasc Thorac Surg* 2010;10:105-6.
6. Ozpolat B, Ozeren M, Akkaya T, et al. Giant lipoma of chest wall. *Eur J Cardiothorac Surg* 2004;26:437.
7. Carr CS, Rawlins R, O'Keefe PA. Intramuscular lipoma of the intercostal muscle--the source of hour-glass transmural thoracic lipomas? *Eur J Cardiothorac Surg* 2001;19:361.
8. Takamori S, Miwa K, Hayashi A, et al. Intramuscular lipoma in the chest wall. *Eur J Cardiothorac Surg* 2004;26:1038.