

CASE REPORT

Open Access



Dissecting ventricular pseudoaneurysm after perimyocarditis—a case report

Rickard P.F. Lindblom*, Ulrica Alström and Vitas Zemgulis

Abstract

Background: The current case describes the fast development of a pseudoaneurysm in a patient that presented with signs of systemic inflammation and generally deranged blood work.

Case Presentation: The pseudoaneurysm appeared within one week of disease onset. The anatomic extent of the pseudoaneurysm was unusual, as it dissected intramurally beneath the septum, inferior to the right ventricle and had effect on the RV filling. The etiology could not be definitely defined, since in adults the most common cause for pseudoaneurysm development is recent myocardial infarction, but in this patient the coronary arteries were healthy. Instead it could have been a consequence of an aggressive perimyocarditis.

Conclusions: Due to the unpredictable nature of pseudoaneurysms we advocate early contact with a center with cardiothoracic surgery expertise for rapid surgical intervention.

Keywords: Perimyocarditis, Pseudoaneurysm, Echocardiogram

Background

Pseudoaneurysms differ from aneurysms in that they lack the components of the ordinary myocardial wall and are only contained by fibrous membrane [1], thus the significant risk of rupture, up to 45 % [2]. Transmural myocardial infarction is the most common etiology behind development of pseudoaneurysms, but they can also occur after trauma, infection and surgery [3–5].

Case presentation

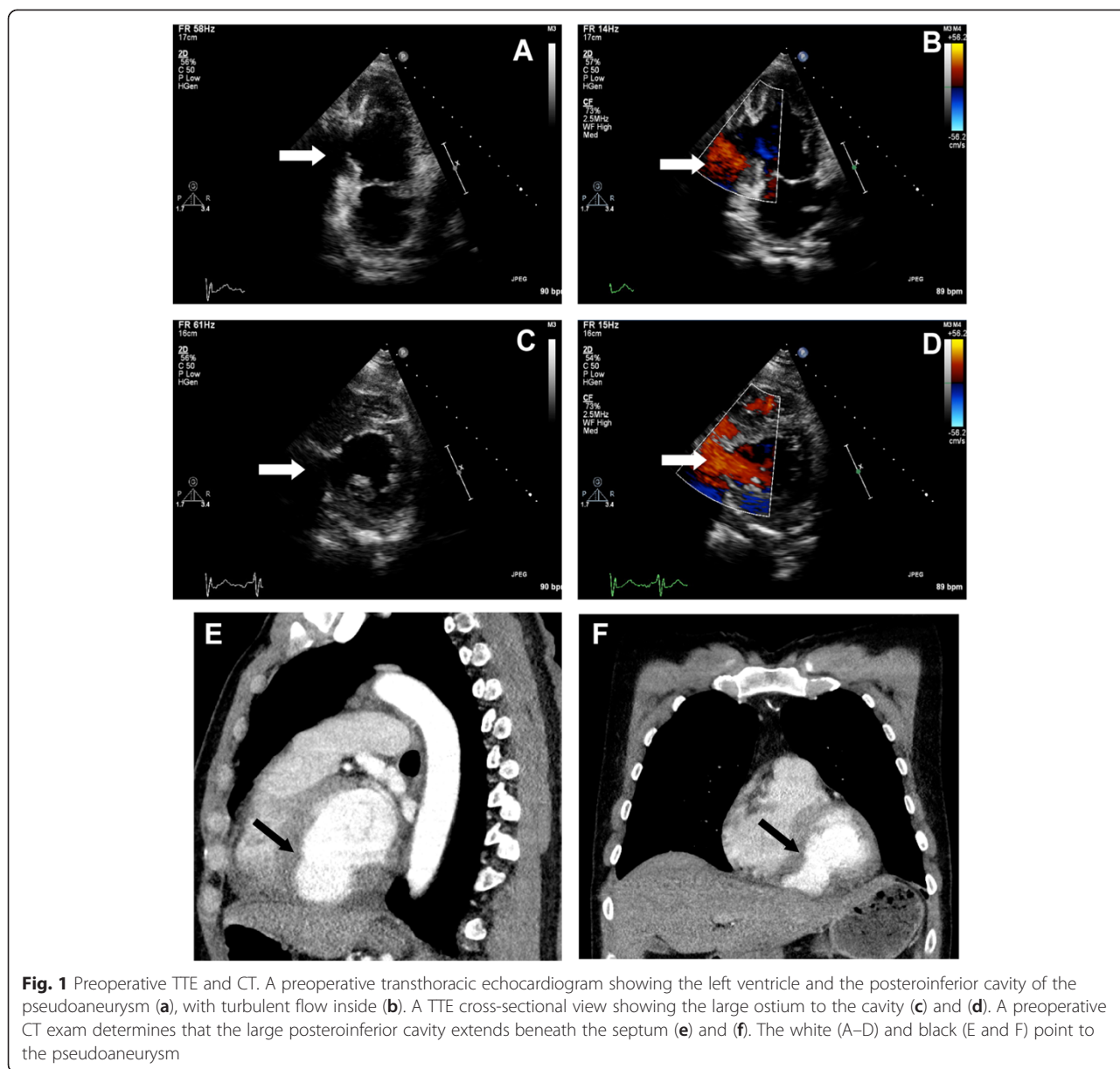
A 48 year old man presented in a rural hospital with nausea, vomiting, diarrhea, fever and high sitting abdominal pains radiating towards the left shoulder. He had a previous medical history of unspecified collagenosis and had since the age of 12 been hospitalized on eight occasions with diffuse rheumatic symptoms that had been treated with cures of steroids and antibiotics. He was in good physical shape without any symptoms of heart disease, without any medications, led an active life and had recently performed an ergometry test that was normal.

Upon presentation there were general ST-elevations on the ECG, suggestive of perimyocarditis. He had elevated

levels of white blood cell count (24.1, ref 3.5–8.8), C-reactive protein (152, ref <5), creatinine (165, ref 60–105), hepatic transaminases (ASAT/ALAT, 3.1/3.36, ref <0.75/<1.1) and troponin I (15, ref <0.07). Blood pressure was 100/70 and there was jugular vein distension. A CT scan was performed; this revealed a significant amount of pericardial fluid, right sided pleural effusion, enlarged mediastinal lymph nodes, oedema around the pancreas and fluid around the liver. A transthoracic echocardiogram confirmed the presence of pericardial effusion with significant hemodynamic compromise, but no other significant findings.

This warranted urgent transfer to a county hospital where antibiotics (Cefotaxime) were started. In the next days a new echocardiogram was performed which identified a 2.7 × 3.3 cm large pseudoaneurysm in the posteroinferior wall of the LV (Fig. 1a–d). The ostium of the pseudoaneurysm was localized close to the posterior leaflet of the mitral valve, but the valve was patent. Moreover, the pericardial effusion had diminished. A new CT-scan was performed which demonstrated a rupture in the ventricular wall with an ostium of 2–3 cm (Fig. 1e–f). The cavity dissected in the muscular mass beneath the septum and affected the filling of the RV. A coronary angiogram was performed, which surprisingly showed no coronary pathology, after which the patient was moved to the department of cardiothoracic

* Correspondence: rickard.lindblom@akademiska.se
Department of Cardiothoracic Surgery and Anesthesia, Uppsala University Hospital, 751 85 Uppsala, Sweden



surgery. The operation took place 13 days after initial hospitalization.

The patient was cannulated in the femoral vessels and sternotomy performed on full bypass. The pericardium was opened and a substantial volume of dark red fluid with fibrin clots was released under pressure. The posterodiaphragmatic wall of the LV consisted of a hematoma with a large amount of blood clots. The hematoma, i.e. the epicardium that contained the pseudoaneurysm was opened; the aneurysmal sac disrupted the distal part of the septum and dissected intramyocardially into the RV and out to the epicardium (Fig. 2a–e). A 5 × 5.5 cm cardiovascular patch was anchored to the septum with Teflon pledgets, with the sutures passing through the dissection

space beneath the RV and out to the epicardium on either side of the pseudoaneurysm edges through a second Teflon strand forming a three-layer sandwich construction. The edges of the pseudoaneurysm were adapted using a second patch and a running suture over the first patch. There was also a thinning of the RV where the aneurysmal sac had dissected. This was stabilized using new Teflon strands and interrupted sutures. Obliteration of the cavity was confirmed by TEE (Fig. 2f). Weaning from cardiopulmonary bypass was done with inotropic support and was complemented with a percutaneously placed IABP which reduced the needs of amines. The IABP was removed on the third postoperative day. Eight days postoperatively the patient was discharged to the

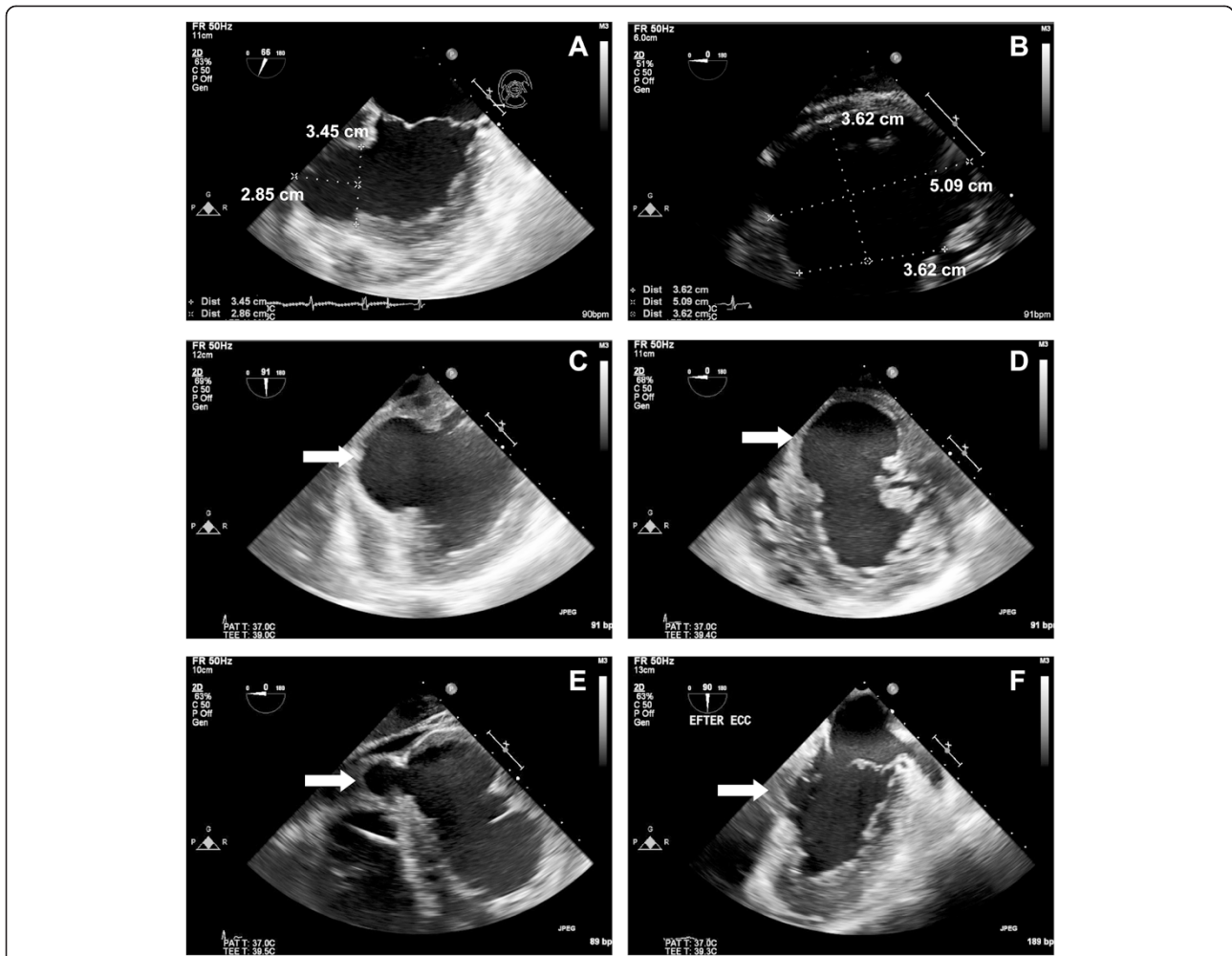


Fig. 2 Peri- and postoperative TEE. Perioperative transesophageal echocardiogram demonstrates that the cavity is almost as large as that of the LV, and probably has increased in size from the previous TTE (a–d), white arrow points to the pseudoaneurysm. The cavity dissects beneath the septum and under the right ventricle (e), white arrow points to the part beneath the RV. TEE at the end of surgery shows that the cavity is largely obliterated (f), the white arrow points to where the ostium was

home clinic in good condition (Fig. 3). Postoperative TTE revealed a moderately depressed LV function, hypo/akinesia of the septum and the inferior wall by the patch, and a mild TR but no MR. The perioperative biopsy of the tissue in the pseudoaneurysm revealed the presence of fibrin and low numbers of eosinophils, suggestive of infarcted myocardium. No amyloid or excessive inflammation was seen. The patient was negative

for CMV, EBV and legionella antigen and no bacteria were identified in the cultures. At follow up 6 months after surgery the patient was in good clinical condition.

Conclusions

The explanation behind the development of the current pseudoaneurysm remains a puzzle as there was no coronary pathology and no site specific infection. We

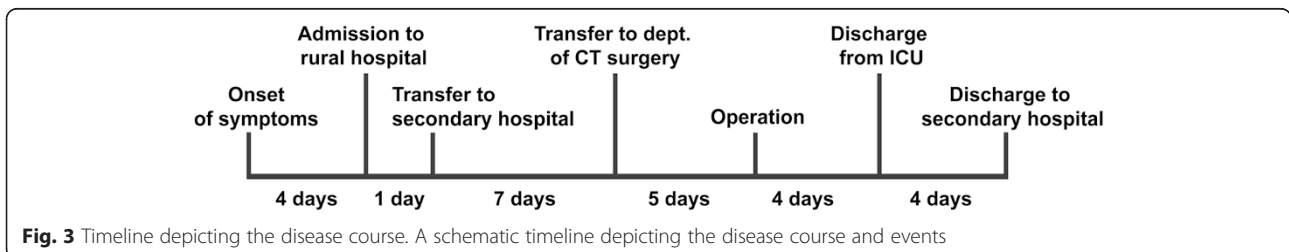


Fig. 3 Timeline depicting the disease course. A schematic timeline depicting the disease course and events

believe it was a consequence of the perimyocarditis, which in general is a benign condition [6], where the current case is clearly an exception. Cases of peri-/myocarditis that have led to ventricular pseudoaneurysm development have been described in children [7, 8] and in conjunction with tuberculosis [9]. Another described etiology behind pseudoaneurysm development is severe endocarditis, with abscess formation [10]. However in the above mentioned cases there has been verified bacterial infections, most often *S.aureus*. In the current case there was a general systemic inflammation, not a site specific cardiac infection. Furthermore no cultures from the patient grew bacteria and 16sRNA analysis showed no presence of bacterial RNA. An exceedingly scarce [11] cause behind pseudoaneurysm formation is infiltrating tumors, but this was ruled out as the PAD showed no signs of malignancy. Another interesting aspect of the current case is that the pseudoaneurysm dissected intramyocardially beneath the septum instead of rupturing. This undoubtedly saved the patient's life, but illustrates how unpredictable pseudoaneurysms are. In the light of this, we advocate early contact with a cardiothoracic surgery center for surgery with short delay.

Consent

Written informed consent was given by the patient.

Abbreviations

IABP: Intra-aortic balloon pump; LV: Left ventricle; MR: Mitral regurgitation; RV: Right ventricle; TEE: Trans-esophageal echocardiogram; TTE: Trans-thoracic echocardiogram; TR: Tricuspid regurgitation.

Competing interests

None.

Authors' contributions

RL wrote the manuscript. UA and VZ read, approved and revised the manuscript. All authors read and approved the final manuscript.

Authors' information

RL admitted the patient. UA was anesthesiologist during the operation and recorded the TEE. VZ operated the patient and was responsible for the postoperative care.

Acknowledgements

We thank Håkan Pettersson at the imaging service at the radiology department for help with formatting the images.

Received: 19 June 2015 Accepted: 28 October 2015

Published online: 06 November 2015

References

1. Yeo TC, Malouf JF, Reeder GS, Oh JK. Clinical characteristics and outcome in postinfarction pseudoaneurysm. *Am J Cardiol.* 1999;84(592–595):A598.
2. Bryniarski L, Kubinyi A, Ekiert-Kubinyi M, Kawecka-Jaszcz K. Postinfarction left ventricular pseudoaneurysm with left-to-right shunt: case report and review of the literature. *Int J Cardiol.* 2010;139:199–201.
3. Frances C, Romero A, Grady D. Left ventricular pseudoaneurysm. *J Am Coll Cardiol.* 1998;32:557–61.
4. Maselli D, Micalizzi E, Pizio R, Audo A, De Gasperis C. Posttraumatic left ventricular pseudoaneurysm due to intramyocardial dissecting hematoma. *Ann Thorac Surg.* 1997;64:830–1.

5. Mohan JC, Mishra B, Nair M, Arora R. Post-traumatic multilobated pseudoaneurysm of the left ventricle secondary to dissecting intramyocardial haematoma of the posterior wall: obstructive and fenestrated communication demonstrated by colour Doppler imaging. *Indian Heart J.* 1998;50:539–41.
6. Ligabue G, Imazio M, Brucato A, Barbieri A, Ferroni F, Maestroni S, et al. Good prognosis for pericarditis with and without myocardial involvement: results from a multicenter, prospective cohort study. *Circulation.* 2013;128:42–9.
7. Desai M, Gandhi H, Mishra A. Post-infective pericarditis left ventricular pseudoaneurysm: a case report and review of literature. *Cardiol Young.* 2015;25:358–61.
8. Airan B, Nair VV, Malankar D, Kothari SS, Das S, Gulati GS, et al. Unusual left ventricular pseudoaneurysm in a child after disseminated bacterial infection. *World J Pediatr congenit heart surg.* 2014;5:121–3.
9. Wei W, Hui C, Sheng-Yu W, Xin D. Uncommon cause of left ventricular pseudoaneurysm: case report and review of literature. *Thorac Cardiovasc Surg.* 2014;62:375–7.
10. Silbiger JJ, Krasner A, Chikwe J, Marino T, Mathewkutty S, et al. Pseudoaneurysm formation in infective endocarditis. *Echocardiogr.* 2013;30:E319–321.
11. Lee PJ, Spencer KT. Pseudoaneurysm of the left ventricular free wall caused by tumor infiltration. *JASE.* 1999;12:604–6.

Submit your next manuscript to BioMed Central and take full advantage of:

- Convenient online submission
- Thorough peer review
- No space constraints or color figure charges
- Immediate publication on acceptance
- Inclusion in PubMed, CAS, Scopus and Google Scholar
- Research which is freely available for redistribution

Submit your manuscript at
www.biomedcentral.com/submit

