

Miliary pulmonary cryptococcosis in a patient with the acquired immunodeficiency syndrome

J D Douketis, S Kesten

Abstract

A 33 year old man with AIDS presented with fever, dyspnoea, cough and a miliary pattern on the chest radiograph. *Cryptococcus neoformans* infection was diagnosed from bronchoalveolar lavage bronchoscopy. This case supports the principle that, in patients with AIDS, pulmonary infections can exhibit variable radiographic features and that definitive diagnosis should always be considered.

(Thorax 1993;48:402-403)

The initial management of patients with the acquired immunodeficiency syndrome (AIDS) with undiagnosed pulmonary infiltrates often requires empirical antimicrobial treatment. As our experience with pneumonia in AIDS patients broadens, however, it has become apparent that many pathogens can exhibit a highly variable clinical and radiographical picture, thereby limiting the accuracy of diagnosis before testing. In patients with AIDS a miliary pattern on the chest radiograph has been associated with *Mycobacterium tuberculosis* and *Pneumocystis carinii* infections and with histoplasmosis.¹⁻³ We present a case of miliary pulmonary cryptococcosis which is to our knowledge the first to be reported in a patient with AIDS.

Case report

A 33 year old homosexual man presented to hospital after a four week history of intermittent fever, chills, progressive dyspnoea, and a non-productive cough. A diagnosis of human immunodeficiency virus (HIV) infection had been made in 1985 as part of a routine screen. Since then the patient's history had included AIDS related peripheral neuropathy, recurrent perianal herpes simplex virus infection, and *Pneumocystis carinii* pneumonia. His CD4 count two months before this admission was $40 \times 10^9/l$. On admission his medications included pentamidine 60 mg by aerosol twice weekly, acyclovir 200 mg five times daily, and ketoconazole 400 mg daily. Zidovudine (AZT) prophylaxis had been dis-

continued one week earlier because of leucopenia.

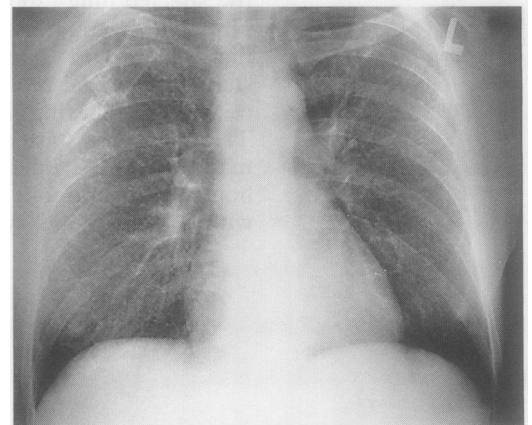
On physical examination the patient appeared acutely ill, thin, pale, and dyspnoeic. His blood pressure was 100/70 mm Hg, pulse 110/min, respiratory rate 24/min, and the temperature was 38.3°C. Head and neck examination showed oral candidiasis and bilateral non-tender lymph nodes, 1-2 cm in diameter, in the anterior cervical chain. Auscultation of the chest revealed bilateral mid inspiratory crackles at the lung bases. The cardiovascular examination showed nothing remarkable. The liver span was 16 cm in the mid clavicular line and there was a palpable spleen tip.

Laboratory investigations showed pancytopenia (haemoglobin, 8.3 g/dl; white blood cells, $1.4 \times 10^9/l$ (86% neutrophils, 7% lymphocytes); platelets, $125 \times 10^9/l$) and raised hepatic enzyme concentrations (serum aspartate aminotransferase, 191 U/l; serum alanine aminotransferase, 121 U/l). Arterial blood gas pressures on room air were: pH 7.50, PaCO₂ 30 mm Hg (4 kPa), PaO₂ 61 mm Hg (8.1 kPa), HCO₃ 24 mmol/l. Chest radiography revealed a miliary pattern (fig); a chest radiograph taken seven months earlier had been normal. Abdominal ultrasonography showed hepatosplenomegaly and para-aortic lymphadenopathy. Initial treatment consisted of intravenous sulphamethoxazole-trimethoprim for presumed pneumocystis pneumonia. Two days after hospitalisation antituberculous medications were added for presumed miliary tuberculosis. Bronchoscopy was undertaken to establish a definitive diagnosis. Bronchoalveolar lavage stains and culture were positive for *Cryptococcus neoformans*. No acid fast bacilli, bacteria, or pneumocystis organisms were identified. The aforementioned medications were discontinued and the patient was prescribed intravenous amphotericin B, 40 mg daily. Further laboratory results included positive blood cultures for cryptococcus, and a cerebrospinal fluid (CSF) India ink stain positive for cryptococcus with a CSF antigen titre of 1/1024. Cultures of the CSF, urine, and sputum were negative.

Toronto Hospital, 399
Bathurst Street,
4-009 ECW, Toronto,
Ontario M5T 2S8,
Canada
J D Douketis
S Kesten

Reprint requests to:
Dr S Kesten

Received 30 January 1992
Returned to authors
13 March 1992
Revised version received
27 April 1992
Accepted 7 May 1992



Radiograph of the chest showing miliary pattern.

In the ensuing weeks the patient's clinical course gradually improved. He was discharged on the 26th hospital day in a stable condition having received a three week course of amphotericin. He continued to receive intravenous amphotericin, 40 mg three times a week, at an outpatient clinic, to a cumulative dose of 1200 mg. Given the high recurrence rate of cryptococcosis in untreated patients, he was also started on maintenance treatment with oral fluconazole 200 mg daily, which, unlike ketoconazole, is known to have good penetration into the CSF. A repeat chest radiograph several months later was normal.

Discussion

Cryptococcus neoformans is the most common cause of fungal pneumonia in patients positive for HIV. Most cases have occurred in HIV patients with a previous history of an AIDS defining illness. As with our case, cryptococcal pneumonia in patients with AIDS is often part of a disseminated illness, usually with coexistent disease of the central nervous system.^{4,5} The development of widespread cryptococcal infection and oral candidiasis was associated with evidence of substantial immunosuppression (neutropenia, low CD4 count) and occurred despite prophylaxis with ketoconazole. In HIV patients without AIDS, cryptococcal pneumonia usually presents with localised disease and infrequent dissemination.⁴ The clinical features are usually non-specific and include fever, cough, weight loss, pleuritic chest pain, and dyspnoea. The radiographic findings of pulmonary cryptococcosis in patients with or without AIDS can have a varied presentation that includes segmental consolidation, well circumscribed single or multiple nodules, interstitial infiltrates, cavitory lesions, and pleural effusions.⁵⁻⁷ A diffuse nodular pattern somewhat resembling miliary tuberculosis, except that the nodules were larger, has been described recently in two AIDS patients with disseminating cryptococcosis whose clinical presentations were similar to that of our case.⁶ Interstitial infiltrates in patients with AIDS and disseminated cryptococcosis have also been associated with other opportunistic lung infections.⁸ Our case of miliary pulmonary cryptococcosis represents the first such reported occurrence in an HIV positive patient. Overall this presentation of cryptococcus is exceedingly rare with only two other cases having been report-

ed in the literature.^{9,10} One of these patients had a known immunocompromising illness (chronic myelogenous leukaemia).

The differential diagnosis of a miliary radiographical pattern in the general population is dominated by tuberculosis. Other less common causes include sarcoidosis, lymphoma, histiocytosis X, and fungal infections (including histoplasmosis, coccidioidomycosis, blastomycosis, and cryptococcus).¹¹ In the HIV population a miliary pattern has been described with tuberculosis, pneumocystis pneumonia, and histoplasmosis.^{2,3} An interstitial pattern simulating miliary disease on the chest radiograph has also been described with pneumocystis pneumonia and Kaposi sarcoma.¹

Our case of miliary pulmonary cryptococcosis illustrates that a pulmonary infection in a patient with AIDS often has a variable and at times unexpected radiographical appearance. A microbiological diagnosis should be sought whenever possible, either by non-invasive means or by bronchoscopy, to indicate appropriate treatment. As with our patient, bronchoscopy has been found to be a safe and sensitive means of diagnosing pulmonary cryptococcosis in patients with AIDS.¹²

- 1 Barnes PF, Bloch AB, Davidson PT, Snider DE Jr. Tuberculosis in patients with human immunodeficiency virus infection. *N Engl J Med* 1991;324:1644-50.
- 2 Wasser LS, Brown E, Talavera W. Miliary PCP in AIDS. *Chest* 1989;96:693-5.
- 3 Johnson PC, Sarosi GA, Septimus ES, Satterwhite TK. Progressive disseminated histoplasmosis in patients with the acquired immune deficiency syndrome: a report of 12 cases and a literature review. *Semin Respir Infect* 1986;1:1-8.
- 4 Eng RHK, Bishburg E, Smith SM, Kapila R. Cryptococcal infections in patients with AIDS. *Am J Med* 1986;81:19-23.
- 5 Wasser L, Talavera W. Pulmonary cryptococcosis in AIDS. *Chest* 1987;92:692-5.
- 6 Miller WT Jr, Edeman JM, Miller WT. Cryptococcal pulmonary infection in patients with AIDS: radiographic appearance. *Radiology* 1990;175:725-8.
- 7 Khoury MB, Godwin JD, Ravin CE, Gallis HA, Halvorsen RA, Putman CE. Thoracic cryptococcosis: immunologic competence and radiologic appearance. *AJR* 1984;141:893-6.
- 8 Chechani V, Kamholz SL. Pulmonary manifestations of disseminated cryptococcosis in patients with AIDS. *Chest* 1990;98:1060-6.
- 9 McCulough NB, Louria DB, Hilbish TF, Thomas LB, Emmons C. Cryptococcosis: clinical staff conference at the National Institutes of Health. *Ann Intern Med* 1958;49:642-61.
- 10 Gordonson J, Birnbaum W, Jacobson G, Sargent EN. Pulmonary cryptococcosis. *Radiology* 1974;112:557-61.
- 11 Lynch DA, Armstrong JD. A pattern oriented approach to chest radiographs in atypical pneumonia syndrome. *Clin Chest Med* 1991;12:203-22.
- 12 Malabonga VM, Basti J, Kamholz SL. Utility of bronchoscopic sampling techniques for cryptococcal disease in AIDS. *Chest* 1991;99:370-72.