

# Thoracoscopy assisted pulmonary lobectomy

W S Walker, F M Carnochan, M Tin

## Abstract

**Background**—This report describes a preliminary experience with six patients undergoing video imaged thoracoscopic pulmonary lobectomy.

**Methods**—Three left upper lobectomies, and one each of right upper, right lower and left lower lobectomy were undertaken. The resections were performed as orthodox dissectional lobectomy procedures but were carried out under videothoracoscopic imaging with instruments introduced through two stab incisions. The entire resected lobe was delivered through a 7 cm submammary intercostal incision.

**Results**—There were no operative deaths or complications attributable to the technique. In three other patients conversion to an open thoracotomy was required because of bleeding (two cases) or obscure anatomy (one case). Post-operative pain in those undergoing thoracoscopic resection was less than that encountered with standard thoracotomy and early clinic review showed the patients to be pain free with excellent shoulder movement.

**Conclusions**—Major pulmonary resection according to standard cancer practices is feasible with videothoracoscopic techniques. This approach is likely to offer considerable functional benefit to patients. Specimen delivery through the submammary incision imposes a 5 cm primary lesion size limitation. Detailed mediastinal assessment is necessary to exclude N2 status before undertaking thoracoscopic surgery.

(Thorax 1993;48:921-924)

Thoracoscopic pulmonary resection has been described using wedge resection<sup>1,2</sup> that can be accomplished with either stapling techniques or by laser.<sup>3</sup> Limited local resection, however, raises the concern of completeness of resection when compared with standard open lobectomy.<sup>4,5</sup> This report confirms the feasibility of using endoscopic instrumentation to perform an orthodox dissectional lobectomy thereby obviating the concern that might otherwise result if a minimally invasive approach were to be restricted to local excision.

## Methods

### SELECTION

Nine patients referred to the thoracic surgical unit between April and July 1992 were

selected for the procedure. Fitness for surgery was based on standard current criteria for resection by open thoracotomy (adequate spirometry, blood gas analysis, and stable cardiac status). Suitability for thoracoscopic resection was determined by the presence of a peripheral pulmonary lesion of apparent size less than 5 cm that was not visible on fibre-optic bronchoscopy. Localised thoracic disease was confirmed by thoracic computed tomography (CT) scans that identified either no mediastinal nodes or nodes less than 5 mm in size. Distant spread was excluded by negative hepatic ultrasound and negative isotopic bone scan (if indicated by routine biochemistry or symptoms). Specific consent for an attempt at thoracoscopic resection was obtained from each patient and the possible need to revert to standard thoracotomy was explained.

### SURGICAL TECHNIQUE

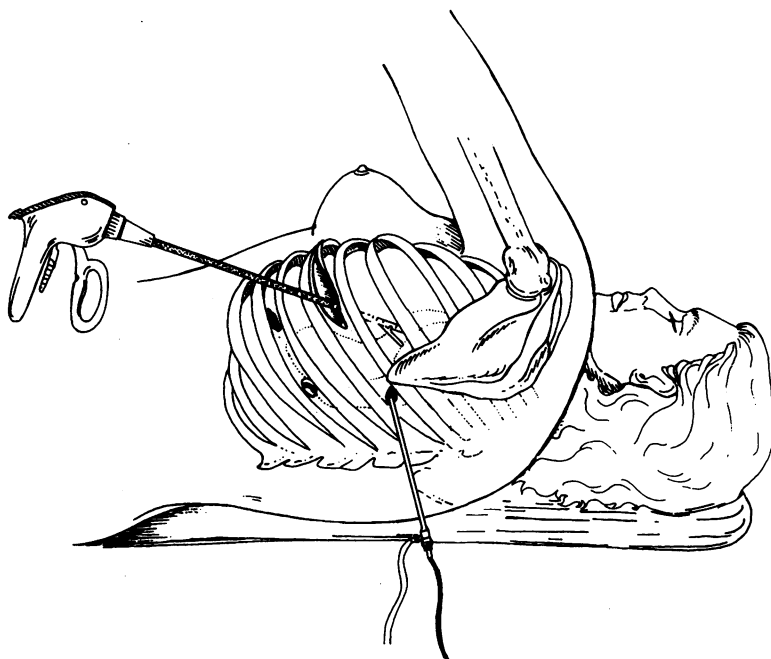
Surgery was undertaken with the patient prepared, anaesthetised, and positioned as for a standard posterolateral thoracotomy. A double lumen endobronchial tube was employed and standard thoracotomy monitoring practised with continuous electrocardiogram, radial arterial pressure, O<sub>2</sub> saturation, and end tidal CO<sub>2</sub> displayed. Surgical access was gained with three stab incisions over the lateral chest wall and a short (5-7 cm) submammary incision (fig) was used to deliver the lobectomy specimen. The first incision was made about 1 cm posterior to and just caudal to the lower pole of the scapula. This was used to obtain the thoracoscopic video image and provided a good general view of the thorax and excellent positioning to view the fissural and hilar dissection. The operative view was provided by a video thoracoscopic system comprising a 10 mm 0° laparoscope (Storz, UK), video camera system (DP 102, DP Medical Systems, Wallington, Surrey), light source (Richard Wolf UK, Mitcham, Surrey, UK), and video monitor (Sony PVM-2BOQM, Sony UK).

Operating instruments were passed through an incision positioned about three interspaces caudal to the thoracoscopic port and through another adjacent incision or one 2-3 cm anterior and cranial to the tip of the scapula. The first two cases were resected entirely using three ports and a short submammary incision was then made for specimen delivery. It became apparent, however, that it was advantageous to create the submammary incision at an early stage as it allowed a swab mounted on sponge holding forceps to be inserted to clear blood and clot. A cannula was used for the thoracoscopic

Department of  
Thoracic Surgery,  
City Hospital,  
Greenbank Drive,  
Edinburgh EH10 5SB  
W S Walker  
F M Carnochan  
M Tin

Correspondence to:  
Mr W S Walker

Received 25 August 1992  
Returned to authors  
30 March 1993  
Revised version received  
14 June 1993  
Accepted 17 June 1993



Operating ports and submammary incision used for a left sided thoracoscopic lobectomy.

port but not for any of the other sites as it restricted the movement of instruments.

#### OPERATIVE TECHNIQUE

Suitability for operation was first assessed by inspection paying particular attention to the size and location of the tumour to determine that it appeared restricted to one lobe and that the hilum was free of disease. A pledget mounted on long forceps was used to provide tactile feedback and was also useful for locating the tumour within the lobe if visceral pleural puckering was not obvious. The lobar arteries were divided before the vein to avoid pulmonary congestion and oozing in the operative field. For left upper lobectomy the sequence comprised arteries, vein, and bronchus. For either lower lobectomy, however, it proved convenient to divide the pulmonary ligament and lower pulmonary vein before the bronchus, and in the case of the right upper lobectomy the bronchus had to be divided before the apicoanterior stem artery could be seen.

Fissural dissection with the lung moderately inflated was carried out with dissecting scissors (Endoshears; Autosuture, UK) until the sheath of the pulmonary artery was exposed. The arterial sheath was then entered by sharp dissection after deflating the lung. Arterial dissection was achieved by opening the sheath and using pledgets to displace it. The relevant lobar branches were stapled (Endo GIA 30 V3; Autosuture). When the fissures were incomplete they were completed with staples (Endo GIA 30 3·5; Autosuture) to minimise postoperative air leakage. Lobar bronchial nodes were swept up into the specimen with a pledget mounted on a long forceps and the bronchial arteries were

cauterised or clipped. Endoscopic staples were used to divide and close the lobar bronchus (Endo GIA 30 3·5) and vein (Endo GIA 30 V3). The port chosen for stapler insertion was that which most easily allowed the instrument to be passed across the structure to be divided and which allowed the operator to see that the jaws of the stapler were completely across the structure thereby avoiding the possibility of partial division.

The lobes were retrieved through the short anterior intercostal incision in the inframammary crease. In five cases it was not necessary to spread the ribs but in one very obese patient with a larger tumour a Touffier retractor was used to separate the ribs slightly as in an anterior mediastinotomy. Apical and basal underwater seal drains were inserted through the instrument ports. The short inframammary incision and the remaining stab incision were repaired in layers with Vicryl (Ethicon).

Linear visual analogue pain scores (0 = no pain, 100 = worst pain imaginable) were determined at regular intervals by the nursing staff while the patient remained in the high dependency unit.

#### Results

Six of the nine patients underwent successful video imaged thoracoscopic resection. Within this learning group of patients, operative experience varied considerably. Blood loss ranged between 50 and 1100 ml (average 400 ml). Operative time varied between three and six hours (average 4·2 hours). Air leakage and drain removal after operation was similar to standard cases. Linear visual analogue pain scores were reduced by comparison with unit average figures. The mean first day visual analogue pain score was 25·8 compared with 34·3 for contemporary open thoracotomy and no intercostal nerve blocks were required after operation. A feature of note was that reduced wound pain made other sources of discomfort such as arthritis contribute to reported pain.

The table gives details of the postoperative courses and pathological data of the six resected cases. No attempt was made to discharge those patients with an uneventful postoperative course earlier than usual at this preliminary stage in our experience. Four patients made entirely satisfactory recoveries from their surgery. One with gross abdominal obesity developed sputum retention and required suction bronchoscopy. This patient's stay was prolonged until his lung expanded to a satisfactory degree although he remained clinically well. Another case who was an alcoholic developed a severe postoperative confusional state. This resulted in a prolonged stay in the thoracic unit because of an absence of suitable accommodation elsewhere. None of the patients had abnormal postoperative blood loss and there were no bronchopleural fistulae.

At outpatient review four weeks after operation mobility seemed enhanced over

## Clinical features of six male patients undergoing video imaged thoracoscopic lobectomy

Age (years)	Preoperative conditions	Procedure	Postoperative course	Pathology	Discharge (days after operation)
64	Chronic abdominal pain	Left upper lobectomy	Uneventful	Atypical carcinoid T1 N0	9
74	Severe rheumatoid arthritis	Left upper lobectomy	Uneventful	Adeno-carcinoma T1 N0	7
73	Prostatic carcinoma	Left upper lobectomy	Uneventful	Small cell carcinoma T2 N0	8
65	Prostatism	Right lower lobectomy	Uneventful Atrial fibrillation	Metachronous tumours Adeno T2 N0 Squamous T1 N0	7
63	Morbid obesity diabetes Tracheal cancer irradiated 2 years previously	Left lower lobectomy	Sputum retention: suction bronchoscopy × 2	Mixed differentiation (adeno, squamous, and small cell) T2 N0	18
73	Alcoholism Recent pulmonary embolus	Right upper lobectomy	Severe confusional state	Mixed differentiation (adeno and squamous) T1 N0	26

standard thoracotomy cases and wound pain was appreciably reduced; shoulder movement was excellent.

Three other cases underwent attempted resection and were converted to standard thoracotomies. Two were intended right upper lobectomies. In one of these abnormal vascular anatomy led to the attempt being abandoned to forestall possible damage to a major vessel. In the other, bleeding occurred from a damaged branch of a middle lobe artery and the attempt was also abandoned. The third case underwent thoracoscopic middle and lower lobectomy that was completed except for the middle lobe vein. During attempts to display this a previously unseen small middle lobe artery was damaged and the operation was therefore completed as an open procedure. None of these cases suffered any ill effects from the change to an open approach. In retrospect both of those converted to an open procedure because of bleeding were readily salvagable and could have been completed as thoracoscopic cases, but at that stage in the clinical experience it was considered wise to proceed to an open procedure.

### Discussion

Thoracoscopy is a powerful diagnostic aid in the management of mesothelioma and recurrent pleural effusion. Thoracoscopic management of pneumothorax, sympathectomy, and lung biopsy are well established procedures.<sup>4,5,7</sup> The advent of videothoracoscopy has facilitated operative techniques including pleurectomy and control of bullae,<sup>8</sup> mobilisation of the thoracic oesophagus,<sup>9</sup> and drainage or excision of mediastinal and bronchial cysts.<sup>10</sup> Resection of pulmonary tumours has until recently been restricted to local wedge resections. Lewis *et al* described two cases undergoing thoracoscopic middle lobectomy and one undergoing left upper lobectomy.<sup>11</sup> Their technique differed in that the bronchus was

secured with a conventional Ethicon Proximate Linear 75 stapler and all the vessels were taken collectively using an Ethicon Proximate RL 60 with both instruments passed through a minithoracotomy. This technique is not comparable with the present series in which a dissection lobectomy was performed so that each hilar structure was identified, cleared of surrounding tissue, and secured individually as would be the case in an open lobectomy.

It seems prudent to limit thoracoscopic lobar resection to small lesions at this stage in the development of the technique. Although it is possible to dissect mediastinal nodes with thoracoscopic techniques and it has been postulated that thoracoscopy could be employed in assessing the mediastinum for nodal spread, access may not be as effective as that provided by mediastinoscopy, which also allows sampling of the contralateral mediastinum. We would therefore now advocate preoperative mediastinal assessment by both thoracic CT scanning and mediastinoscopy.

The patient must be prepared as for a formal thoracotomy and a full thoracotomy instrument set should be available in case of haemorrhage or the need to extend the proposed resection. At present, conventional instruments inserted through the operating ports are often superior to the available laparoscopic types. Several of the cases in this series had to have further staples applied to the bronchus to ensure that it was properly closed, until it became evident that stapler apposition weakens with each use of the device. A new instrument rather than simply a staple cartridge reload should therefore be used when the lobar bronchus is to be tackled. The value of thoracoscopic resection would be lost by a long delivery incision. Therefore the tumour must be small enough to slide through the anterior intercostal incision, indicating a 4–5 cm maximum lesion size.

Although the conversion rate to open thoracotomy was high, this early experience shows that thoracoscopic lobectomy is feasible and can be performed without sacrificing the dissection techniques used at an open procedure. It seems probable that with increasing experience the conversion rate will fall but it should be remembered that conversion simply returns the patient to the technique that would previously have been used anyway. The use of thoracoscopic techniques to achieve formal lobectomy offers potential advantages to the patient. Tumour handling is virtually absent and postoperative pain is reduced. If this translates into reduced chronic wound pain and expedites return to normal activities, the added time and cost inherent in the procedure will have been justified.

- 1 Wakabayashi A. Expanded applications of diagnostic and therapeutic thoracoscopy. *J Thorac Cardiovasc Surg* 1991;102:721–3.
- 2 Donnelly RJ, Page RD, Cowen ME. Endoscopy assisted microthoracotomy: initial experience. *Thorax* 1992;47:490–3.

- 3 Landreneau RJ, Herla DB, Johnson JA, Boley TM, Nawarawong W, Ferson PF. Thoracoscopic neodymium:yttrium aluminium garnet laser assisted pulmonary resection. *Ann Thorac Surg* 1991;52:1176-8.
- 4 Miller JL. Therapeutic thoracoscopy: new horizons for an established procedure. *Ann Thorac Surg* 1991;52:1036-7.
- 5 Goldstraw P. Endoscopy assisted microthoracotomy. *Thorax* 1992;47:489.
- 6 Dijkman JH, van der Meer JWM, Bakker W, Wever AMJ, van der Brock PJ. Transpleural lung biopsy by the thoracoscopic route in patients with diffuse interstitial pulmonary disease. *Chest* 1982;82:76-83.
- 7 Page RD, Jeffrey RR, Donnelly RJ. Thoracoscopy: a review of 121 consecutive surgical procedures. *Ann Thorac Surg* 1989;48:66-8.
- 8 Nathanson LK, Shimi SM, Wood RA, Cuschieri A. Videothoracoscopic ligation of bulla and pleurectomy for spontaneous pneumothorax. *Ann Thorac Surg* 1991;52:316-9.
- 9 Cuschieri A, Shimi S, Banting S. Endoscopic oesophagectomy through a right thoracoscopic approach. *J R Coll Surg Edinb* 1992;37:7-11.
- 10 Lewis RJ, Caccavale RJ, Sisler GE. Imaged thoracoscopic surgery: a new thoracic technique for resection of mediastinal cysts. *Ann Thorac Surg* 1992;53:318-20.
- 11 Lewis RJ, Sisler GE, Caccavale RJ. Imaged thoracic lobectomy: Should it be done? *Ann Thorac Surg* 1992;54:80-3.