

Anaesthetic Management of Anaphylactic Shock Caused by Nonruptured Hydatid Cyst of the Liver

I Davarci¹, K Tuzcu¹, M Karcioglu¹, I Yetim², A Aydogan², S Turhanoglu¹

ABSTRACT

Hepatic hydatid cyst (HC) caused by Echinococcus granulosus is still endemic in many parts of the world, and it is a common health problem, especially in developing countries. The rupture of the HC can cause anaphylactic shock or even death during surgical treatment. We present a case report regarding anaphylactic reaction due to surgery to the liver for HC which has an aberrant venous drainage incidentally detected during surgical operation in a 50-year old female patient. She was successfully treated with adrenaline, antihistamines, steroids, colloid or crystalloid fluids. After the surgery, she was transferred from the intensive care unit to the surgical ward on the first postoperative day. The possibility of anaphylaxis should be kept in mind; despite all the precautionary measures, nonrupture of the hydatid cyst and absence of spillage of the cyst to the circulation or into the surrounding tissues, anaphylaxis can still occur. Therefore, close monitoring for early diagnosis and appropriate management of anaphylaxis are essential to stabilize the patient and produce the best outcome.

Keywords: Anaphylactic shock, hydatid cyst, nonrupture

Manejo Anestésico del Choque Anafiláctico Causado por Quiste Hidatídico Hepático Sin Ruptura

I Davarci¹, K Tuzcu¹, M Karcioglu¹, I Yetim², A Aydogan², S Turhanoglu¹

RESUMEN

El quiste hidatídico hepático (QH) causado por Echinococcus granulosus es todavía endémico en muchas partes del mundo, y constituye un problema de salud común, especialmente en los países en desarrollo. La ruptura del QH puede causar un choque anafiláctico o incluso la muerte durante el tratamiento quirúrgico. Presentamos el reporte de un caso de reacción anafiláctica debido a la cirugía del hígado por un QH que tiene un drenaje venoso aberrante, incidentalmente detectado en el transcurso de una operación quirúrgica a una paciente de 50 años de edad. La paciente fue tratada exitosamente con adrenalina, antihistamínicos, esteroides, y líquidos coloides o cristaloides. Después de la cirugía, fue trasladada de la unidad de cuidados intensivos a la sala de cirugía en el primer día postoperatorio. Debe tenerse en cuenta la posibilidad de anafilaxia. A pesar de todas las medidas cautelares, no ruptura del quiste hidatídico y ausencia de derrame del quiste a la circulación o a los tejidos circundantes, la anafilaxis puede ocurrir. Por lo tanto, una estrecha vigilancia para un diagnóstico precoz y un manejo adecuado de la anafilaxis, son esenciales para estabilizar al paciente y producir el mejor resultado posible.

Palabras claves: Choque anafiláctico, quiste hidatídico, no ruptura

West Indian Med J 2014; 63 (5): 545

From: ¹Department of Anaesthesiology and ²Department of General Surgery, Faculty of Medicine, Mustafa Kemal University, Hatay, Turkey.

Correspondence: I Davarci, Mustafa Kemal University, Faculty of Medicine, Department of Anaesthesiology, Hatay, Turkey. E-mail: isildavarci@gmail.com

INTRODUCTION

Hepatic hydatid cyst (HC) caused by *Echinococcus granulosus* is still endemic in many parts of the world, and it is a common health problem, especially in developing countries. Hydatid cyst is commonly seen primarily in the

liver (1). Some procedures such as marsupialization, evacuation of the cyst elements and filling the cyst with saline after evacuation of the endocyst are currently utilized for treatment of HC in the liver (2, 3). The rupture of the HC can cause anaphylactic shock or even death during surgical treatment (4).

In patients undergoing surgery for excision of hydatid cysts, any sudden findings regarding anaphylactic reaction including tachycardia, hypotension, significant bronchospasm and urticaria should alert caregivers to anaphylaxis (5). Herein, we present a case report regarding anaphylactic reaction due to surgery to the liver for HC which had an aberrant venous drainage incidentally detected during the surgical operation.

CASE REPORT

A 50-year old female patient presented with complaints of epigastric pain for approximately four months. Laboratory parameters including haematological and biochemical profile were normal. On physical examination, there was no abnormal finding regarding the cardiovascular and respiratory systems. Ultrasound evaluation revealed a 76×69 mm HC in segment VI and VII of the liver (Figure). Surgery was

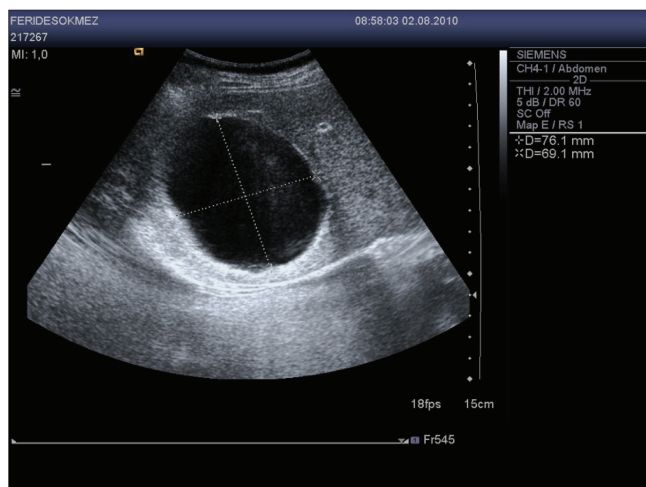


Figure: Ultrasound image of hepatic hydatid cyst (76×69 mm).

decided for the HC.

The patient was premedicated with 2 mg midazolam before induction, and she was monitored by electrocardiogram (ECG), noninvasive blood pressure and peripheral oxygen saturation. Pheniramine maleate (45.5 mg), dexametazon (8 mg) and ranitidine (50 mg) were given for the prophylaxis before induction. Anaesthesia was induced by lidocaine hydrochloride (70 mg), propofol (160 mg), fentanyl (100 μ g) and rocuronium (50 mg). Then the trachea was intubated by using a 7.5-mm cuffed silicon endotracheal tube. The patient was continuously monitored by ECG, noninvasive blood pressure monitor, pulse oximetry and end-tidal capnography. Ventilation was maintained by intermittent positive pressure ventilation at the rate of 12 breaths/

minute, and tidal volume of 550 mL. Anaesthesia was maintained with sevoflurane plus oxygen and nitrous oxide (50:50). Muscle relaxation was provided by using repeated doses of rocuronium.

There was no problem with respect of anaesthesia during the first 30 minutes. After starting the cyst excision, sudden and persistent desaturation (SpO_2 60%), hypotension (50/20 mmHg), hypocarbia ($EtCO_2$ 14 mmHg) and bradycardia (heart rate 30/minute) were noticed. Erythema and flushing, especially in the upper part of the patient's body, were observed. Therefore, the operation was stopped. At this time, sevoflurane and nitrous oxide were discontinued, and the lungs were ventilated with 100% oxygen for hypoxaemia. Then fluid resuscitation was started for hypotension.

Hypoxaemia did not improve despite 100% oxygen ventilation. Hypotension did not respond to fluid replacement. On the auscultation of the lungs, there was bilateral bronchospasm. The diagnosis was an anaphylactic reaction, and a 200 μ g bolus of IV adrenaline was given, followed by an infusion of 5 μ g/kg/minute. After, methyl-prednisolone (100 mg) and pheniramine maleates (45.5 mg) were used. Invasive arterial catheter was inserted and arterial blood gas analysis was done. Severe hypoxaemia was seen [PaO_2 48.3 mmHg, $PaCO_2$ 55 mmHg, pH 7.17, serum bicarbonate 18 mmol/L, BE -8.4 and SpO_2 75%]. The patient responded to fluid and epinephrine infusion within 20 minutes.

The blood pressure, SpO_2 and heart rate returned slowly to normal. Following haemodynamic stabilization, the surgery was continued. The surgery team reported that there was an aberrant venous drainage detected in the HC.

After the surgery, the patient was admitted to the intensive care unit and epinephrine infusion was continued for inotropic support for a day. The patient was admitted to the surgical ward on the first postoperative day.

DISCUSSION

The incidence of anaphylaxis during anaesthesia and the perioperative period is rare and range from 1 in 6000 to 1 in 20 000 anaesthetics (6). The estimated mortality rate is 3%–6% (5). The common anaphylactogenic agents are muscle relaxants, local anaesthetics, antibiotics, latex, chlorhexidine, hypnotics and inhalant agents, protamine, colloids, opioids and antibiotics (6).

Anaphylactic reaction occurs immediately, systemically and can influence various organ systems, and several symptoms have been observed such as respiratory (bronchospasm and upper airway obstruction), cardiovascular (hypotension and arrhythmias), skin (urticaria and angioedema) and gastrointestinal [nausea and vomiting] (6).

A large portion of these symptoms may not be seen under general anaesthesia. During general anaesthesia, hypotension, bronchospasm and urticaria are the main symptoms (7, 8).

In a previous study, the incidence of intra-operative anaphylaxis with hydatid cyst was reported to be low at 0.2–

3.3% (9). During surgical cyst removal or percutaneous drainage of the liver, hydatid cyst IgE-mediated anaphylactic reaction occurs when there is spillage or release of the highly antigenic hydatid fluid into the systemic circulation (5, 10). The allergic reactions vary from mild hypersensitivity reaction to a fatal anaphylactic shock, convulsions and coma (3).

Some reports have recommended that the usage of the prophylactic corticosteroid and antihistamines could avoid anaphylactic reactions (5, 11). In the present study, antihistamines and corticosteroids were admitted for the risk of anaphylaxis after induction. However, during the cyst excision, sudden and persistent desaturation, severe hypotension, hypocarbia, bradycardia and diffuse erythema were observed. These symptoms appeared to be primarily related to anaphylaxis due to the spillage of the highly antigenic HC fluid into the bloodstream by the HC rupture. However, the surgical team reported that the cystic wall was intact but there was a vein in the cyst cavity.

Hydatid cyst has a high intracystic pressure and contains antigenic fluid (12). In a previous study, the authors claimed leakage of cystic fluid into the bloodstream due to high intracystic pressure and blunt dissection (3, 12). In our case, we believe that the high intracystic pressure coupled with blunt dissection must have been the cause of leakage of cystic contents through this vein into the circulation with no apparent macroscopic rupture. So, the same aetiology may also be effective in our case. In reviewing the literature, a few anaphylactic reactions have been reported with no apparent macroscopic rupture of the hydatid cysts (1, 12).

When there is unexpected or sudden, rapidly progressive haemodynamic and respiratory problems, the possibility of an anaphylactic reaction should always be considered in respect to an HC rupture, and the diagnosis should be made immediately. Initially, the aim of treatment should be to restore both adequate cardiac output and circulatory competency (2, 13). Some reports have advised use of vasopressors with alpha as well as beta stimulating properties (2, 5, 13). Epinephrine is the most appropriate drug of choice in the management of bronchospasm and massive peripheral vasodilation, which occur in anaphylaxis and sometimes a high dose may be necessary and the infusion may have to be maintained for a long time (2, 13).

In addition to epinephrine, intravascular volume, vascular tone and cardiac output should be supported with colloid or crystalloid fluids (5). In our case, we received a response within 20 minutes to epinephrine, colloid or crystalloid fluids. Besides, inhalation anaesthetics should be stopped and 100% oxygen administered for control of the

airway and bronchospasm. Antihistamines are useful prophylactically and may also prevent further histamine binding after the development of anaphylactic reactions (2, 5). Corticosteroids should be given prophylactically to diminish the airway swelling and prevent recurrence of symptoms. Extubation should not be immediate. Airway swelling and inflammation may continue for hours (7).

CONCLUSION

It should be kept in mind that anaphylaxis can occur despite all the precautionary measures and absence of rupture of the hydatid cyst or spillage of the cyst to the circulation or into the surrounding tissues.

The anaesthetist should be aware of anaphylactoid reaction and be prepared for treatment. Consequently, a close monitoring for early diagnosis and appropriate management of anaphylaxis are essential to stabilize the patient and produce the best outcome.

REFERENCES

1. Buyuk Y, Turan AA, Uzun I, Aybar Y, Cin O, Kurmaz G. Non-ruptured hydatid cyst can lead to death by spread of cyst content into bloodstream: an autopsy case. *Eur J Gastroenterol Hepatol* 2005; **17**: 671–3.
2. Jakubowski MS, Barnard DE. Anaphylactic shock during operation for hydatid disease. *Anesthesiology* 1971; **34**: 197–9.
3. Kol IO, Duger C, Kaygusuz K, Gursoy S, Aydin C, Mimaroglu C. Perioperative anaphylactic shock in a patient with unruptured hepatic hydatid cyst. *Anaesth Pain Intensive Care* 2011; **15**: 45–7.
4. Yahya AI, Przybylski J, Foud A. Anaphylactic shock in a patient with ruptured hydatid liver cyst owing to trivial abdominal trauma. *J R Coll Surg Edinb* 1997; **42**: 423–4.
5. Khanna P, Garg R, Pawar D. Intraoperative anaphylaxis caused by a hepatic hydatid cyst. *Singapore Med J* 2011; **52**: E18–9.
6. Nel L, Eren E. Peri-operative anaphylaxis. *Br J Clin Pharmacol* 2011; **71**: 647–58.
7. Hepner DL, Castells MC. Anaphylaxis during the perioperative period. *Anesth Analg* 2003; **97**: 1381–95.
8. Laxenaire MC, Mertes PM. Anaphylaxis during anaesthesia. Results of a two-year survey in France. *Br J Anaesth* 2001; **87**: 549–58.
9. Sola JL, Vaquerizo A, Madariaga MJ, Opla JM, Bondia A. Intraoperative anaphylaxis caused by a hydatid cyst. *Acta Anaesthesiol Scand* 1995; **39**: 273–4.
10. Khoury G, Jabbour-Khoury S, Soueidi A, Nabbout G, Baraka A. Anaphylactic shock complicating laparoscopic treatment of hydatid cysts of the liver. *Surg Endosc* 1998; **12**: 452–4.
11. Kambam JR, Dymond R, Krestow M, Handte RE. Efficacy of histamine H1 and H2 receptor blockers in the anesthetic management during operation for hydatid cysts of liver and lungs. *South Med J* 1988; **81**: 1013–15.
12. Sanei B, Hashemi SM, Mahmoudieh M. Anaphylactic shock caused by nonruptured hydatid cyst of the liver. *J Gastrointest Surg* 2008; **12**: 2243–5.
13. Currie M, Kerridge RK, Bacon AK, Williamson JA. Crisis management during anaesthesia: anaphylaxis and allergy. *Qual Saf Health Care* 2005; **14**: e19.