

# Flail hip joint following periacetabular tumor resection of the pelvis using upper surface of the femoral neck as a saddle: A case report

MASATSUGU TAKAMI<sup>1</sup>, MAKOTO IEGUCHI<sup>2</sup>, MASANARI AONO<sup>3</sup>, MANABU HOSHI<sup>2</sup>,  
JUN TAKADA<sup>2</sup>, NAOTO OEBISU<sup>2</sup> and TADASHI IWAI<sup>2</sup>

<sup>1</sup>Department of Orthopedic Surgery, Hanwa Sumiyoshi General Hospital, Osaka 558-0041;

<sup>2</sup>Department of Orthopedic Surgery, Osaka City Graduate School of Medicine, Osaka 545-0051;

<sup>3</sup>Department of Orthopedic Surgery, Osaka City General Hospital, Osaka 534-0021, Japan

Received October 27, 2014; Accepted August 20, 2015

DOI: 10.3892/ol.2015.3756

**Abstract.** Reconstruction following periacetabular tumor resection of the pelvis is one of the most challenging issues in limb salvage surgery. An ideal procedure has still not been established. There are several reconstruction methods available, including arthrodesis, pseudoarthrosis, resection arthroplasty, prosthetic arthroplasty, saddle prosthesis, allograft and hip transposition. In our hospital, we have been using a flail hip joint procedure without reconstruction. Herein, we report good extremity function following a flail hip joint procedure which used the upper surface of the femoral neck as a saddle facing the remaining ilium. To the best of our knowledge, among the reported flail hip joint cases, this procedure has never been used. The patient is able to walk without any pain for several hundred meters with a shoe lift but without a cane, as observed at a 20-year follow-up. The authors consider that the flail hip joint using the upper surface of the femoral neck as a saddle is a simple and effective method.

## Introduction

Reconstruction following periacetabular tumor resection of the pelvis is a major challenge in orthopedic oncology. There are several reconstruction methods available, including arthrodesis (1,2), pseudoarthrosis (1-3), resection arthroplasty (4-6), prosthetic arthroplasty (7,8), saddle prosthesis (9) and hip transposition (10). Most of these reconstruction methods have associated complications. The most common complications are deep infection, wound skin necrosis and aseptic loosening of implants. At Osaka City University Hospital (Osaka, Japan),

doctors have been using the method of flail hip joint without reconstruction. Compared with the results obtained with other types of reconstruction methods, complication rates with the flail hip joint method appear to be acceptable, and enable relatively good extremity function (11). In the present study, we describe the case of a patient with excellent extremity function as observed on a long-term follow-up. The simple and highly effective procedure is described below.

## Case report

In August 1993, a 20-year-old male fell while driving a motorcycle. As pain subsequently developed in the left inguinal region, he visited the Department of Orthopedic Surgery at Osaka City University Hospital for treatment. Radiography revealed an osteolytic lesion in the left pubis, ischium and acetabulum (Fig. 1). After an open biopsy revealed Ewing sarcoma, preoperative radiotherapy (61 Gy) and chemotherapy were administered. In February 1994, the tumor was resected, and a flail hip joint was implemented. At that time, we placed the head of the femur inside the pelvis using the upper surface of the femoral neck as a saddle facing the remaining ilium in order to provide bony support (Fig. 2). The concavity of the upper surface of the femoral neck articulated well with the remaining ilium (Fig. 3). The patient had a deep infection and was conservatively treated with irrigation and antibiotics. He demonstrated a good recovery within a month. He is now working at a shop 20 years after the surgery. Although the patient has a 5-cm leg-length discrepancy, he is able to walk several hundred meters using a 5-cm shoe lift but without a cane.

Written informed consent was obtained from the patient for publication of this case report and the accompanying images. The study was approved by the ethics committee of Hanwa Sumiyoshi General Hospital (Osaka, Japan).

## Discussion

When treating patients with tumors that require sacrificing the acetabular region in the pelvis, our hospital has been performing the flail hip joint procedure rather than reconstruction surgeries.

---

*Correspondence to:* Dr Masatsugu Takami, Department of Orthopedic Surgery, Hanwa Sumiyoshi General Hospital, 3-2-9 Minamiumiyoshi, Sumiyoshiku, Osaka 558-0041, Japan  
E-mail: a1971452005@yahoo.co.jp

**Key words:** flail hip joint, pelvic tumor, pelvic reconstruction

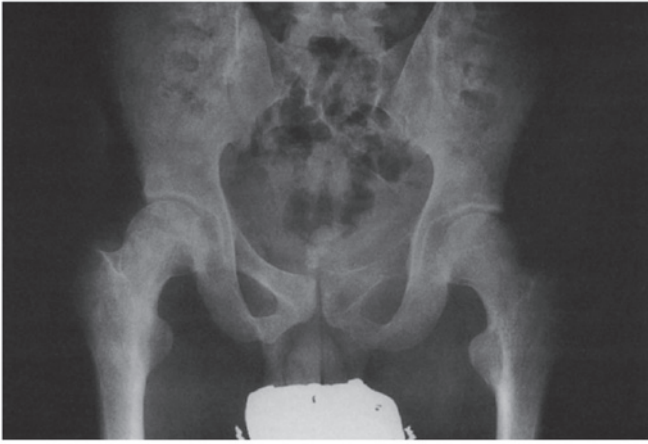

Figure 1. Plain radiograph revealing a lytic mass involving the left pubis, ischium and acetabulum.

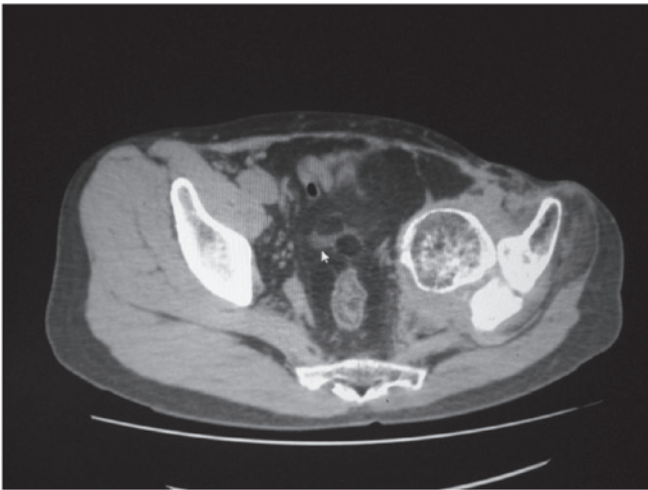


Figure 2. Computed tomography scan revealing osseous resorption and formation, indicating an avascular necrosis-like lesion of the femoral head.

High complication rates have been reported with various types of reconstruction procedures. The common complications are wound healing, aseptic loosening of the implant and, most frequently, deep infections. Hillmann *et al* (12) reported a complication rate of 50% in 110 patients following reconstruction, with complications including infections, skin problems and hematoma. Abudu *et al* (7) reported a complication rate of 60% in 34 patients, with complications including infection, dislocation and visceral injury. We consider that it is best to avoid the use of foreign parts as much as possible in order to avoid infection. For this reason, the flail hip joint is considered to be the optimal procedure. We also support the work of Gebert *et al* (13) who used only small foreign parts when they performed hip transposition.

One disadvantage of the flail hip joint is the resulting high leg-length discrepancy. However, when the femoral head moves upwards, dead space decreases and operative wounds are likely to heal more easily. After patients are cured of the sarcoma, it is possible to perform limb lengthening via callotasis (10). In a variety of reconstruction methods following acetabular tumor resection, certain surgeons resect

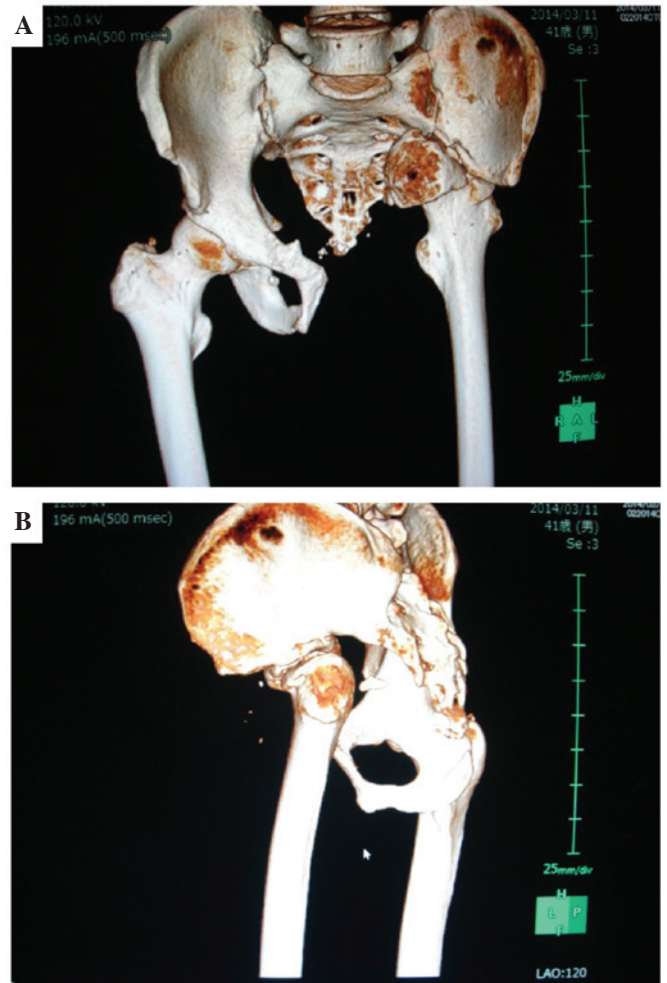


Figure 3. Three-dimensional computed tomography scan demonstrating the association between the femoral neck and the remaining ilium in the (A) anterior and (B) lateral view.

the femoral head and neck (4,5,14). Other surgeons do not resect the femoral head (6,10,11,13,14). In cases in which the femoral head is not resected, extensive surgical procedures might cause blood supply loss to the femoral head and result in avascular necrosis of the femoral head.

When treating the present case, we did not resect the femoral head and neck, but used the upper side of the femoral neck as a saddle. Computed tomography revealed osseous resorption and formation, indicating an avascular necrosis-like lesion of the femoral head (Fig. 2). However, we consider that weight bearing might be transmitted between the upper side of the femoral neck and the remaining ilium. We believe that even if femoral head necrosis is observed in these cases, it is not related to the functional outcome.

The Musculoskeletal Tumor Society (MSTS) score (15) in our case was 27 points (90%). The MSTS score is scored as 0-5 for six categories (emotional acceptance, function, pain, walking ability, support and gait). The score of this patient was notably high (90%) when compared with the mean MSTS scores of different reconstruction methods, which range from 30-70% (2,4,6-10).

We consider that this procedure should be limited to cases in which the uninvolved acetabular region is capable

of providing sufficient bony support. However, the use of the flail hip joint using the upper side of the femoral neck as a saddle is a simple and effective method.

## References

1. Enneking WF and Dunham WK: Resection and reconstruction for primary neoplasm involving the innominate bone. *J Bone and Joint Surg Am* 60: 731-746, 1978.
2. Fuchs B, O'Conner MI, Kaufman KR, Padgett DJ and Sim FH: Iliofemoral arthrodesis and pseudoarthrosis: a long-term functional outcome evaluation. *Clin Ortho Relat Res* 397: 29-35, 2002.
3. Steel HH: Partial or complete resection of the hemipelvis. An alternative to hindquarter amputation for periacetabular chondrosarcoma of the pelvis. *J Bone and Joint Surg Am* 60: 719-730, 1978.
4. Schwartz AJ, Kiatisevi P, Eilber FC, Eilber FR and Eckardt JJ: The Friedman-Eilber resection arthroplasty of the pelvis. *Clin Orthop Relat Res* 467: 2825-2830, 2009.
5. Pant R, Moreau P, Ilyas I, Paramasivan ON and Younge D: Pelvic limb-salvage surgery for malignant tumors. *Int Orthop* 24: 311-315, 2001.
6. Kusuzaki K, Shinjo H, Kim W, Nakamura S, Murata H and Hirasawa T: Resection hip arthroplasty for malignant pelvic tumor. Outcome in 5 patients followed more than 2 years. *Acta Orthop Scand* 69: 617-621, 1998.
7. Abudu A, Grimer RJ, Cannon SR, Carter SR and Sneath RS: Reconstruction of the hemipelvis after the excision of malignant tumors. Complications and functional outcome of prostheses. *J Bone and Joint Surg Br* 79: 773-779, 1997.
8. Ueda T, Kakunaga S, Takenaka S, Araki N and Yoshikawa H: Constrained total hip megaprosthesis for primary periacetabular tumors. *Clin Orthop Relat Res* 471: 741-749, 2013.
9. Renard AJ, Veth RP, Schreuder HW, Pruszczynski M, Keller A, van Hoesel Q and Bökkerink JP: The saddle prosthesis in pelvic primary and secondary musculoskeletal tumors: functional results at several postoperative intervals. *Arch Orthop Trauma Surg* 120: 188-194, 2000.
10. Gebert C, Wessling M, Hoffman C, Roedl R, Winkelmann W, Gosheger G and Harges J: Hip transposition as limb salvage procedure following the resection of periacetabular tumors. *J Surg Oncol* 103: 269-275, 2011.
11. Takami M, Ieguchi M, Takamatsu K, Kitano T, Aono M, Ishida T and Yamano Y: Functional evaluation of flail hip joint after periacetabular resection of the pelvis. *Osaka City Med J* 43: 173-183, 1997.
12. Hillmann A, Hoffmann C, Gosheger G, Roedl R, Winkelmann W and Ozaki T: Tumors of the pelvis: complications after reconstruction. *Arch Orthop Trauma Surg* 2003: 340-344, 2003.
13. Gebert C, Gosheger G and Winkelmann W: Hip transposition as a universal surgical procedure for periacetabular tumors of the pelvis. *J Surg Oncol* 99: 169-172, 2009.
14. Nilsson U, Kreiberg A, Olsson E and Stark A: Function after pelvic tumour resection involving the acetabular ring. *Int Orthop* 6: 27-33, 1982.
15. Enneking WF, Dunham W, Gebhardt MC, Malawar M and Prichard DJ: A system for the functional evaluation of reconstructive procedures after surgical treatment of the musculoskeletal system. *Clin Orthop Relat Res* 286: 241-246, 1993.