



#SPRINGMESSAGE("ENUM.\${ENUM.CLASS.SIMPLENAME}.\${ENUM.NAME()}!\${SUFFIX}")

REVISED **Case Report: Neuropathic pain in a patient with congenital insensitivity to pain [version 2; referees: 2 approved]**

Daniel W. Wheeler¹, Michael C.H. Lee¹, E. Katherine Harrison², David K. Menon¹, C. Geoffrey Woods³

¹Division of Anaesthesia, University of Cambridge, Cambridge, CB2 0QQ, UK

²School of Clinical Medicine, University of Cambridge, Cambridge, CB2 0SP, UK

³Department of Medical Genetics, University of Cambridge, Cambridge, CB2 0QQ, UK

v2 **First published:** 26 Jun 2014, 3:135 (doi: [10.12688/f1000research.2642.1](https://doi.org/10.12688/f1000research.2642.1))
Latest published: 19 Jun 2015, 3:135 (doi: [10.12688/f1000research.2642.2](https://doi.org/10.12688/f1000research.2642.2))

Abstract

We report a unique case of a woman with Channelopathy-associated Insensitivity to Pain (CIP) Syndrome, who developed features of neuropathic pain after sustaining pelvic fractures and an epidural hematoma that impinged on the right fifth lumbar (L5) nerve root. Her pelvic injuries were sustained during painless labor, which culminated in a Cesarean section. She had been diagnosed with CIP as child, which was later confirmed when she was found to have null mutations of the *SCN9A* gene that encodes the voltage-gated sodium channel Nav1.7. She now complains of troubling continuous buzzing in both legs and a vice-like squeezing in the pelvis on walking. Quantitative sensory testing showed that sensory thresholds to mechanical stimulation of the dorsum of both feet had increased more than 10-fold on both sides compared with tests performed before her pregnancy. These findings fulfill the diagnostic criteria for neuropathic pain. Notably, she mostly only experiences the negative symptoms (such as numbness and tingling, but also electric shocks), and she has not reported sharp or burning sensations, although the value of verbal descriptors is somewhat limited in a person who has never felt pain before. However, her case strongly suggests that at least some of the symptoms of neuropathic pain can persist despite the absence of the Nav1.7 channel. Pain is a subjective experience and this case sheds light on the transmission of neuropathic pain in humans that cannot be learned from knockout mice.

Open Peer Review

Referee Status:

	Invited Referees	
	1	2
REVISED version 2 published 19 Jun 2015	 report	 report
↑	↑	↑
version 1 published 26 Jun 2014	 report	 report

1 Frank van Eijs, St. Elisabeth Hospital
Netherlands

2 Juan D. Ramirez, University of Oxford UK

Discuss this article

Comments (0)

Corresponding author: Daniel W. Wheeler (dan.wheeler@gmail.com)

How to cite this article: Wheeler DW, Lee MCH, Harrison EK *et al.* **Case Report: Neuropathic pain in a patient with congenital insensitivity to pain [version 2; referees: 2 approved]** *F1000Research* 2015, 3:135 (doi: [10.12688/f1000research.2642.2](https://doi.org/10.12688/f1000research.2642.2))

Copyright: © 2015 Wheeler DW *et al.* This is an open access article distributed under the terms of the [Creative Commons Attribution Licence](https://creativecommons.org/licenses/by/4.0/), which permits unrestricted use, distribution, and reproduction in any medium, provided the original work is properly cited.

Grant information: The author(s) declared that no grants were involved in supporting this work.

Competing interests: No competing interests were disclosed.

First published: 26 Jun 2014, 3:135 (doi: [10.12688/f1000research.2642.1](https://doi.org/10.12688/f1000research.2642.1))

REVISED Amendments from Version 1

The revised version includes a broader discussion of the concept of pain when expressed by a person with congenital insensitivity to pain. It includes our patient's DN4 neuropathic pain questionnaire results, and the intensity of the pain she experiences on a numeric rating scale. We have also made corrections and additions according to the reviewers' comments.

See referee reports

Case

There has been an explosion of interest in Nav1.7 as a potential therapeutic target for novel analgesics, as mutations in *SCN9A* are associated with profoundly altered pain thresholds¹. Perhaps the greatest level of interest has been reserved for those very rare individuals with autosomal recessive mutations that truncate the protein Nav1.7 resulting in a complete lack of expression of the ion channel. The result is Channelopathy-associated Insensitivity to Pain (CIP) Syndrome: a complete absence of pain sensation, while all other sensory modalities apart from the sense of smell remain intact. Here we describe the experiences of a Caucasian 37-year-old patient with CIP whose older sister, but neither of her parents or other family members, is also affected. Other than a variety of injuries to the cornea and tongue, burns and relatively minor fractures sustained during childhood and now ascribed to CIP, there was no other medical history of note. Nonetheless, after childbirth she developed symptoms that she now readily describes as pain, and which has neuropathic features. We believe that this case report provides insights into the mechanisms of neuropathic pain, dissecting "positive" from "negative" symptomatology, and shows that it is possible to experience neuropathic pain in the absence of prior experience of acute pain.

Our patient had been recognized as having CIP aged 7, diagnosed at the same time as her older sister and confirmed 18 years later by

finding bi-allelic heterozygous null mutations of *SCN9A* in exon 29 (c.4975T>A p.K1659X) and exon 22 (c.3699-3709delATGGATAGCAT p.I1235LfsX2). The *SCN9A* gene on chromosome 2q24.3 encodes the alpha-subunit of the Nav1.7 voltage-gated sodium channel, which is expressed at high levels in small-diameter peripheral nociceptive neurons².

She sustained painless pelvic fractures, presumably during labor, which were not recognized for two months. By then, examination revealed significant weakness in both legs, worse on the right, and with both ankle reflexes absent. We subsequently compared the results of formal quantitative sensory testing three months post-injury to those obtained four years pre-injury. Sensory thresholds to heat and cold in the foot dorsum were broadly similar on both sides (Table 1), and should be interpreted in the context of someone who has never felt pain. However, thresholds to mechanical (von Frey) stimulation of the dorsum of both feet were increased more than 10-fold bilaterally. Imaging studies revealed multiple fractures of both sacral wings and of the superior and inferior pubic rami bilaterally (Figure 1a). Furthermore, there was an extensive hematoma extending into the left iliopsoas, right obturator externus and spinal canal, causing occlusion of the thecal sac at the level of the fifth lumbar (L5) and first sacral (S1) intervertebral space (Figure 1b, 1c and 1d). The fractures were attributed to transient osteoporosis of pregnancy, and their severity to her continued walking in the face of CIP. However, shortly after the fractures were diagnosed, bone densitometry studies and all serum bone profile results were found to be normal.

Two months later, four months after delivery, she reported troubling continuous buzzing and electric shocks in both legs, and a vice-like squeezing in the pelvis when she walked: symptoms that are consistent with neuropathic pain³. These symptoms did not respond to the anti-neuropathic drug gabapentin, and persist six years after the delivery. Further treatment has focused on physiotherapy and conservative measures such as pacing and activity management.

Table 1. Temperature and mechanical thresholds of the dorsum of both feet before and after childbirth (baseline temperature 32°C).

Body part tested	Dorsum right foot		Dorsum left foot	
	Pre-delivery	Post-delivery	Pre-delivery	Post-delivery
"Feels cool" (°C)	28.6	20.0	23.6	25.7
"Feels warm" (°C)	42.8	48.7	47.6	46.4
"Painfully cold" (°C)	14.5	20.6	9.7	17.9
"Painfully hot" (°C)	48.0	46.6	>50.0	>52.0
Mechanical detection threshold (Von Frey filament, g)	0.04	0.65	0.02	0.99

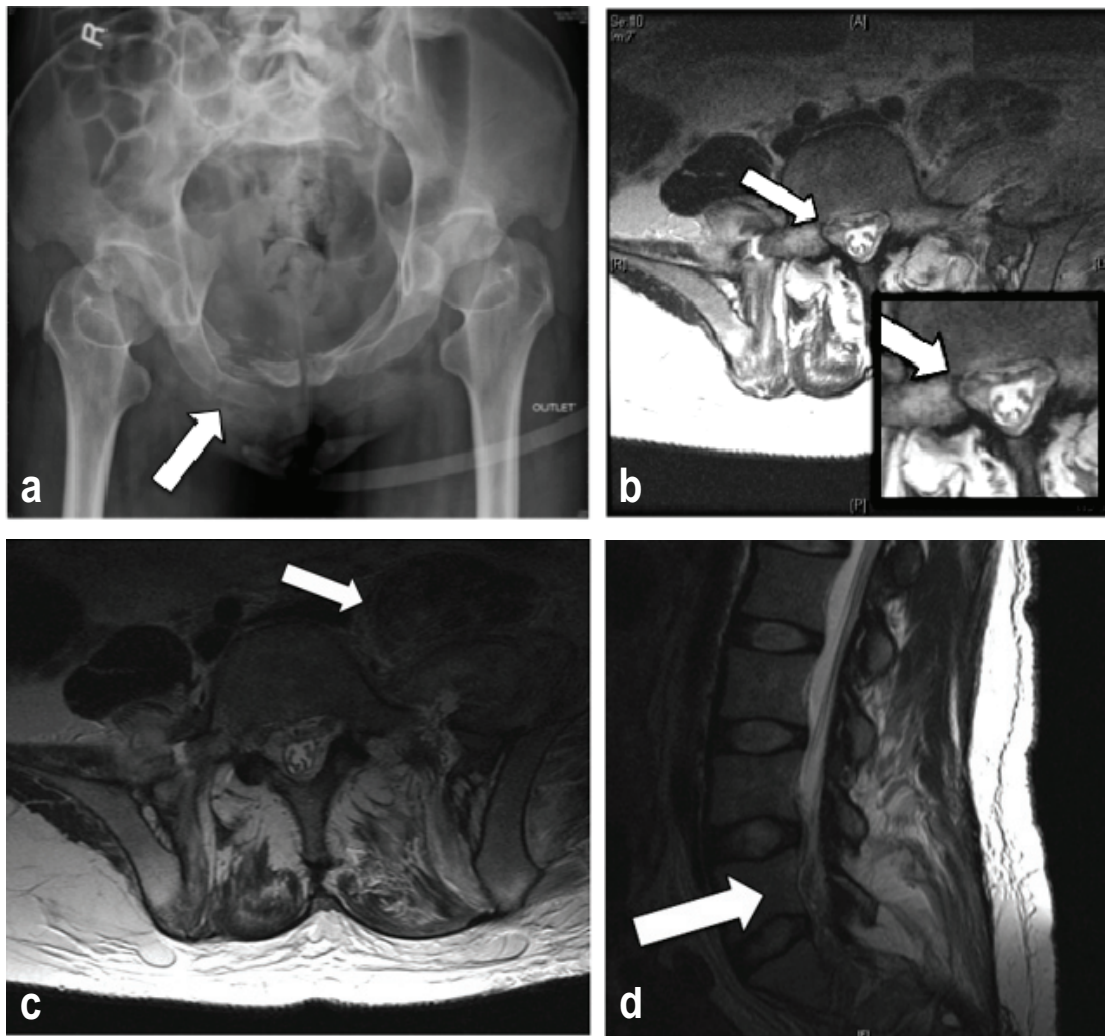


Figure 1. **a)** an anteroposterior X-ray outlet view of the patient's pelvis showing multiple fractures of the superior and inferior pubic rami; **b)** axial T2-weighted non-enhanced magnetic resonance image plus magnification showing hematoma adjacent to the right L5 nerve root at the exit foramen (arrow); **c)** a more cranial axial view showing the extent of the pelvic hematoma, and **d)** a sagittal view at the right exit foramina showing hematoma around the distal cauda equina.

Discussion

Neuropathic pain arises as a direct consequence of a lesion or disease affecting the somatosensory system, and is characterized according to four criteria: pain distribution; the link between distribution and history; confirmatory tests of neurologic status demonstrating sensory signs confined to the territory of the lesioned nerve, and further confirmatory diagnostic tests to identify the lesion or disease entity underlying the neuropathic pain³. The history, examination and investigations that we have described fulfill these criteria. We therefore believe that this patient has definite neuropathic pain, although it is manifested mostly by numbness, tingling, electric shocks and pressure, rather than stabbing or burning, but is nonetheless becoming increasingly debilitating.

It could be argued that the sensations described by our patient do not represent pain as understood by those without CIP. The International Association for the Study of Pain (IASP), however, defines pain as an unpleasant sensory and emotional experience associated with actual or potential tissue damage, or described in terms of such damage. The IASP also acknowledges that application of the word 'pain' is learnt in early life (<http://www.iasp-pain.org/Taxonomy?navItemNumber=576#Pain>). There is psychometric and neuroimaging evidence that patients with CIP understand what the word 'pain' means, as they are able to empathize with behavioral and verbal expressions of pain in normal individuals⁴.

Since her injury, our patient has started using a variety of means of describing pain with which most will be familiar. She reports that

her right hip and pelvis still “hurt” a great deal, using descriptors such as “tight” and “aching”, and that she “suffers” if she walks too far or doesn’t wear an orthotic heel raise. At rest, these symptoms resolve, but she is left with “tingling”, “buzzing” and “electric shocks”. Furthermore she also describes headaches that respond to acetaminophen, “the sting of a graze”, “the sharpness of an exposed gum”, and “back aches”, “period pains” and “stomach cramps” that arose after pregnancy.

Our patient has also exhibited behavior consistent with a person in pain. She sought treatment in the local Pain Clinic (with DWW) for her symptoms, which suggests that these “buzzing” and “vice-like” descriptors had strong aversive-motivational qualities. We contend that these descriptions, in the context of the injury sustained and the resultant behaviors, are adequate to fulfill the IASP definition of pain, and have acknowledged and managed her report of pain as such.

A visual analog or numeric rating scale (NRS) is undoubtedly useful in normal individuals, and our patient rates her current pain intensity in the right hip and leg as between 0 and 4 on a 10-point NRS. However, the scale should not be required to validate the report of pain by this patient. Our patient currently scores 5 in the Douleur Neuropathique 4 (DN4) diagnostic neuropathic pain questionnaire, answering ‘yes’ to the presence of electric shocks, tingling and numbness, and having documented hypoesthesia to touch and pinprick in the affected area five years after the original injury⁵. A score >4 provides 90% specificity for neuropathic pain in individuals with premorbid normal nociceptive physiology, but we judge that the diagnosis of neuropathic pain in our patient stands independently of the DN4 score, and question the value of neuropathic pain questionnaires in patients with CIP.

Conclusion

The Nav1.7 channel plays a crucial role in pain transmission; however, this case shows that neuropathic pain can be initiated and maintained in its absence in humans, as well as in knockout mice⁶, although we cannot rule out that Nav1.7 may mediate sharp or burning sensations. Our data provide a further rational basis for seeking specific molecular substrates for neuropathic pain, some of which could act as mechanistic targets for new therapies for patients with symptoms of neuropathic pain.

Author contributions

All authors conceived the paper. MCL undertook the post-injury quantitative sensory testing and CGW the *SCN9A* genotyping. DWW wrote the first draft and final version, which was reviewed, revised and approved by all authors.

Competing interests

No competing interests were disclosed.

Grant information

The author(s) declared that no grants were involved in funding this work.

Acknowledgments

We are indebted to the late Dr David Bowsher, who kindly shared his pre-injury quantitative sensory testing data. We are grateful to our patient, who gave written consent for the publication of this report.

References

- Fischer TZ, Waxman SG: **Familial pain syndromes from mutations of the Nav1.7 sodium channel.** *Ann N Y Acad Sci.* 2010; **1184**: 196–207.
[PubMed Abstract](#) | [Publisher Full Text](#)
- Cox JJ, Reimann F, Nicholas AK, *et al.*: **An *SCN9A* channelopathy causes congenital inability to experience pain.** *Nature.* 2006; **444**(7121): 894–8.
[PubMed Abstract](#) | [Publisher Full Text](#)
- Treede RD, Jensen TS, Campbell JN, *et al.*: **Neuropathic pain: redefinition and a grading system for clinical and research purposes.** *Neurology.* 2008; **70**(18): 1630–5.
[PubMed Abstract](#) | [Publisher Full Text](#)
- Danziger N, Faillenot I, Peyron R: **Can we share a pain we never felt? Neural correlates of empathy in patients with congenital insensitivity to pain.** *Neuron.* 2009; **61**(2): 203–12.
[PubMed Abstract](#) | [Publisher Full Text](#)
- Bouhassira D, Attal N, Alchaar H, *et al.*: **Comparison of pain syndromes associated with nervous or somatic lesions and development of a new neuropathic pain diagnostic questionnaire (DN4).** *Pain.* 2005; **114**(1–2): 29–36.
[PubMed Abstract](#) | [Publisher Full Text](#)
- Nassar MA, Levato A, Stirling LC, *et al.*: **Neuropathic pain develops normally in mice lacking both Na(v)1.7 and Na(v)1.8.** *Mol Pain.* 2005; **1**: 24.
[PubMed Abstract](#) | [Publisher Full Text](#) | [Free Full Text](#)

Open Peer Review

Current Referee Status:



Version 2

Referee Report 29 July 2015

doi:10.5256/f1000research.7158.r9123



Juan D. Ramirez

Nuffield Department of Clinical Neurosciences, University of Oxford, Oxford, UK

The authors have addressed the points thoroughly and added substantial evidence to support their claims. It is a well documented report on such a unique condition.

`#springMessage("enum.${enum.class.simpleName}.${enum.name()}!${suffix}")`

Competing Interests: No competing interests were disclosed.

Referee Report 22 June 2015

doi:10.5256/f1000research.7158.r9122



Frank van Eijs

Department of Anaesthesiology, St. Elisabeth Hospital, Tilburg, Netherlands

Congratulations with your work.

`#springMessage("enum.${enum.class.simpleName}.${enum.name()}!${suffix}")`

Competing Interests: No competing interests were disclosed.

Version 1

Referee Report 17 September 2014

doi:10.5256/f1000research.2861.r6088



Juan D. Ramirez

Nuffield Department of Clinical Neurosciences, University of Oxford, Oxford, UK

This is an exciting report by Wheeler *et al.*, assessing the meaning of pain after a traumatic labour in a subject who has never experienced anything similar. This case is paramount for highlighting the importance of a detailed study of patients with inherited channelopathies.

Neuropathic pain has been established by IASP as pain arising as a consequence of damage to the somatosensory system. In this case the patient describes positive sensory phenomena in the form of buzzing and squeezing which is troubling and is accompanied by numbness which is often regarded as negative phenomena (positive and negative sensory abnormalities often co-exist in neuropathic pain states) so I would recommend changing the terms 'sensory loss' for both 'sensory gain and loss'.

One issue is whether what the subject describes is more akin to paraesthesia rather than pain as understood by healthy subjects in whom NaV 1.7 is functional. The IASP definition of pain is actually fairly broad including the term 'unpleasant sensory experience'. In the current case this sensory disturbance is an anatomically plausible distribution with evidence of a lesion to the somatosensory system.

The evidence comes from MRI that shows nerve root compression as a consequence of a haematoma. It would be helpful to have more sequences in order to demonstrate bilateral involvement and neurophysiology to define the extent of the nerve damage (sensory and motor).

The thermal and mechanical sensory testing is thorough and I would only recommend the authors to add the baseline temperature at which they started the assessment e.g. "32°C" added as part of the figure legend.

Finally, I would vouch for the use of the neuropathic pain symptom inventory for assessing in more detail the symptomatology of the subject ([Bouhassira et al., 2004](#)).

In general I believe this a relevant case that illustrates the need to carefully delineate new sensory symptoms in patients with congenital inability to experience pain and emphasises the distinct nature of neuropathic versus nociceptive pain states.

`#springMessage("enum.${enum.class.simpleName}.${enum.name()}${suffix}")`

Competing Interests: No competing interests were disclosed.

`#springMessage("enum.${enum.class.simpleName}.${enum.name()}${suffix}")` 12 Jun 2015

Daniel W. Wheeler, Division of Anaesthesia, University of Cambridge, UK

- *This is an exciting report by Wheeler et al., assessing the meaning of pain after a traumatic labour in a subject who has never experienced anything similar. This case is paramount for highlighting the importance of a detailed study of patients with inherited channelopathies.*

Thank you for your positive comments about our manuscript.

- *Neuropathic pain has been established by IASP as pain arising as a consequence of damage to the somatosensory system. In this case the patient describes positive sensory phenomena in the form of buzzing and squeezing which is troubling and is accompanied by numbness which is often regarded as negative phenomena (positive and negative sensory abnormalities often co-exist in neuropathic pain states) so I would recommend changing the terms 'sensory loss' for both 'sensory gain and loss'.*

We agree, and the text has been amended as suggested.

- *One issue is whether what the subject describes is more akin to paraesthesia rather than pain as understood by healthy subjects in whom NaV 1.7 is functional. The IASP definition of pain is actually fairly broad including the term ‘unpleasant sensory experience’. In the current case this sensory disturbance is an anatomically plausible distribution with evidence of a lesion to the somatosensory system.*

The evidence comes from MRI that shows nerve root compression as a consequence of a haematoma. It would be helpful to have more sequences in order to demonstrate bilateral involvement and neurophysiology to define the extent of the nerve damage (sensory and motor).

The patient was seen in the clinical setting. Routine neurological examination revealed sensory loss to touch already suggesting neuropathy. EMG and ENG were not performed, as neither would have altered the clinical management in this case.

Please see our response to Dr van Eijs for our comment on the MRI scan.

- *The thermal and mechanical sensory testing is thorough and I would only recommend the authors to add the baseline temperature at which they started the assessment e.g. “32°C” added as part of the figure legend.*

The table caption has been amended to indicate that the baseline temperature was 32°C.

- *Finally, I would vouch for the use of the neuropathic pain symptom inventory for assessing in more detail the symptomatology of the subject ([Bouhassira et al., 2004](#)).*

Please see our response to Dr van Eijs regarding the value of pain questionnaires in patients with CIP.

Competing Interests: No competing interests were disclosed.

Referee Report 11 September 2014

doi:[10.5256/f1000research.2861.r5741](https://doi.org/10.5256/f1000research.2861.r5741)



Frank van Eijs

Department of Anaesthesiology, St. Elisabeth Hospital, Tilburg, Netherlands

The presented aspects of the reported case are indeed interesting, however...

One cannot talk about pain if no pain is reported. Buzzing and a vice like squeezing of the pelvis is not the same as pain. The vice like squeezing of the pelvis may also have been due to the observed fractured pelvis. It is unclear if there indeed is subjective pain. If there is a report of pain there should also be an assessment of the visual analogue or numerical pain rating scale. Unfortunately this is not mentioned. Another clinical aspect is the missing of a DN4 score (douleur neuropathique 4 questionnaire). As I can see the score may not be more than 3 in which case the presence of neuropathic pain is unlikely.

The MRI scan of the L5-S1 interspace is not clear. It lacks a sagittal view. The cross-sectional view should be more clearly and preferentially showing more than 1 slice.

Suggestions:

1. Add the VAS or NRS of the pain intensity (probably 0?) Specify if pain scores are for the feet, legs or pelvis. If pain scores are not 0 then indeed there may possibly be neuropathic pain. In that case add the DN 4 score.
2. If there is no pain, symptoms should be mentioned as neuropathic or neuropathy instead of neuropathic pain. In that case also the title needs to be changed (e.g. neuropathy in a patient with congenital insensitivity to pain).
3. Add the sagittal view of the lumbar MRI. Show more than 1 cross-sectional view of the MRI. Specify if views are T1, T2 or contrast dye enhanced.

#springMessage("enum.\${enum.class.simpleName}.\${enum.name()}\${suffix}")

Competing Interests: No competing interests were disclosed.

#springMessage("enum.\${enum.class.simpleName}.\${enum.name()}\${suffix}") 12 Jun 2015

Daniel W. Wheeler, Division of Anaesthesia, University of Cambridge, UK

- *The presented aspects of the reported case are indeed interesting; however, one cannot talk about pain if no pain is reported. Buzzing and a vice like squeezing of the pelvis is not the same as pain. The vice like squeezing of the pelvis may also have been due to the observed fractured pelvis. It is unclear if there indeed is subjective pain. If there is a report of pain there should also be an assessment of the visual analogue or numerical pain rating scale. Unfortunately this is not mentioned. Another clinical aspect is the missing of a DN4 score (douleur neuropathique 4 questionnaire). As I can see the score may not be more than 3 in which case the presence of neuropathic pain is unlikely.*

The MRI scan of the L5-S1 interspace is not clear. It lacks a sagittal view. The cross-sectional view should be more clearly and preferentially showing more than 1 slice.

Suggestions:

- 1. Add the VAS or NRS of the pain intensity (probably 0?) Specify if pain scores are for the feet, legs or pelvis. If pain scores are not 0 then indeed there may possibly be neuropathic pain. In that case add the DN 4 score.*
- 2. If there is no pain, symptoms should be mentioned as neuropathic or neuropathy instead of neuropathic pain. In that case also the title needs to be changed (e.g. neuropathy in a patient with congenital insensitivity to pain)*

Response

The International Association for the Study of Pain (IASP) defines pain as an unpleasant sensory and emotional experience associated with actual or potential tissue damage, or described in terms of such damage. The IASP also acknowledges that application of the

word 'pain' is learnt in early life (<http://www.iasp-pain.org/Taxonomy?navItemNumber=576#Pain>). It is unclear what patients have been diagnosed with congenital insensitivity to pain (CIP) understand by the word 'pain'. However, there is psychometric and neuroimaging evidence they understand what the word 'pain' means, as they are clearly able to empathise with behavioural and verbal expressions of pain in normal individuals (Danziger *et al.*, 2009).

Our patient reports that her right hip and pelvis still "hurt" a great deal, using descriptors such as "tight" and "aching", and that she "suffers" if she walks too far or doesn't wear an orthotic heel raise. At rest, this "pain" resolves, but she is left with "tingling", "buzzing" and "electric shocks". **The patient in our report labelled her sensations as painful and we contend that description alone is adequate to fulfil the IASP definition of pain.** Furthermore she also describes headaches that respond to paracetamol, "the sting of a graze", "the sharpness of an exposed gum", and "back aches", "period pains and stomach cramps" that arose after pregnancy.

Our patient has also exhibited behavior consistent with a person in pain. She sought treatment in the local Pain Clinic (with DWW) for the sensations, which suggests that these "buzzing" and "vice-like" descriptors had strong aversive-motivational qualities. We believe that the simple verbal use of the word pain and behavioral response sufficed and have acknowledged and managed her report of pain as such. The visual analog or numeric rating scale (NRS) is undoubtedly useful in normal individuals, and our patient rates her current pain intensity in the right hip and leg as between 0 and 4 on a 10-point NRS. However, the scale should not be required to validate the report of pain by this patient.

The DN4 score aims to increase the specificity of a diagnosis of neuropathic pain, with a score >4 providing 90% specificity for neuropathic pain. The sensitivity of the questionnaire is not well documented and the specificity of lower scores for neuropathic pain is unclear. The score in our patient was 5, but as the scale was validated **in individuals with premorbid normal nociceptive physiology**, we judge that the diagnosis of neuropathic pain stands independently of the DN4 score.

We have added several additional paragraphs to the manuscript to address these points, which we hope you will find satisfactory.

- *Add the sagittal view of the lumbar MRI. Show more than 1 cross-sectional view of the MRI. Specify if views are T1, T2 or contrast dye enhanced.*

Response

The MRI scans are T2-weighted and non-contrast enhanced. An additional cross-sectional view and a sagittal view are included below (included as Figure 1c and 1d in the revised manuscript). The arrows indicate the presence of hematoma material in the psoas and adjacent to the cauda equina.

Competing Interests: No competing interests were disclosed.