



ELSEVIER

Contents lists available at ScienceDirect

Journal of Arrhythmia

journal homepage: www.elsevier.com/locate/joa

Case Report

Aortic perforation due to cardiac resynchronisation therapy defibrillator lead placement: Case report and medicolegal considerations



Antonino M. Grande, MD^{a,*}, Antonio Fiore, MD^a, Maurizio Merlano, MD^b,
Fabio Buzzi, MD^b, Alessandro Mazzola, MD^a

^a Divisione Cardiochirurgia IRCCS Policlinico San Matteo Pavia, Viale C. Golgi, 19, 27100 Pavia, Italy

^b Istituto Medicina Legale Università degli Studi Pavia, Via C. Forlanini, 12, 27100 Pavia, Italy

ARTICLE INFO

Article history:

Received 17 February 2015

Received in revised form

26 April 2015

Accepted 8 May 2015

Available online 16 June 2015

Keywords:

Aortic perforation

Cardiac resynchronization therapy

defibrillator

Implantable cardioverter defibrillator

Active lead

ABSTRACT

A 45-year-old woman with dilated cardiomyopathy was admitted for the upgrade of a previously implanted pacemaker. Echocardiography showed intraventricular dyssynchrony and a low ejection fraction (0.35). Treatment with a cardiac resynchronization therapy defibrillator (CRT-D) was selected and the device was implanted. CRT-D interrogation revealed proper function. Following procedure termination, the patient went into cardiac arrest and died despite resuscitation attempts. An autopsy revealed that the medial aspect of the right atrium was pierced by an active lead and that the aorta had a deep lesion, 2 mm in length, on its lateral aspect. We explain the probable pathogenesis of this patient's death.

© 2015 Japanese Heart Rhythm Society. Published by Elsevier B.V. All rights reserved.

1. Introduction

Cardiac perforation is a dreaded complication of transvenous pacemaker, cardiac resynchronization therapy defibrillator (CRT-D), and implantable cardioverter-defibrillator (ICD) lead placement because of the potential for critical morbidity and mortality.

2. Case report

We report the case of a 45-year-old woman affected by severe dilated cardiomyopathy who was admitted to our Cardiology Department for an upgrade of a previously implanted pacemaker. The patient received a VVI pacemaker implant for complete atrioventricular block 22 years earlier and an upgrade (DDD mode) 11 years later. Echocardiography revealed intraventricular dyssynchrony and a low ejection fraction (0.35). A CRT-D was selected for this patient and the device was implanted.

The procedure was performed under local anesthesia. Leads were inserted through the left subclavian vein: (a) an active fixation double catheter in the right ventricle, (b) a bipolar active fixation lead in the right auricle (Fig. 1), and (c) a bipolar lead introduced from the coronary sinus into the antero-lateral vein.

The previously implanted pacemaker and one atrial lead were removed (the old unipolar lead was left in the right ventricle) and a CRT device was connected to the new implanted leads. The atrial lead removal was uneventful. After satisfactory R-wave sensing (> 5 mV) and pacing thresholds (< 1.0 V at 0.5-ms pulse width) had been demonstrated, the patient underwent defibrillation threshold testing (DFT) to ensure proper device function. Sustained ventricular tachycardia and ventricular fibrillation were induced to make certain that the device was able to constantly sense, detect, and terminate arrhythmias with a shock at 25 J. During skin closure, the patient went into cardiac arrest with pulseless electrical activity. Cardiopulmonary resuscitation maneuvers were performed immediately and echocardiography showed intrapericardial effusion that was partially drained. After 1 h, pulseless electrical activity persisted, the patient was declared dead, and resuscitation attempts were halted.

The unexpected fatal outcome resulted in an allegation of medical negligence against the operating cardiologists. A board of physicians consisting of a forensic doctor and a heart surgeon conducted a post-mortem examination and analysis of the medical records.

At autopsy, approximately 180 cm³ of blood and clots were found inside the pericardial cavity. Careful inspection of the aorta showed a deep lesion, 2 mm in length, on the antero-lateral aspect of the vessel (Fig. 1) 2 cm above the valvular plane (Fig. 2). On the medial aspect of the right atrium, the lead metal extremity was implanted at the base of the auricle on the medial wall. The right atrium was very thin, with an

* Corresponding author. Tel.: +39 0382503515; fax: +39 0382503059.

E-mail address: amgrande@libero.it (A.M. Grande).

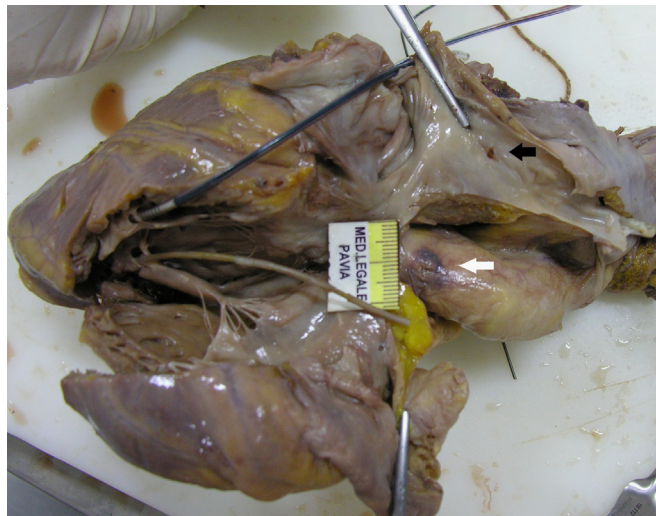


Fig. 1. The explanted heart: a small hematoma is evident on the antero-lateral aspect of the aorta (white arrow); the medial aspect of the right atrium shows the lesion where the lead metal extremity was implanted (black arrow).

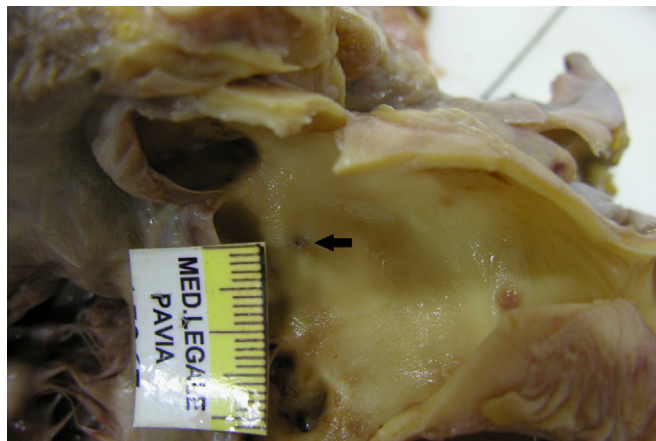


Fig. 2. The aorta opened: a pinpoint injury was noted 2 cm above the noncoronary cusp (black arrow). This was related to the lesion described on the adventitial portion of the aorta.

Table 1

Review of the literature: only five cases of atrial damage by a pacemaker lead with concomitant aortic wall perforation have been published.

Author	Device	Time after implant	Symptoms	Procedure	Outcome
Kalijusto [1]	P-M	14 days	Chest pain	Sternotomy	Alive
Kashani [2]	P-M active lead	1 day	Pain, dyspnea	Thorac/Sternot	Alive
Sticco [3]	P-M	14 days	Syncope	Thorac/Sternot	Alive
deRoux [4]	P-M active lead	End procedure	Hypotension	Thoracotomy	Dead
Di Marco [5]	P-M active lead	6 h	Ch. pain, hypot.	Sternotomy	Alive

average thickness of 2 mm. Histology showed abundant adipose tissue in its context, endocardial fibrosis, and numerous foci of inflammatory infiltration by various elements including lymphocytes and monocytes as well numerous plasma cells and eosinophils, clearly indicating myocarditis that was not recent.

The ascending aorta was incised and approximately 2 cm above the noncoronary cusp, a pinpoint injury related to the lesion described on the aortic adventia (Fig. 2) was noted.

3. Discussion

The pathogenetic mechanism underlying this patient's death can be explained in the following manner: the active lead (Fig. 1),

positioned in the right atrium medial aspect, perforated the thin atrial wall and the lateral aspect of the aortic wall. After aortic perforation, the lead initially remained inside its wall, which explains why the device interrogation revealed satisfactory R-wave sensing (> 5 mV) and pacing thresholds (< 1.0 V at 0.5-ms pulse width). The patient eventually underwent DFT to guarantee proper device function. At this point, the active lead, positioned inside the aorta like a cork, slipped out, causing cardiac tamponade. In a review of relevant literature, we identified only five cases [1–5] of atrial damage by a pacemaker lead with concomitant aortic wall perforation, as shown in Table 1. However, not all reports indicate whether the lead responsible for the cardiac laceration was active or passive.

A board of physicians conducted a post-mortem examination and their findings did not support a direct allegation of medical

negligence against the operating cardiologists who performed the ICD implant. The board analyzed the guidelines for cardiac pacing and cardiac resynchronization therapy and considered the indications for the procedure performed on the patient to be correct. The increased heart size shifted the right atrial appendage closer to the adjacent lateral aspect of the aorta. At the same time, the remarkable thinness of the right atrium was conducive to wall perforation. The perforation was not necessarily a result of malpractice in electrode positioning, but was also caused by other factors such as the pressure exerted during cardiac contraction. Moreover, since she was bearing a pacemaker, the patient could not undergo magnetic resonance imaging before the procedure to highlight the thicknesses of the cardiac wall. In addition, her pre-existing myocarditis undoubtedly reduced the chances of successful resuscitation.

Conflict of interest

The corresponding author, Dr. Antonino M. Grande, affirms on behalf of all co-authors that we have no conflicts of interest in connection with this article.

References

- [1] Kalijusto ML, Tønnessen T. Aortic perforation with cardiac tamponade two weeks after pacemaker implantation. *J Thorac Cardiovasc Surg* 2007;134:502–3.
- [2] Kashani A, Mehdiraz A, Fredman C, Barold S. Aortic perforation by active-fixation atrial pacing lead. *Pac Clin Electrophysiol* 2004;27:417–8.
- [3] Sticco CC, Barrett LO. Delayed cardiac tamponade by iatrogenic aortic perforation with pacemaker implantation. *J Thorac Cardiovasc Surg* 2006;131:480–1.
- [4] deRoux S. Fatality following right atrial perforation by a screw-in pacemaker electrode. *J Forensic Sci* 2005;50:1191–3.
- [5] Di Marco A, Nuñez E, Osorio K, et al. Atrial pacing lead: an unusual but serious complication. *Tex Heart Inst J* 2014;41:327–8.