

Aspergillus species: An emerging pathogen in onychomycosis among diabetics

T. M. Wijesuriya, J. Kottahachchi, T. D. C. P. Gunasekara, U. Bulugahapitiya¹, K. N. P. Ranasinghe², S. S. Neluka Fernando, M. M. Weerasekara

Department of Microbiology, Faculty of Medical Sciences, University of Sri Jayewardenepura, Gangodawila, Nugegoda, ¹Diabetic Clinic, Colombo South Teaching Hospital, Kalubowila, ²Tan-Galle Base Hospital, Tangalle, Hambantota, Sri Lanka

ABSTRACT

Introduction: Approximately, 33% patients with diabetes are afflicted with onychomycosis. In the past, nondermatophyte molds have been regarded as opportunistic pathogens; recently, *Aspergillus* species are considered as emerging pathogens of toenail infections. In Sri Lanka, the prevalence of *Aspergillus* species in onychomycosis among diabetics is not well documented. **Objective:** To determine the proportion of *Aspergillus* onychomycosis, risk factors and knowledge among diabetics. **Materials and Methods:** This was descriptive cross-sectional study. Three hundred diabetic patients were included. Clinical examinations of patients' toenails were performed by a clinical microbiologist. Laboratory identification was done, and pathogens were identified to the species level by morpho-physiological methods. All inferential statistics were tested at $P < 0.05$. **Results:** Among clinically suspected patients, 85% (255/300) were mycologically confirmed to have onychomycosis. *Aspergillus* species were most commonly isolated $n = 180$ (71%) followed by dermatophytes, yeasts, and other molds $n = 75$ (29%). Of the patients having *Aspergillus* onychomycosis, 149 (83%) were in the >50 age group. In men, *Aspergillus* onychomycosis was seen in 82%. Among patients who had *Aspergillus* nail infection, 114 (63%) had diabetes for a period of >15 years. Among patients who were engaged in agricultural activities, 77% were confirmed to have infected nails due to *Aspergillus* species. **Conclusion:** *Aspergillus niger* was the most common pathogen isolated from toenail infection. *Aspergillus* species should be considered as an important pathogen in toenail onychomycosis in diabetic patients. Risk factors associated with *Aspergillus* onychomycosis were age, gender, duration of diabetes, length of exposure to fungi, and occupation.

Key words: *Aspergillus* species, diabetics, onychomycosis, Sri Lanka

INTRODUCTION

Onychomycosis accounts for about a half of all nail abnormalities.^[1] Approximately, 33% patients with diabetes are afflicted with onychomycosis.^[2] The predisposing factors are age, gender, duration of diabetes, time of exposure,

and altered host immune response.^[3-6] Recently, *Aspergillus* species were considered as emerging pathogens of toenail infections.^[7-10] The proportion of *Aspergillus* infection in onychomycosis has been reported as 50–60%.^[11,12] In Sri Lanka, the prevalence of *Aspergillus* species in onychomycosis among diabetics is not well documented; therefore, we investigated the proportion of *Aspergillus* onychomycosis, risk factors and knowledge among diabetic patients presenting to a tertiary care hospital.

Corresponding Author: Dr. S. S. Neluka Fernando, Department of Microbiology, Faculty of Medical Sciences, University of Sri Jayewardenepura, Gangodawila, Nugegoda, Sri Lanka. E-mail: fneluka@gmail.com

Access this article online

Quick Response Code:



Website:
www.ijem.in

DOI:
10.4103/2230-8210.167565

This is an open access article distributed under the terms of the Creative Commons Attribution-NonCommercial-ShareAlike 3.0 License, which allows others to remix, tweak, and build upon the work non-commercially, as long as the author is credited and the new creations are licensed under the identical terms.

For reprints contact: reprints@medknow.com

Cite this article as: Wijesuriya TM, Kottahachchi J, Gunasekara T, Bulugahapitiya U, Ranasinghe K, Neluka Fernando SS *et al.* *Aspergillus* species: An emerging pathogen in onychomycosis among diabetics. Indian J Endocr Metab 2015;19:811-6.

MATERIALS AND METHODS

Study design

A descriptive cross-sectional study conducted at the Diabetic Clinic at Colombo South Teaching Hospital.

Ethics

Ethical approval for the study was granted by the Ethical Committee of Colombo South Teaching Hospital (228) and University of Sri Jayawardanapura (02) Sri Lanka.

Three hundred diabetic patients attending the diabetic clinic were included in the study after obtaining their informed written consent. After taking a thorough history and demographic details, patients were asked questions on knowledge on onychomycosis, about the causative agents, risk factors, and preventive measures. Clinical examinations of patients' toenails for onychomycosis were performed by a clinical microbiologist. Different nail abnormalities such as nail thickening, brittle nails, pitting of nails, cracking of nails, and any visible change in color of nail plate were recorded. Samples of affected toenails were collected after cleaning with 70% ethyl alcohol using sterile scissors or nail-cutters. The nail clippings were collected to black papers (5" × 5") to form of flat packets and transported to the laboratory.

The nail clippings placed on a pre-labeled clean glass slides were immersed in a drop of 20% potassium hydroxide (KOH) and incubated at 37°C for 10–15 min. In addition, thick nail clippings processed as above were kept in humidified petri dishes overnight at room temperature. The slides were examined under a microscope. The nail samples were inoculated on quality controlled Sabouraud's dextrose agar (Oxoid, UK), with and without antimicrobials (chloramphenicol [0.05 g/l], and cycloheximide [100 mg/l]). The inoculated specimens were incubated at 25–30°C aerobically for up to 3 weeks and examined for any growth regularly. Identification of the fungi was done by examining colony morphology and microscopic examination of lactophenol blue preparation. The slides were examined for the presence of characteristic hyphae, macroconidia, and microconidia.

Statistics

Data were analyzed using SPSS version 16 (Chicago; SPSS Inc.). All inferential statistics were tested at $P < 0.05$. Frequency tables and cross tables were obtained to achieve the objectives of the study.

RESULTS

Three hundred diabetic patients with clinically suspected onychomycosis, comprising 92 men (31%) and 208 women

(69%), aged 30–90 (mean age, 58.3) years were included in the study. Among these patients with toenail onychomycosis, 50 (16.7%) showed involvement of the first toenail alone, 80 (27%) showed involvement of two toenails and 170 (57%) showed involvement of multiple toenails.

Among clinically suspected patients, 255 patients (255/300, 85%) were mycologically confirmed to have onychomycosis: 85 men (age range 30–90 years, mean 60.05, median 61, standard deviation [SD] 11.82) and 170 women (age range 30–84 years, mean 58.05, median 58.5, SD 11.00). Male/female ratio is 1:2. All the patients with mycologically confirmed onychomycosis had type II diabetes mellitus.

Of the 255 patients with confirmed onychomycosis, culture positivity alone was seen in 28 (11%) cases, both culture and KOH positivity was seen in 226 (88.9%) cases. *Aspergillus* onychomycosis was confirmed after obtaining positive results from both KOH and culture. Of the fungal pathogens isolated from the mycological investigations, *Aspergillus* species were most commonly isolated ($n = 180$ [71%]). Among *Aspergillus* species, *Aspergillus niger* (76%) was predominant [Tables 1 and 2].

Table 1: The spectrum of *Aspergillus* species isolated from toenails

<i>Aspergillus</i> species	Number of isolates (%)
<i>Aspergillus niger</i>	137 (76)
<i>Aspergillus flavus</i>	21 (12)
<i>Aspergillus terreus</i>	14 (8)
<i>Aspergillus fumigatus</i>	8 (4)

Table 2: *Aspergillus* species isolated from the toenails

Name of the Fungal agent	Microscopic characteristics
Figure 1: <i>Aspergillus niger</i>	Stain-lactophenol cotton blue Magnification – ×40 Conidial heads are dark brown to black, radiate with metulae twice as long as the phialides. Conidiophores are smooth-walled. Conidia brown and rough walled
Figure 2: <i>Aspergillus flavus</i>	Stain-lactophenol cotton blue Magnification – ×40 Conidial heads with phialides borne directly on the vesicle. Conidiophores are hyaline and coarsely roughened, often more noticeable near the vesicle
Figure 3: <i>Aspergillus terreus</i>	Stain-lactophenol cotton blue Magnification – ×40 Conidial heads are compact, columnar and biseriate. Conidiophores are hyaline and smooth-walled. Conidia are globose to ellipsoidal hyaline to slightly yellow and smooth-walled
Figure 4: <i>Aspergillus fumigatus</i>	Stain-lactophenol cotton blue Magnification – ×40 Columnar, uniseriate conidial heads. Conidiophores are smooth-walled and conical shaped terminal vesicles, which support a single row of phialides on the upper two-thirds of the vesicle

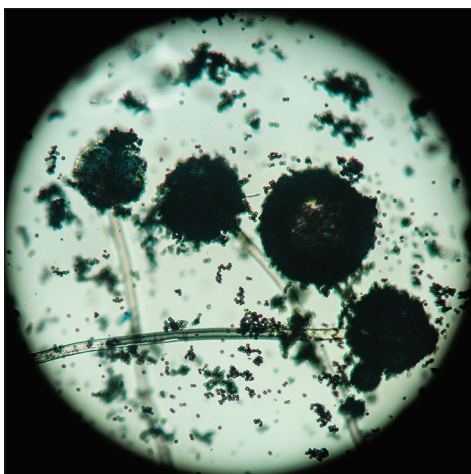


Figure 1: *Aspergillus niger*



Figure 2: *Aspergillus flavus*

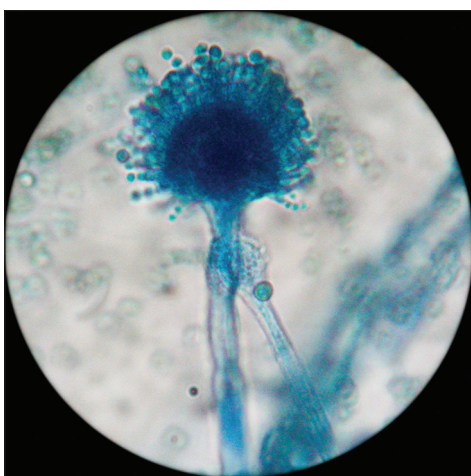


Figure 3: *Aspergillus terreus*

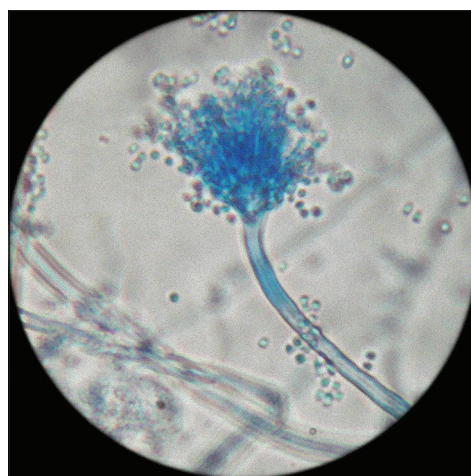


Figure 4: *Aspergillus fumigatus*

Among the women with onychomycosis, 65% and 35% cases were due to *Aspergillus* species and other fungal species, respectively, whereas in men 82% of onychomycosis was caused by *Aspergillus* species. Infection with *Aspergillus* species was found to correlate significantly with the male gender ($P = 0.004$).

Of the patients having *Aspergillus* onychomycosis, 149 (83%) were in the >50 age group. The occurrence of *Aspergillus* species in toenail infections was statistically significant with the increasing age ($P = 0.014$) and with the duration of diabetes ($P < 0.05$). Among patients who had *Aspergillus* nail infection, 66 (37%) had diabetes for a period of <15 years, and 114 (63%) had diabetes for a period of >15 years. There was no statistical significance with the occurrence of *Aspergillus* species in toenails with the family history of onychomycosis.

With regard to occupation, 162 (63%) patients were engaged in agricultural activities, including farming and gardening. Among these 77% were confirmed to have infected nails

due to *Aspergillus* species, ($P = 0.006$). The majority of patients ($n = 180$ [71%]) were using unchlorinated water supplies for daily bathing and washing. Among these 76% were confirmed to have *Aspergillus* species ($P = 0.003$).

Sixty (20%) of the clinically suspected patients were working in offices, wearing socks and shoes. Among them, 65% were confirmed to have onychomycosis due to *Aspergillus* species, and all of them had previous fungal infections as well. Hard and brittle nails were the two common clinical signs observed in patients with onychomycosis due to *Aspergillus* species [Figure 5].

Among study population, only 36% of patients assumed they had an infection in their toenails. However, when the clinical toe examination was performed followed by the laboratory confirmation 85% (255/300) were found to be suffering from fungal toenail infection.

It is evident that the actual frequency of toenail infections was underestimated by the patients. Furthermore, it is

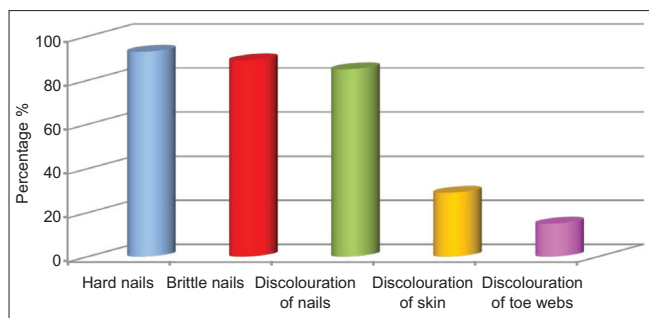


Figure 5: Characteristics of nails of patients confirmed to have *Aspergillus* onychomycosis

clearly evident that the patients' awareness about the pathogen which causes nail infection was very low among study population [Figure 6].

DISCUSSION

Although it is reported that dermatophytes and yeasts are the most common cause for onychomycosis,^[6,8] nondermatophyte molds (NDM) such as *Aspergillus* spp., *Fusarium* spp., *Acremonium* spp., and *Scopulariopsis* spp., were also found as the most common pathogens for onychomycosis in patients with diabetes.^[2,5,13]

In our study, *A. niger* was found to be the most common (76%) cause for onychomycosis among the diabetes patients. In recent past, more than 50% of nail abnormalities are due to onychomycosis.^[1] We report that 85% of diabetic patients had toenail infections, which is a significant finding when compared to the reported prevalence rates of 30–60%.^[4,14] Our results were also in line with previous investigations^[15,16] reporting that *A. niger* as the commonest cause of nail infection in diabetics.

Studies based on epidemiology have stated that *Aspergillus* species are emerging fungal agents of toenail onychomycosis.^[9,10] Several other studies also have reported *Aspergillus* species as a primary cause of onychomycosis.^[7,8]

Our findings of *Aspergillus* species as the true pathogen is consolidated as all the specimens which were positive for *Aspergillus* species were confirmed by both direct smear and culture positive results.

In contrast to our study, Gupta and Humke, Moreno and Arenas, have reported that *Trichophyton* spp., *Microsporium* spp. and *Epidermophyton* spp. were more common pathogens causing nail infections among diabetes patients.^[6,8]

Even though the majority of the study population who were clinically suspected to have onychomycosis were females, the percentage of culture positive for *Aspergillus* species

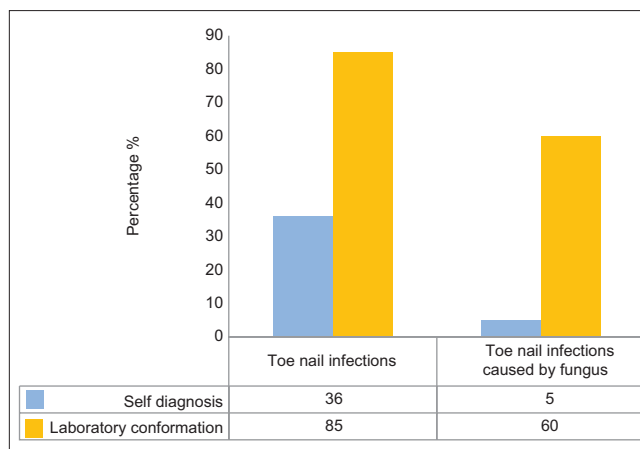


Figure 6: Response of volunteers regarding self-diagnosis of onychomycosis and comparison with laboratory-based mycological confirmation

was higher in males and showed statistical significance. A global study by Sigurgeirsson and Baran in 2014 had further supported our finding.^[17] Fata *et al.*, reported that gender-related factors such as differences in lifestyle, professional activities, and sports activities can affect the nail structure of the foot.^[18]

The occurrence of *Aspergillus* species in toenails was found to be statistically significant with the advancing age of the diabetic patients. Diabetic patients more than 50 years old are more susceptible to fungal infections in toenails due to diminished blood circulation, increased thickness of the nail plate, decreased the growth rate of the nail, and poor foot hygiene.^[19]

Previous reports indicate that prolonged duration of diabetes mellitus, prolonged exposure to fungi and old age can predispose patients to onychomycosis because these patients provide a favorable environment for the growth of *Aspergillus* species. Therefore, early recognition and intervention is advisable because of the progressive nature of the infection.

In our study group having onychomycosis due to *Aspergillus* species, 93% were diagnosed with hard nails (pachyonychia), 89% with brittle nails and 85% had discolored nails. The presence of discolored skin on the feet and discolored toe webs were comparatively low than the nail deformities. This is mainly because *Aspergillus* species do not spread to the surrounding skin like other fungal species that cause nail infections.^[20] *Aspergillus* onychomycosis starts at the tip of the underside of the nail, where spores get accumulated, and the infection spreads toward the cuticle and the nails become thick, discolored, and flaky.^[19]

Certain factors such as barefoot walking, using open rubber slippers, low socioeconomic status, late presentation by

patients, poor compliance with medical care, inadequate adherence to precautionary measures, and foot inspection contribute to this high prevalence of onychomycosis among diabetic population. *Aspergillus* species are a large group of common saprophytic molds which are often isolated from soil, air, and plant materials. Prolonged exposure to soil, mud, and water contaminated with fungi will increase the susceptibility of *Aspergillus* infection in toenails. In our study, more than half of the population was manual laborers working as farmers and gardeners' in close contact with soil, mud, and water. The occurrence of *Aspergillus* infection was statistically significant with agricultural workers.

Interestingly, in our study population, only 20% were office workers, among them more than half were diagnosed with *Aspergillus* onychomycosis. Accumulation of sweat within a shoe: Especially when wearing socks, can generate a moist warm environment, that is, ideal for fungal growth. In 2010, Thomas *et al.* had reported an association between onychomycosis and the use of footwear.^[21] Increased use of occlusive footwear that hinder ventilation and do not absorb perspiration may also contribute to higher incidence of onychomycosis in males.^[18,22,23]

Aspergillus is normally considered as a common contaminant. Therefore, it is difficult to discern between the contaminant and the pathogen when *Aspergillus* spp. are identified in onychomycosis. However, according to English, in 1976, NDM can be considered as a pathogen of onychomycosis only when hyphae or spores are seen on direct microscopic examination, and the same strain is identified through cultures.^[24] In our study, all the nail specimens which were confirmed to have *Aspergillus* showed positive direct smear as well as gave a comparable culture result.

Onychomycosis in people with diabetes increases the risk for other foot disorders and trigger for more severe complications such as foot ulcers, gangrene,^[2] recurrent cellulitis, and limb amputation.^[4]

The final outcome from not treating this condition can be worse in diabetics than in those without diabetes. Therefore, care should be taken for the accurate diagnosis and timely treatment of toenail onychomycosis to prevent complications.

CONCLUSION

A. niger was the most common pathogen isolated from toenail infection in this study conducted among diabetic population in Sri Lanka. Risk factors associated with

Aspergillus onychomycosis were age, gender, duration of diabetes, length of exposure to fungi, and occupation.

Acknowledgment

We would like to thank all the technical officers at the Department of Microbiology, University of Sri Jayewardenepura and the nursing staff at the Diabetic Clinic at Colombo South Teaching Tertiary Care Hospital, for their assistance.

Financial support and sponsorship

Nil.

Conflicts of interest

There are no conflicts of interest.

REFERENCES

1. Leelavathi M, Noorlaily M. Onychomycosis nailed. *Malays Fam Physician* 2014;9:2-7.
2. Papini M, Cicoletti M, Fabrizi V, Landucci P. Skin and nail mycoses in patients with diabetic foot. *G Ital Dermatol Venereol* 2013;148:603-8.
3. Mayser P, Freund V, Budihardja D. Toenail onychomycosis in diabetic patients: Issues and management. *Am J Clin Dermatol* 2009;10:211-20.
4. Cathcart S, Cantrell W, Elewski BE. Onychomycosis and diabetes. *J Eur Acad Dermatol Venereol* 2009;23:1119-22.
5. Wijesuriya TM, Weerasekera MM, Kottahachchi J, Ranasinghe KN, Dissanayake MS, Prathapan S, *et al.* Proportion of lower limb fungal foot infections in patients with type 2 diabetes at a tertiary care hospital in Sri Lanka. *Indian J Endocrinol Metab* 2014;18:63-9.
6. Gupta AK, Humke S. The prevalence and management of onychomycosis in diabetic patients. *Eur J Dermatol* 2000;10:379-84.
7. Gupta AK, Drummond-Main C, Cooper EA, Brintnell W, Piraccini BM, Tosti A. Systematic review of nondermatophyte mold onychomycosis: Diagnosis, clinical types, epidemiology, and treatment. *J Am Acad Dermatol* 2012;66:494-502.
8. Moreno G, Arenas R. Other fungi causing onychomycosis. *Clin Dermatol* 2010;28:160-3.
9. Gianni C, Romano C. Clinical and histological aspects of toenail onychomycosis caused by *Aspergillus* spp.: 34 cases treated with weekly intermittent terbinafine. *Dermatology* 2004;209:104-10.
10. Hilmioglu-Polat S, Metin DY, Inci R, Dereli T, Kilinç I, Tümbay E. Non-dermatophytic molds as agents of onychomycosis in Izmir, Turkey – A prospective study. *Mycopathologia* 2005;160:125-8.
11. Veer P, Patwardhan NS, Damle AS. Study of onychomycosis: Prevailing fungi and pattern of infection. *Indian J Med Microbiol* 2007;25:53-6.
12. Bassiri-Jahromi S, Khaksar AA. Nondermatophytic moulds as a causative agent of onychomycosis in tehran. *Indian J Dermatol* 2010;55:140-3.
13. Farwa U, Abbasi SA, Mirza IA, Amjad A, Ikram A, Malik N, *et al.* Non-dermatophyte moulds as pathogens of onychomycosis. *J Coll Physicians Surg Pak* 2011;21:597-600.
14. Nasreen S, Ahmed I, Jahangir MU. Cutaneous manifestations of diabetic foot. *J Pak Assoc Dermatologists* 2009;19:13-7.
15. Nair S, Peter S, Sasidharan A, Sistla S, Unni AK. Incidence of mycotic infections in diabetic foot tissue. *J Cult Collect* 2006-2007;5:85-9.
16. Eckhard M, Lengler A, Liersch J, Bretzel RG, Mayser P. Fungal foot infections in patients with diabetes mellitus – Results of two independent investigations. *Mycoses* 2007;50 Suppl 2:14-9.

17. Sigurgeirsson B, Baran R. The prevalence of onychomycosis in the global population: A literature study. *J Eur Acad Dermatol Venereol* 2014;28:1480-91.
18. Fata S, Saeed-Modaghegh MH, Faizi R, Najafzadeh MJ, Afzalagheh M, Ghasemi M. Mycotic infections in diabetic foot ulcers in Emam Reza hospital, Mashhad, 2006-2008. *Jundishapur J Microbiol* 2011;4:11-6.
19. Zaias N, Escovar SX, Rebell G. Opportunistic toenail onychomycosis. The fungal colonization of an available nail unit space by non-dermatophytes is produced by the trauma of the closed shoe by an asymmetric gait or other trauma. A plausible theory. *J Eur Acad Dermatol Venereol* 2014;28:1002-6.
20. Banu A, Anand M, Eswari L. A rare case of onychomycosis in all 10 fingers of an immunocompetent patient. *Indian Dermatol Online J* 2013;4:302-4.
21. Thomas J, Jacobson GA, Narkowicz CK, Peterson GM, Burnet H, Sharpe C. Toenail onychomycosis: An important global disease burden. *J Clin Pharm Ther* 2010;35:497-519.
22. Araujo AJ, Bastos OM, Souza MA, Oliveira JC. Occurrence of onychomycosis among patients attended in dermatology offices in the city of Rio de Janeiro, Brazil. *An Bras Dermatol* 2003;78:299-308.
23. Kafaie P, Noorbala MT. Evaluation of onychomycosis among diabetic patients of Yazd diabetic center. *J Pak Assoc Dermatologists* 2010;20:217-21.
24. English MP. Nails and fungi. *Br J Dermatol* 1976;94:697-701.