

How to approach phyllodes tumors of the breast?

Turan Acar¹, Ercüment Tarcan¹, Mehmet Hacıyanlı¹, Erdinç Kamer¹, Mustafa Peşkersoy¹, Seyran Yiğit², Özlem Gür¹, Necat Cin¹, Ayşegül Akder Sarı², Fatma Tatar¹

ÖZ

Objective: Phyllodes tumor of the breast is a rare fibroepithelial breast tumor that comprise 0.3-0.9% of primary breast neoplasms. In this study, we aimed to present clinicopathologic symptoms of our patients along with their treatment modality.

Material and Methods: Clinicopathologic properties and treatment modality of 20 phyllodes tumor patients who underwent surgery between January 2008 and January 2013 were retrospectively evaluated.

Results: Median patient age was 47 years (22-75). Fine-needle aspiration biopsy was applied to 19 patients. Biopsy results were reported as suspicious in four, malignant in three, benign in 11, and as non-diagnostic in one patient. Final histopathology reports revealed two benign, one malignant and one borderline tumor out of the four patients with suspicious findings on fine needle aspiration biopsy; all patients with malignant cytology had malignancy. There were two borderline and nine benign lesions within the benign biopsy group. Sixteen patients underwent segmental mastectomy, four patients underwent mastectomy with/without axillary dissection. The median tumor size was 6 (1-13) cm. Histopathologically, 11 (55%) tumors were benign, 5 (25%) were borderline, and 4 (20%) were malignant. Two of the four patients with malignancy underwent radiotherapy and chemotherapy, and one patient only received chemotherapy as adjuvant treatment.

Conclusion: Phyllodes tumors are rare, mix-type breast tumors. Due to high rates of local recurrence and potential for malignancy, preoperative diagnosis and accurate management are important.

Keywords: Phyllodes tumor, breast cancer, mastectomy

INTRODUCTION

Phyllodes tumors are rare fibroepithelial lesions that comprise 2-3% of all fibroepithelial tumors, and 0.3-0.5% of all breast tumors in women. It can be detected at any age, but they are relatively rare in adolescents and the elderly. The peak age for this tumor is around 45-49 years. Its incidence is very low with a rate of approximately 2.1/1,000,000 (1-3).

Phyllodes tumors have been first defined as a giant type of fibroadenoma in 1774 (4). They are differentiated from fibroadenomas histologically by increased cellularity, and clinically by local recurrence and metastatic spread. In 1838, Johannes Müller (4) defined this tumor as "cystosarcoma phyllodes". It was believed to be a benign lesion until Cooper and Ackerman stated that biologically there is a malignancy potential in these tumors in 1943. In 1981, the World Health Organization (WHO) adopted the phyllodes tumor terminology and it was classified as benign, borderline and malignant by Rosen based on histologic tumor characteristics (tumor margins, stromal overgrowth, tumor necrosis, cellular atypia, mitotic count) (5, 6). Approximately 35-64% of these tumors are benign and 25% are malignant (7). Surgery is the mainstay of treatment for phyllodes tumors. Preoperative diagnosis is very important for accurate surgical planning. In this article, we presented clinicopathologic symptoms of our patients with a diagnosis of phyllodes tumor along with their treatment modality.

MATERIAL AND METHODS

Demographic, clinicopathologic properties and the treatment modality of 20 patients with phyllodes tumors who underwent surgery at İzmir Katip Çelebi University Atatürk Training and Research Hospital General Surgery Clinics between January 2008 and January 2013 were retrospectively evaluated. An approval was obtained from the İzmir Katip Çelebi University Atatürk Education and Research Hospital Ethics Committee (Decision No. 168; Date: 02.08.2013).

Diagnosis

Patients were diagnosed by radiologic and pathologic evaluations. Ultrasound (USG) and mammography (MMG) were used as the primary imaging methods. Fine needle aspiration biopsy (FNAB) was used for pathologic diagnosis.

¹Clinic of General Surgery, İzmir Katip Çelebi University Atatürk Training and Research Hospital, İzmir, Turkey

²Clinic of Pathology, İzmir Katip Çelebi University Atatürk Training and Research Hospital, İzmir, Turkey

Address for Correspondence

Turan Acar

e-mail:

drturancar1982@gmail.com

Received: 03.10.2014

Accepted: 24.11.2014

Available Online Date: 24.06.2015

©Copyright 2015

by Turkish Surgical Association

Available online at

www.uluscerrahidergisi.org

Surgical Treatment

Wide local excision, breast-conserving surgery (BCS), mastectomy or modified radical mastectomy (MRM) were performed according to the tumor location, size and histopathologic diagnosis.

Pathologic Evaluation

Phyllodes tumor types were pathologically classified as benign, borderline and malignant according to the following standard criteria:

- a) Benign: 0-4 mitosis / 10x magnification area, minimal stromal hypercellularity and atypia, minimal or moderate stromal overgrowth, and negative surgical margins.
- b) Borderline: 5-9 mitosis / 10x magnification area, moderate stromal hypercellularity, atypia and stromal overgrowth, negative or permeative surgical margins.
- c) Malignant: >10 mitosis / 10x magnification area, moderate or marked stromal hypercellularity, atypia and stromal overgrowth, permeative surgical margins.

Adjuvant Therapy

All patients were discussed at the İzmir Katip Çelebi University Atatürk Training and Research Hospital multidisciplinary oncology meetings, and it was decided if the patients would receive additional adjuvant treatment. Patients with malignant phyllodes who underwent BCS received radiotherapy to the breast and the tumor bed, patients with a high mitotic index who were considered to have very aggressive tumors received radiotherapy to the chest wall and some of these patients were given additional chemotherapy.

Statistical Analysis

Patient data included the following clinical and pathological characteristics: age at diagnosis, preoperative diagnosis, tumor size, primary surgery, if external beam radiotherapy and / or chemotherapy was implemented or not, presence of local and/or systemic recurrence.

Patients were informed about the disease and procedures, and written consents were obtained. Informed consent was obtained from all patients to perform scientific studies.

RESULTS

The clinical and pathological features and treatment modalities of the patients are shown in Table 1. The median age of patients was 46 (22-75) years. As part of the radiologic examination 19 patients underwent ultrasound and/or MMG, while FNAB was obtained directly in one patient. Magnetic resonance imaging (MRI) was not requested from any patient. In total, FNAB was performed in 19 patients. The FNAB results revealed 4 suspicious cytology, 3 malignant cytology, 11 benign cytology and 1 non-diagnostic sample.

The median tumor size was 6 (1-13) cm. Definitive histopathologic results of patients revealed 2 benign, 1 malignant, and

1 borderline tumor within those with suspicious cytology on FNAB; malignant tumors in all patients with malignant cytology; and 2 borderline and 9 benign tumors within those with benign cytology (Figure 1). The lesions were localized in the upper outer quadrant in 10 patients.

Sixteen patients underwent wide local excision (segmental mastectomy), and four underwent mastectomy (\pm axillary dissection).

On histopathologic examination, 11 tumors (55%) were classified as benign, five (25%) as borderline, and four (20%) as malignant (Figure 2). Two of the four patients with malignant tumors received adjuvant radiotherapy (RT) and chemotherapy (CT) after surgery, and 1 received only chemotherapy. One patient did not receive any adjuvant therapy because of her poor overall condition.

The median follow-up was 46 months (6-82). There was no local recurrence during the follow-up period after surgery, however the patient who had malignant phyllodes but did not receive any adjuvant therapy due to her poor overall condition developed liver metastases and a synchronous tumor (pancreatic cancer) at 12 months, and died. The 5-year overall survival rate was determined as 89% (8/9 patients) for borderline and malignant cases.

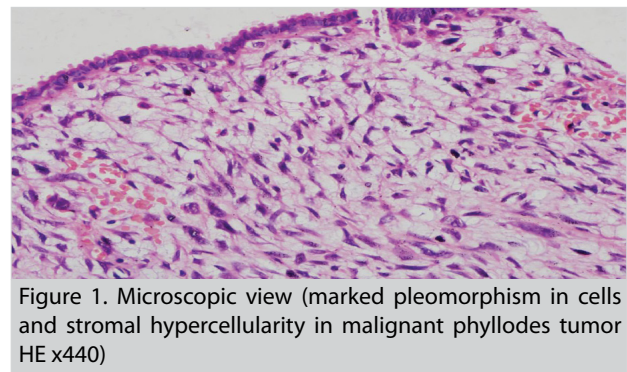


Figure 1. Microscopic view (marked pleomorphism in cells and stromal hypercellularity in malignant phyllodes tumor HE x440)

Table 1. Clinical and pathologic features of patients with phyllodes tumors

Patient feature	n=20	n=11 (Benign)	n=5 (Borderline)	n=4 (Malignant)
Median age	46 (22-75)	43 (22-58)	48 (34-75)	51 (43-57)
FNAB	19			
Procedure type				
Wide local excision	16	11	3	2
Mastectomy (\pm axillary dissection)	4	0	2	2
Median tumor size (cm)	6 (1-13)	5 (1-11)	7 (1.5-13)	6 (1.5-11)
Adjuvant chemotherapy	3	0	0	3
Adjuvant radiotherapy	2	0	0	2

FNAB: Fine needle aspiration biopsy

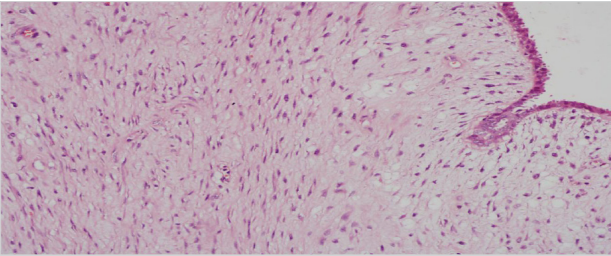


Figure 2. Microscopic view (moderate pleomorphism in stromal cells in a borderline tumor HE x220)

DISCUSSION

Phyllodes tumors are rare fibroepithelial lesions. The peak age for this entity is 45-49 years, but it can be detected at any age from the young to the elderly (1-3). In their study, Parker et al. (7) reported the mean age at diagnosis as 45 years. It is more common in the Latin American and Asian population (8). It is very rare in men, and its presence is usually associated with gynecomastia. In our series, the median age was determined as 46 years, and borderline - malignant phyllodes tumors were detected in older women, similar to the 30 patient-series reported by Atalay et al. (9).

Clinically, they appear as a benign breast mass with rapid growth. In some patients, the lesion may present with a recent sudden growth after being present for many years. They are usually located in the upper outer quadrant, and may rarely be bilateral (10, 11). In our series, the most frequent tumor localization was the upper outer quadrant and none of the patients had bilateral tumors.

Preoperative diagnosis of this rare phenomenon is significant to decide on the proper surgical approach. They appear as hyperdense, large, round/lobular, well-circumscribed lesions on MMG, which is the initial imaging modality of choice (12-15). It was reported that distinguishing these tumors from fibroadenomas was difficult by MMG, since both display similar findings (16, 17). Parallel to these reports, five patients in our series were initially reported as fibroadenoma with ultrasound and/or MMG. Ultrasound and/or MMG was used for imaging in all 20 patients in our series. Recent studies with MRI have reported that there were no significant differences in MRI findings between benign phyllodes tumors and fibroadenomas (18). We did not obtain MRI in any of our patients in the preoperative period.

Phyllodes tumors and fibroadenomas constitute majority of fibroepithelial lesions. Definite diagnosis of phyllodes tumors with FNAB is difficult since they show similar features with fibroadenomas. Gordon et al. (19) followed-up 194 patients with a diagnosis of fibroadenoma on FNAB, and they detected an increase in size during the 6-month follow-up in 20% of cases. Fibroepithelial lesions that contain cellular stroma may be reported as either fibroadenoma or phyllodes tumor in surgically excised specimens. Stromal hypercellularity, stromal cellular atypia, mitotic rate and relative ratio of stroma to the epithelium may help in making a diagnosis. Phyllodes tumors may be histologically distinguished from fibroadenomas generally by the increased stromal cellularity and mitotic

activity. However, since cellular stroma may also be present in juvenile fibroadenomas, the diagnosis may be challenging. Jacobs et al. (20) detected four stromal features (cellularity, nuclear atypia, mitotic rate and relative ratio of stroma to the epithelium) in tru-cut biopsy specimens. These features were detected in phyllodes tumors and were not identified in excised fibroadenomas. Based on these literature findings, most surgeons advocate excisional biopsy for definitive diagnosis, which is not only diagnostic but also therapeutic for benign phyllodes tumors.

The risk of malignancy increases in these tumors with increasing tumor size. In a study by Tan et al. (12), it has been shown that the relative risk of malignancy is 3.87 fold in tumors >3 cm, and that all tumors >8 cm were detected to be malignant on histopathologic evaluation. In our study, the median tumor size was larger in borderline and malignant tumors as compared to benign lesions.

In our study, phyllodes tumors were classified into benign, borderline and malignant tumors according to the WHO classification (5, 6). The classification was made according to the degree of mitosis, surgical margin status, stromal cellularity and atypia (14). One of the signs indicating aggressive behavior is stromal overgrowth, and is defined as the presence of stroma without any epithelial elements on x40 magnification. Suzuki et al. (21) reported that 60% of these tumors were benign, 20% were borderline and 20% were malignant. Several other series also reported that benign phyllodes tumors were detected in about 60% (9, 22). Consistent with the literature in our study, the tumors were detected to be benign in 55%, borderline in 25% and malignant in 20% of patients.

The primary treatment modality of phyllodes tumor is surgery regardless of the nature of tumor. Local excision, wide local excision or mastectomy may be implemented. Wide local excision is recommended even for benign tumors due to their local recurrence risk (20%). Local excision is defined as excision with a 5 mm safe surgical margin, while wide local excision defines excision with negative surgical margin of at least 1 cm (23). In borderline or malignant phyllodes tumors diagnosed in the preoperative period, the margin should be at least 1 cm. This can be achieved with wide local excision or mastectomy based on breast size. In benign phyllodes tumors diagnosed after local excision, the wait-and-see method can be used. However, the follow-up of these patients should be regularly carried out. That is why the socio-economic and cultural level of the patient must be taken into consideration. In such an approach, the local recurrence and 5-year survival rates vary between 4% and 96%. In patients with benign phyllodes tumors and positive surgical margins after local excision case, the debate on if additional surgery should be performed or if the patient should be followed-up still continues. However, there is consensus on the requirement for re-excision in case of positive surgical margins in both borderline and malignant phyllodes tumors. Considering breast size, the main approach should be mastectomy in giant phyllodes tumors. In their series on 172 cases, Chen et al. (24) reported 76% benign, 7% borderline and 17% malignant tumors, and while applying

less aggressive surgical treatment in low-grade tumors, they preferred mastectomy in 10% of benign, 67% of borderline and 86% of malignant cases. Local recurrence was found in 15%, and these were all detected in benign cases treated with local/wide local excision. In another study, distant metastasis and survival rates were reported to be similar in patients who underwent BCS or mastectomy, however, the local recurrence rate was significantly higher in patients who underwent BCS (25). In addition to these studies, the Mayo Clinic series reported tumor size, surgical margin <1 cm, and stromal overgrowth as factors that increase local recurrence rate (26).

In our series, 16 patients including all patients with benign tumors (n=11), three with borderline tumors, and two with malignant tumors underwent wide local excision. Four patients with histopathologic borderline and malignant tumors underwent mastectomy (\pm axillary dissection). In order to provide a safe surgical margin and to avoid local recurrence, two patients with borderline tumors that were larger than 10 cm in size underwent mastectomy. As a result, local recurrence was not observed in any patient during follow-up.

Malignant phyllodes tumors often spread by hematogenous route. Lymph node metastases occur in less than 1%, therefore axillary dissection is not routinely recommended (24). In cases with axillary metastasis, axillary dissection may be necessary. Lymph node metastasis was not detected in any of the 42 cases who underwent modified radical mastectomy (MRM) (24). In another series of 15 patients with MRM, lymph node metastases was found in only three patients (20%) (21). In our series, two patients with suspicious axillary lymph nodes on MMG underwent axillary dissection, and metastatic lymph nodes were not detected in either.

Distant metastases can be detected in 10% of patients, and 25% of these occur in malignant tumors. Most of these distant metastases occur in the absence of local recurrence. Distant metastases are most common in the lungs (66%), bone (28%), brain (9%) followed by the liver and the heart. The prognosis of metastatic phyllodes tumor is poor. In our series, the patient who had malignant phyllodes tumor but did not receive any adjuvant therapy due to her overall condition, developed liver metastases and a synchronous tumor (pancreatic cancer) at 12 months, and she died.

Although the role of adjuvant radiotherapy (RT) is controversial in this setting, the favorable results reported for sarcomatous lesions are also promising for malignant phyllodes tumors. Chanye et al. (27) stated that the use of adjuvant RT would be useful in the presence of some unfavorable characteristics (large tumor, high nuclear pleomorphism, high mitotic index, absence of necrosis, increased vascularity). In contrast, in the MD Anderson (22) Cancer Center, only patients with positive surgical margins and patients who had local excision and could not be re-operated received RT. Likewise, chemotherapy (CT) (anthracyclines, ifosfamide, cisplatin, etoposide, dacarbazine, doxorubicin) has been used in many studies, with no survival benefit (28). In our series, postoperative adjuvant treatment was applied as RT and chemotherapy in two patients out of the four malignant cases, and one patient re-

ceived chemotherapy alone. One patient with a malignant tumor did not receive any adjuvant therapy because of her poor general condition. The patients who received combined systemic treatment had a high mitotic index, a large tumor size and marked increase in vascularity.

The 5-year overall survival rates in patients with benign and malignant phyllodes tumors in the MD Anderson (22) series was 91% and 82%, respectively; and was 91% in the analysis of SEER data for malignant cases (29). In another study, the 3-year survival of benign/borderline tumors was 100% in 6 patients, while the 3-year survival rate was reported as 53.4% in 13 patients with malignant phyllodes tumor (30). In a study of 15 malignant phyllodes tumors, Suzuki et al. (21) reported the 5-year survival rate after primary surgery as 10%. In our series, in a median of 46 months follow-up, one patient with a diagnosis of malignant phyllodes died due to metastasis and synchronous tumor.

CONCLUSION

Phyllodes tumors are rare mesenchymal and epithelial breast tumors. They may present with various different clinical forms, so they may be confused with other breast diseases that cause breast masses, especially fibroadenoma. Due to their increased local recurrence rate and malignant potential, preoperative diagnosis and diligent management are significant. Early diagnosis and resection prior to the development of distant metastasis are crucial. Nevertheless, due to its rare incidence and lack of specific clinical / imaging properties that may help in diagnosis, the decision to proceed with follow-up or surgery relies on the accumulation of more and detailed information.

In addition to these, a review of the literature reveals that systemic adjuvant therapy reduces local recurrence rate and increases overall survival in patients with high mitotic index, high nuclear pleomorphism, large tumor size and marked increase in vascularity.

Ethics Committee Approval: Ethics committee approval was received for this study from the ethics committee of Izmir Katip Çelebi University Atatürk Training and Research Hospital (Decision number: 168; Date: 02.08.2013).

Informed Consent: Written informed consent was obtained from patients who participated in this study.

Peer-review: Externally peer-reviewed.

Author Contributions: Concept - T.A., E.T., M.H., E.K., M.P., S.Y., Ö.G., N.C., A.A.S., F.T.; Design - T.A., E.T., M.H., E.K., M.P., S.Y., Ö.G., N.C., A.A.S., F.T.; Supervision - T.A., E.T., M.H., E.K., M.P., S.Y., Ö.G., N.C., A.A.S., F.T.; Funding - T.A., E.T.; Materials - T.A., S.Y., A.A.S.; Data Collection and/or Processing - T.A., E.K.; Analysis and/or Interpretation - T.A., E.T., M.H., E.K., M.P., S.Y., Ö.G., N.C., A.A.S., F.T.; Literature Review - T.A., E.T., M.H., E.K., M.P., S.Y., Ö.G., N.C., A.A.S., F.T.; Writer - T.A.; Critical Review - M.H., M.P.

Conflict of Interest: No conflict of interest was declared by the authors.

Financial Disclosure: The authors declared that this study has received no financial support.

REFERENCES

1. Rowell MD, Perry RR, Hsiu JG, Barranco SC. Phyllodes tumors. *Am J Surg* 1993; 165: 376-379. [\[CrossRef\]](#)
2. Salvadori B, Cusumano F, Del Bo R, Delledonne V, Grassi M, Rovini D, et al. Surgical treatment of phyllodes tumors of the breast. *Cancer* 1989; 63: 2532-2536. [\[CrossRef\]](#)
3. Bernstein L, Deapen D, Ross RK. The descriptive epidemiology of malignant cystosarcoma phyllodes tumors of the breast. *Cancer* 1993; 71: 3020-3024. [\[CrossRef\]](#)
4. Müller J. Über den feineren Bau und die Formen der Krankhaften Geschwulste. Berlin: G Reiner 1838; 1: 54-57.
5. World Health Organization, Histologic Typing of Breast Tumors, WHO, Geneva, Switzerland, 2nd edition, 1981.
6. Rosen PP. Rosen's Breast Pathology, Lippincott William Wilkins, New York, NY, USA, 2nd edition, 2001.
7. Parker SJ, Harries SA. Phyllodes tumours. *Postgrad Med J* 2001; 77: 428-435. [\[CrossRef\]](#)
8. Noguchi S, Motomura K, Inaji H, Imaoka S, Koyama H. Clonal analysis of fibroadenoma and phyllodes tumor of the breast. *Cancer Res* 1993; 53: 4071-4074.
9. Atalay C, Kınaş V, Çelebioğlu S. Analysis of patients with phylloides tumor of the breast. *Ulus Cerrahi Derg* 2014; 30: 129-132. [\[CrossRef\]](#)
10. Reinfuss M, Mituš J, Duda K, Stelmach A, Rys J, Smolak K. The treatment and prognosis of patients with phyllodes tumor of the breast: an analysis of 170 cases. *Cancer* 1996; 77: 910-916. [\[CrossRef\]](#)
11. Chua CL, Thomas A, Ng BK. Cystosarcoma phyllodes: a review of surgical options. *Surgery* 1989; 105: 141-147.
12. Tan H, Zhang S, Liu H, Peng W, Li R, Gu Y, et al. Imaging findings in phyllodes tumors of the breast. *Eur J Radiol* 2012; 81: 62-69. [\[CrossRef\]](#)
13. Harvey JA. Unusual breast cancers: useful clues to expanding the differential diagnosis. *Radiology* 2007; 242: 683-694. [\[CrossRef\]](#)
14. Liberman L, Bonaccio E, Hamele-Bena D, Abramson AF, Cohen MA, Dershaw DD. Benign and malignant phyllodes tumors: mammographic and sonographic findings. *Radiology* 1996; 198: 121-124. [\[CrossRef\]](#)
15. Foxcroft LM, Evans EB, Porter AJ. Difficulties in the pre-operative diagnosis of phyllodes tumours of the breast: A study of 84 cases. *Breast* 2007; 16: 27-37. [\[CrossRef\]](#)
16. Cosmacini P, Zurrada S, Veronesi P, Bartoli C, Coopmans de Yoldi GF. Phyllodes tumor of the breast: Mammographic experience in 99 cases. *Eur J Radiol* 1992; 15: 11-14. [\[CrossRef\]](#)
17. Buchberger W, Strasser K, Heim K, Müller E, Schröcksnadel H. Phyllodes tumor: Findings on mammography, sonography and aspiration cytology in 10 cases. *AJR Am J Roentgenol* 1991; 157: 715-719. [\[CrossRef\]](#)
18. Wurdinger S, Herzog AB, Fischer DR, Marx C, Raabe G, Schneider A, et al. Differentiation of phyllodes breast tumors from fibroadenomas on MRI. *AJR* 2005; 185: 1317-1321. [\[CrossRef\]](#)
19. Gordon PB, Gagnon FA, Lanzkowsky L. Solid breast masses diagnosed as fibroadenoma at fine-needle aspiration biopsy: acceptable rates of growth at long-term follow-up. *Radiology* 2003; 229: 233-238. [\[CrossRef\]](#)
20. Jacobs TW, Chen YY, Guinee DG Jr, Holden JA, Cha I, Bauermeister DE, et al. Fibroepithelial lesions with cellular stroma on breast core needle biopsy: are there predictors of outcome on surgical excision? *Am J Clin Pathol* 2005; 124: 342-354. [\[CrossRef\]](#)
21. Suzuki-Uematsu S, Shiraishi K, Ito T, Adachi N, Inage Y, Taeda Y, et al. Malignant phyllodes tumor composed almost exclusively of a fibrosarcomatous component: a case report and review of malignant phyllodes tumors with metastases. *Breast Cancer* 2010; 17: 218-224. [\[CrossRef\]](#)
22. Chen AM, Meric-Bernstam F, Hunt KK, Thames HD, Oswald MJ, Outlaw ED, et al. Breast conservation after neoadjuvant chemotherapy: the MD Anderson cancer center experience. *J Clin Oncol* 2004; 22: 2303-2312. [\[CrossRef\]](#)
23. Adamietz BR, Kahmann L, Fasching PA, Schulz-Wendtland R, Uder M, Beckmann MW, et al. Differentiation between phyllodes tumor and fibroadenoma using real-time elastography. *Ultraschall Med* 2011; 32: 75-79. [\[CrossRef\]](#)
24. Chen WH, Cheng SP, Tzen CY, Yang TL, Jeng KS, Liu CL, et al. Surgical treatment of phyllodes tumors of the breast: retrospective review of 172 cases. *J Surg Oncol* 2005; 91: 185-194. [\[CrossRef\]](#)
25. Cohn-Cedermark G, Rutqvist LE, Rosendahl I, Silfversvärd C. Prognostic factors in cystosarcoma phyllodes. A clinicopathologic study of 77 patients. *Cancer* 1991; 68: 2017-2022. [\[CrossRef\]](#)
26. Asoglu O, Ugurlu MM, Blanchard K, Grant CS, Reynolds C, Cha SS, et al. Risk factors for recurrence and death after primary surgical treatment of malignant phyllodes tumors. *Ann Surg Oncol* 2004; 11: 1011-1017. [\[CrossRef\]](#)
27. Chaney AW, Pollack A, McNeese MD, Zagars GK. Adjuvant radiotherapy for phyllodes tumor of breast. *Radiat Oncol Investig* 1998; 6: 264-267. [\[CrossRef\]](#)
28. Morales-Vásquez F, Gonzalez-Angulo AM, Broglio K, Lopez-Basave HN, Gallardo D, Hortobagyi GN, et al. Adjuvant chemotherapy with doxorubicine and dacarbazine has no effect in recurrence-free survival of malignant phyllodes tumors of the breast. *Breast J* 2007; 13: 551-556. [\[CrossRef\]](#)
29. Macdonald OK, Lee CM, Tward JD, Chappel CD, Gaffney DK. Malignant phyllodes tumor of the female breast. *Cancer* 2006; 107: 2127-2133. [\[CrossRef\]](#)
30. Confavreux C, Lurkin A, Mitton N, Blondet R, Saba C, Ranchère D, et al. Sarcomas and malignant phyllodes tumours of the breast—a retrospective study. *Eur J Cancer* 2006; 42: 2715-2721. [\[CrossRef\]](#)