

IMAGES AND VIDEOS

Non-valvular left ventricular papillary fibroelastoma in a patient with recurrent stroke

Baskar Sekar MBBS MRCP, Hunaid Vohra MBBS MRCS MD FETCS FRCS (CTh)¹,
Salman Nishtar MBBS MRCP FRCP and Javed Ehtisham MBBChir MA MRCP DPhil

Kettering General Hospital NHS Trust, Kettering, LE3 9QP, UK
¹Glenfield Hospital, University Hospital of Leicester NHS Trust, Leicester, UK

Correspondence
should be addressed
to B Sekar
Email
cardiologist1978@gmail.com

Summary

A 69-year-old gentleman presented with sudden-onset dizziness and diplopia. Clinical examination findings were

suggestive of posterior circulation stroke. He was found to be in atrial flutter on admission, reverting spontaneously to sinus rhythm. Three weeks before admission, he was admitted to a different hospital with anterior circulation

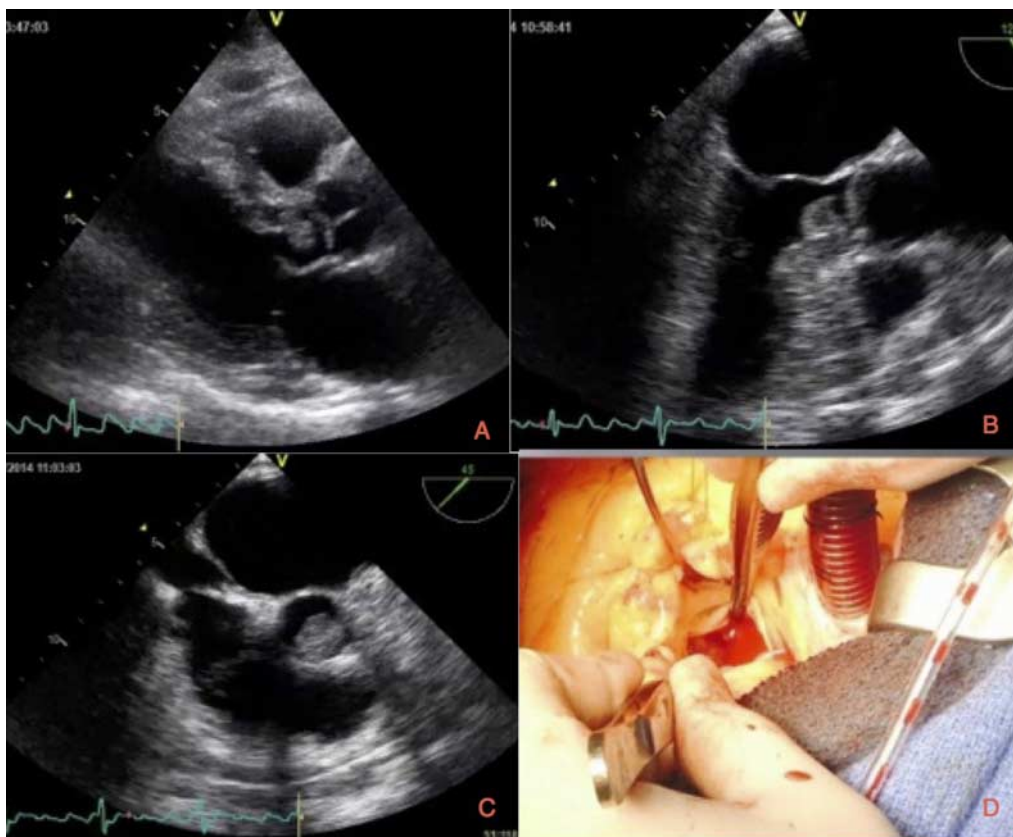


Figure 1

(A) Transthoracic echocardiogram (PLAX view) showing the mass in the LVOT attached to the inter-ventricular septum. (B) Transoesophageal echocardiogram confirming the mass measuring 1.1 × 1.1 cm in the LVOT attached to the inter-ventricular septum. (C) Transoesophageal

echocardiogram showing the mass prolapsing through the aortic valve. (D) Intraoperative picture showing the jelly-like mass attached to the inter-ventricular septum.

stroke, which left him with minor residual weakness. He was found to be in sinus rhythm during that admission and was discharged home on dual-anti platelet therapy. Transthoracic echocardiogram (TTE) performed to exclude a cardiac source of emboli showed a highly mobile echogenic structure in the left ventricular outflow tract (LVOT) attached to the interventricular septum (Fig. 1A and Video 1). Subsequent transoesophageal echocardiogram (TOE) confirmed a highly mobile mass in the LVOT, which appears to be prolapsing through the aortic valve (Fig. 1B, C and Videos 2, 3). The left atrium and appendage are free of spontaneous contrast or thrombus and there are no atherosclerotic plaques noted in the aorta. Given the history of recurrent stroke, the highly mobile nature of the mass and its position in the LVOT, the patient was referred for urgent surgery. The patient underwent complete surgical excision of the mass (Fig. 1D), which was then confirmed to be benign papillary fibroelastoma (PFE) on histopathology. PFE is the second most common cardiac tumour which usually originate from the valvular endothelium. PFE arising from this non-valvular location is exceptionally rare. When present in such a location, they are often mistaken for myxoma from TTE and usually warrants further imaging such as TOE or cardiac MRI to confirm diagnosis. Surgery is curative in most cases and prompt referral should be considered (1).

Video 1

Transthoracic echocardiogram (PLAX view) showing a highly mobile mass in the LVOT attached to the interventricular septum. Download Video 1 via <http://dx.doi.org/10.1530/ERP-14-0080-v1>.

Video 2

Transoesophageal echocardiogram showing a highly mobile mass in the LVOT which appears to prolapsing through the aortic valve. Download Video 2 via <http://dx.doi.org/10.1530/ERP-14-0080-v2>.

Video 3

Transoesophageal echocardiogram showing a highly mobile mass in the LVOT which appears to prolapsing through the aortic valve. Download Video 3 via <http://dx.doi.org/10.1530/ERP-14-0080-v3>.

Patient consent

Written informed consent has been obtained from the patient.

Author contribution statement

B Sekar was responsible for managing the patient along with cardiologist in-charge and helped in manuscript preparation. H Vohra performed the surgery and helped in manuscript preparation. S Nishtar performed the TOE and helped in manuscript preparation. J Ehtisham is the cardiologist in-charge of the patient and critically revised the paper.

Reference

- 1 Bossert T, Gummert JF, Battellini R, Richter M, Barten M, Walther T, Falk V & Mohr FW 2005 Surgical experience with 77 primary cardiac tumors. *Interactive Cardiovascular and Thoracic Surgery* **4** 311–315. (doi:10.1510/icvts.2004.103044)

Received in final form 7 January 2015

Accepted 15 January 2015