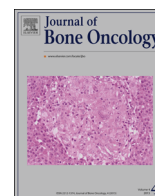



ELSEVIER

Contents lists available at ScienceDirect

Journal of Bone Oncology

journal homepage: www.elsevier.com/locate/jbo

Research Paper

Incidence of distal bone metastases in patients treated for palliative radiotherapy and associations with primary tumour types

Mark Barnes^a, Manpreet S. Tiwana^{a,b}, Andrew Kiraly^b, Mitch Hutchison^a, Robert A. Olson^{a,b,c,*}^a BC Cancer Agency-Centre for the North, 1215 Lethbridge Street, Prince George, BC, Canada V2M7E9^b University of Northern BC 333 University way, Prince George, BC, Canada V2N4Z9^c University of British Columbia Radiation Oncologist, BC Cancer Agency-Centre for the North, 1215 Lethbridge Street, Prince George, BC, Canada V2M7E9

ARTICLE INFO

Article history:

Received 6 May 2015

Received in revised form

4 October 2015

Accepted 16 October 2015

Available online 29 October 2015

Keywords:

Bone metastases

Palliative radiotherapy

Single fraction

Multiple fractions

ABSTRACT

Purpose: This study assesses the incidence of distal bone metastases in palliative radiotherapy (RT) patients.

Material and methods: All courses of RT for bone metastases from 2007–2011 for patient living in British Columbia (BC) were identified in a provincial RT programme. Treated bone metastases (BoM) were categorized as distal if the BoM was located within or distal to the elbow or knee. Patients were grouped by primary tumour site as breast, lung, prostate gastrointestinal, haematological, melanoma, and other. The incidence of distal bone metastases and associations with primary tumour types were determined.

Results: From 2007 to 2011, 8008 patients were treated with 16,277 courses of RT, of which 425 (3%) were courses of RT for distal BoM. The incidence of distal BoM in decreasing order by primary tumour type was melanoma (5%), haematological (3%), lung (2%), other (2%), prostate (2%), breast (1%) and gastrointestinal (1%). Distal BoM were more commonly identified in the lower extremity (87%, $p < 0.001$). Single fraction RT was used more commonly for distal vs non-distal BoM (66% vs. 49%; $p < 0.001$).

Conclusion: The incidence of distal BoM among patients treated with palliative RT was 3% and most commonly identified in patients with melanoma and haematological malignancies.

© 2015 The Authors. Published by Elsevier GmbH. This is an open access article under the CC BY-NC-ND license (<http://creativecommons.org/licenses/by-nc-nd/4.0/>).

1. Introduction

Metastasis to the bone is a common complication of breast, lung, prostate, gastrointestinal, haematological, melanoma, and other tumours [1–3]. In many patients with primary breast, prostate and lung primary tumours, bone metastases (BoM) are signs associated with the presence of disseminated disease [4]. These metastases to the bone will usually result in patients experiencing pain which is often palliated using single fraction radiotherapy (SFRT) or multiple fraction radiotherapy (MFRT) depending on the factors such as cancer type and presence of complication within the bone [5–8]. Although the distribution of BoM

have been observed in many skeletal locations, BoM that are distal to the elbow and knee joints are considered rare and therefore are infrequently reported [9].

Depending on the primary tumour histopathology, the frequency of skeletal bone metastases ranges from 10% to close to 90% and bone lesions are found more commonly within the axial skeletal versus the appendicular skeleton [10]. Although any skeletal bone may be involved with metastatic disease, the vertebral body is most commonly associated with metastatic disease; long bone involvement or metastases distal to the elbow and knee are rare [11–13]. This study sought to assess the incidence of distal bone metastases treated with radiotherapy in a provincial programme.

2. Material and methods

All courses of RT for bone metastases from 2007 to 2011 for patients living in BC were identified in a provincial RT programme. The BC Cancer Agency (BCCA) Information System (CAIS) was used to identify 8008 patients who received 16,277 palliative

* Corresponding author at: University of British Columbia Radiation Oncologist, BC Cancer Agency-Centre for the North, 1215 Lethbridge Street, Prince George, BC, Canada V2M7E9. Fax: 250 645 7361.

E-mail addresses: Mark.barnes@alumni.unbc.ca (M. Barnes),

Manpreet.Tiwana@bccancer.bc.ca (M.S. Tiwana),

andrewkiraly@gmail.com (A. Kiraly),

mitchel.hutchison@alumni.unbc.ca (M. Hutchison),

rolson2@bccancer.bc.ca (R.A. Olson).

radiotherapy courses for bone metastases from 2007 to 2011. Information retrospectively collected on these patients included: patient age, gender, primary tumour histology, fractionation schedules, and location of bone metastases.

Treated BoM were categorized as distal if the BoM was located within or distal to the elbow or knee. Patients were grouped by primary tumour site as breast, lung, prostate gastrointestinal, haematological, melanoma, and other. The incidence of distal bone metastases and associations with primary tumour types were determined.

Multivariable linear regression analysis was used to determine associations between primary tumour type and incidence of distal bone metastases. *P* values were two-sided, and values less than .05 were considered statistically significant. We used the SPSS statistical software package, version 19.0 (Chicago, IL), for data entry and statistical analysis. This study was approved by the combined BCCA and UBC Research Ethics Board.

3. Results

From 2007 to 2011, 8008 patients in BC were treated with 16,277 palliative radiotherapy courses; 425 (3%) of the courses prescribed were used to treat bones located within or distal to the elbow or knee. Male patients were treated more often than female patients (52%) and SFRT was prescribed 49% of the time (Table 1). Breast and lung malignancies were observed most commonly (23%), followed by prostate (19%), other (15%), lymphoma (11%), gastrointestinal (8%) and melanoma (1%) (Table 1). We demonstrated that Melanoma malignancies resulted in the highest frequency (5%) of distal BoM; followed by haematological (3%), lung (2%) prostate (2%), other (2%), gastrointestinal (1%), and breast (1%). Distal BoM were more commonly identified in the lower extremity (87%, $p < 0.001$).

Distal BoM were treated with SFRT significantly more often than non-distal BoM ($p < 0.001$) (Fig. 1).

Table 2 presents the multi-variable analysis performed to determine the associations between distal BoM and patient characteristics, which demonstrated that patients with melanoma have a significant higher odds of having distal bone metastases ($p = 0.004$). The regression analysis also showed significant correlation between having distal bone metastases treated at Abbotsford Centre (odds ratio 2.37, 95% confidence interval 1.54–3.64, $p < 0.0001$) (Table 2).

4. Discussion

This is the first large scale study to illustrate the incidence of distal bone metastases in patients being treated with palliative radiotherapy (RT). From 2007 to 2011, 16,277 courses of palliative

Table 1
Patient characteristics.

Characteristic	Proportion (n=16,277)
Male	52%
Tumour group	
Prostate (n=3103)	19%
Breast (n=3687)	23%
Lung (n=3716)	23%
Lymphoma (n=1860)	11%
Gastrointestinal (n=1277)	8%
Melanoma (n=299)	1%
Other (n=2405)	15%
Distal metastases (n=425)	3%
Single fraction radiotherapy (n=8004)	49%

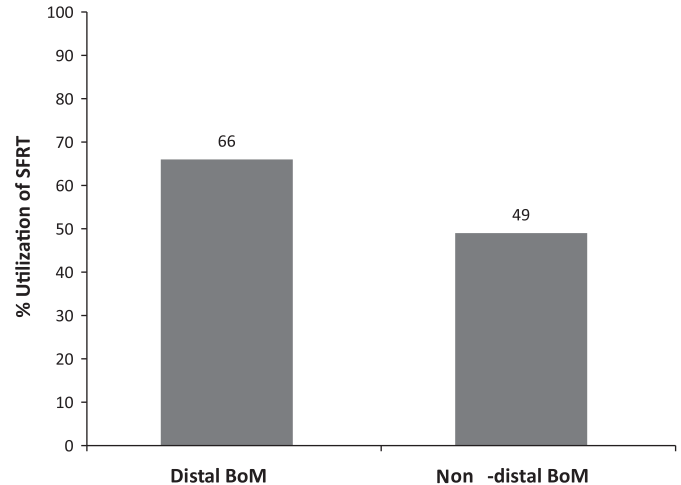


Fig. 1. SFRT utilisation when treating distal and non-distal BoM.

Table 2
Multi-variable linear analysis of distal BoM.

Characteristic	Odds ratio to have distal bone metastases (> 1 favours distal met)	95% confidence interval	<i>p</i> Value
Age	0.99	0.98–1.00	0.07
Male	0.77	0.57–1.05	0.09
Tumour Group			
Prostate	–	–	$p < 0.001$
Breast	0.54	0.32–0.90	0.02
Lung	0.95	0.63–1.44	0.82
Haematological	1.25	0.81–1.93	0.31
Gastrointestinal	0.40	0.19–0.83	0.40
Melanoma	2.76	1.38–5.53	0.004
Other	0.91	0.57–1.44	0.68
BCCA Centre			
Vancouver Centre	–	–	$p < 0.001$
Abbotsford Centre	2.37	1.54–3.64	0.001
Centre for the Southern Interior	0.91	0.65–1.32	$p < 0.001$
Fraser Valley Centre	1.05	0.72–1.51	0.62
Vancouver Island Centre	0.91	0.65–1.26	0.82

RT was used to treat bone metastases in 8008 patients; 425 (3%) of which were RT courses for distal BoM. In addition, distal bone metastases were significantly more likely to be treated with SFRT.

This population-based study demonstrates that patients with melanoma have the highest proportion of distal BoM. This differs from previous reports, which only present that prostate, breast, and lung cancer have the highest absolute number of distal BoM, likely because these are the most common cancers with any type of BoM [9,14–17]. Here we showed that SFRT was used to treat distal BoM more often than non-distal BoM (66% versus 49%, respectively), likely because distal BoM are located in regions that do not contain organs at risk such as the spinal cord [18].

This study should be considered in the context of its strengths and weaknesses. A weakness of this study is that untreated BoM are not captured, and therefore the incidence of distal BoM may be under-represented. However, it is unlikely that the proportion of distal BoM is markedly different than reported. In addition, the large population-based nature of this study provides adequate power to identify correlations between distal BoM and primary tumour type, while being relatively free of selection bias.

Conclusion

This population based study identified an incidence of distal BoM of 3% among patients treated with palliative RT. The incidence of distal BoM was significantly more common with melanoma and haematological malignancies.

Conflict of interest notification

The authors declare that they have no competing interests.

Authors' contributions

MB conceived of the study, participated in the data collection and statistical analysis, and designed and draughted the manuscript. XXX participated in the data collection and statistical analysis. XX and XX participated in the data collection. XXX participated in the acquisition of data, analysis and interpretation of data and helped draughted the manuscript. All authors read and approved the final manuscript.

Acknowledgement of funding

Supported in part by research funding to Dr. Olson from the Northern Medical Program of the University of British Columbia and the University of Northern British Columbia.

References

- [1] N. Pandit-Taskar, M. Batraki, C.R. Divgi, Radiopharmaceutical therapy for palliation of bone pain from osseous metastases, *J. Nucl. Med.* 45 (2004) 1358–1365.
- [2] O.S. Nielsen, Palliative radiotherapy of bone metastases: there is now evidence for the use of single fractions, *Radiother. Oncol.* 52 (1999) 95–96.
- [3] X.H. Zhang, Q. Wang, W. Gerald, et al., Latent bone metastasis in breast cancer tied to src-dependent survival signals, *Cancer Cell.* 16 (2009) 67–78.
- [4] O.S. Nielsen, A.J. Munro, I.F. Tannock, Bone metastases: pathophysiology and management policy, *J. Clin. Oncol.* 9 (1991) 509–524.
- [5] R.A. Olson, M.S. Tiwana, M. Barnes, et al., Use of single- versus multiple-fraction palliative radiation therapy for bone metastases: Population-based analysis of 16,898 courses in a canadian province, *Int. J. Radiat. Oncol. Biol. Phys.* 89 (2014) 1092–1099.
- [6] R.A. Olson, M.S. Tiwana, M. Barnes, et al., Impact of using audit data to improve the evidence-based use of single-fraction radiation therapy for bone metastases in British Columbia, *Int. J. Radiat. Oncol. Biol. Phys.* (2015) (published online July 8) <http://dx.doi.org/10.1016/j.ijrobp.2015.06.044>.
- [7] E. Chow, Y.M. van der Linden, D. Roos, et al., Single versus multiple fractions of repeat radiation for painful bone metastases: a randomised, controlled, non-inferiority trial, *Lancet Oncol.* 15 (2014) 164–171.
- [8] J.E. Bekelman, A.J. Epstein, E.J. Emanuel, Single- vs multiple-fraction radiotherapy for bone metastases from prostate cancer, *JAMA* 310 (2013) 1501–1502.
- [9] J. Dreyes, R. Sailer, A. Schmitt-Graff, Cancer metastases of the hand, *Handchirurgie* 13 (1981) 296–304.
- [10] M.C. Leeson, J.T. Makley, J.R. Carter, Metastatic skeletal disease distal to the elbow and knee, *Clin. Orthop. Relat. Res.* 206 (1986) 94–99.
- [11] S. Hekmat, T. Ghaedian, H. Barati, et al., Solitary metastasis of gastric cancer to fibula: a case report, *Iran. J. Radiol.* 9 (2012) 161–164.
- [12] J.H. Healey, H.K. Brown, Complications of bone metastases: surgical management, *Cancer* 88 (2000) 2940–2951.
- [13] E.E. Pakos, D.N. Gartzonikas, P.G. Tsekeris, et al., Solitary tibial osteolytic lesion, *Case Rep. Med.* 2009 (2009) 352085.
- [14] A. Miric, M. Banks, D. Allen, et al., Cortical metastatic lesions of the appendicular skeleton from tumors of known primary origin, *J. Surg. Oncol.* 67 (1998) 255–260.
- [15] G. Letanche, C. Dumontet, P. Euvrard, et al., Distal metastases of bronchial cancers bone and soft tissue metastases, *Bull. Cancer* 77 (1990) 1025–1030.
- [16] E. Gontier, F. Vaylet, G. Bonardel, et al., Tomographie à émission de positons au [18F]-FDG et métastases distales dans les cancers broncho-pulmonaires, *Rev. Pneumol. Clin.* 61 (2005) 248–257.
- [17] A. Ahmadrza, P.J. Farhadnia, K. Hamidreza, Metastases to the hand and wrist: an analysis of 221 cases, *Hand Surg. Am.* 39 (5) (2014) 923–932.
- [18] S.V. Sejpal, A. Bhate, W. Small, Palliative radiation therapy in the management of brain metastases, spinal cord compression, and bone metastases, *Semin. Interv. Radiol.* 24 (2007) 363–374.