

Original Article

FRZB up-regulated in hepatocellular carcinoma bone metastasis

Jia Huang¹, Wenhao Hu², Xiangjin Lin³, Xuanwei Wang³, Ketao Jin⁴

Departments of ¹Cancer Chemotherapy and Radiotherapy, ²Cancer Chemotherapy and Radiotherapy, Yinzhou Hospital Affiliated to Medical School of Ningbo University, Ningbo 315040, Zhejiang Province, P. R. China; ³Department of Orthopedics, The First Affiliated Hospital, Zhejiang University School of Medicine, Hangzhou 310003, Zhejiang, P. R. China; ⁴Department of Gastrointestinal Surgery, Shaoxing People's Hospital, Shaoxing Hospital of Zhejiang University, Shaoxing 312000, Zhejiang Province, P. R. China

Received August 9, 2015; Accepted September 21, 2015; Epub October 1, 2015; Published October 15, 2015

Abstract: The clinical relevance of frizzled-related protein (FRZB) in hepatocellular carcinoma (HCC) bone metastasis remains uncertain. The aim of this study was to assess the clinical relationship of FRZB in patients with HCC bone metastasis after surgical resection. FRZB expression was evaluated by immunohistochemistry in formalin-fixed paraffin embedded (FFPE) HCC and paired bone metastasis tissues from 13 patients that underwent surgical resection. The clinical characteristics of 13 HCC patients with synchronous or metachronous bone metastasis received surgery were retrospectively reviewed. We found that FRZB was positive in 9 HCC tissues (69.2%) and in 11 paired bone metastatic tissues (84.6%) among these 13 paired samples. The expression of FRZB in the bone metastases was noticeably higher than that in the paired HCC tissues. The expression of FRZB was up-regulated in 10 (76.9%) paired bone metastases tissues. FRZB expression was up-regulated in HCC bone metastasis tissue, which suggested that FRZB might play a key role in the HCC bone metastasis.

Keywords: Hepatocellular carcinoma, bone metastasis, frizzled-related protein (FRZB)

Introduction

Liver cancer in men is the fifth most frequently diagnosed cancer worldwide but the second most frequent cause of cancer death. In women, it is the seventh most commonly diagnosed cancer and the sixth leading cause of cancer death. Half of these cases and deaths were estimated to occur in China [1]. Among primary liver cancers, hepatocellular carcinoma (HCC) represents the major histological subtype, accounting for 70% to 85% of the total liver cancer burden worldwide [1]. The primary risk factor for HCC is liver injury from diverse causes that leads to hepatic cirrhosis in most patients. An estimated 78% of HCC cases and 57% of cases of liver cirrhosis are caused by chronic infection with hepatitis B virus (HBV) or hepatitis C virus (HCV) [2, 3]. HCC is the sixth most prevalent cancer worldwide and the third leading cause of cancer-related death, although its geographical distribution is heterogeneous

with the highest incidence in sub-Saharan Africa and Eastern Asia [4]. Bone is an uncommon site of metastasis in HCC, with the incidence ranging from 3% to 20% [5]. Although bone involvement is reported as uncommon in HCC, its incidence has significantly increased in the last decade due to the longer survival of HCC patients related to recent progresses made both in the diagnosis and treatment of the disease [5-7]. A better understanding of the pathogenic mechanisms underlying the spread of bone metastases in HCC is important. Some retrospective studies have described the characteristics of bone metastasis from HCC [5, 8-10]. However, few data are yet available about bone involvement in patients with HCC, and no agreement has yet been reached about the treatment strategy for extrahepatic HCC metastases. The nature and the characteristics of bone metastases in HCC have not been fully explored in literature, presumably because HCC skeletal involvement was rarely diagnosed.

Frizzled-related protein (FRZB), a member of the secreted frizzled related protein (SFRP) family, also known as sFRP3, plays an important role in embryonic development. FRZB is one of the Wnt signaling pathway regulators. FRZB contains a 24-amino acid putative transmembrane segment [11], a cysteine-rich domain (CRD) which is similar to the putative Wnt-binding region of the frizzled family of transmembrane receptors, a netrin-like domain (NTR) which is homologous with tissue inhibitors of metalloproteases (TIMPs) [12]. Polymorphisms in the FRZB gene have been associated with osteoarthritis [13] and are considered one of the osteoblast regulatory genes. FRZB affects the cartilage integrity as well as cortical bone thickness and density. The mechanism of this protection can be partly attributed to FRZB suppression of the expression of WNT/ β -catenin target genes, including genes for MMP3 and cyclooxygenase 2 (COX2) [14]. Further study demonstrated that FRZB may bind and inhibit MMP3 proteinase activity through its NTR domain [14]. FRZB was seen to be acting as an oncogene in metastatic renal cancer [15]. Tissue microarray analysis showed that the level of FRZB protein was low in primary renal cancer tissues but high in metastatic renal cancer tissues. Functional analysis showed increased cell growth, invasion, and tube formation, and decreased numbers of apoptotic cells in the FRZB-transfected renal cancer cell line A498. The reverse trend was seen in metastatic cells (ACHN and Hs891.T) when FRZB expression was silenced by using a knock-down approach [15].

In this study, we evaluated the potential clinical relationship of FRZB in patients with HCC bone metastasis after surgical resection.

Patients and methods

Patients and tumor tissue samples

The institutional ethical committee approved the current retrospective study. A written informed consent was obtained for all patients. We reviewed the electronic medical records of consecutive patients in whom HCC and synchronous or metachronous bone metastasis was newly diagnosed from January 2009 to October 2014 at the Department of Orthopedics, the First Affiliated Hospital, Zhejiang University School of Medicine (**Table 1**). The diagnosis of HCC was mainly based on

recommendations of the American Association for the Study of Liver Diseases [16]. All patients underwent blood investigations, which included complete blood count, liver function tests, and tests for viral markers of hepatitis B and C infection. Serum alpha-fetoprotein (AFP) was estimated using a particle enzyme immunoassay (AxSYM System; Abbott Laboratories, Abbot Park, Illinois, USA; normal value <20 ng/ml). Upper gastrointestinal endoscopy was done in each case to detect the presence of esophageal varices. Patients with underlying cirrhosis were classified into Child's A, B or C based on the Child-Pugh classification [17]. Staging of HCC was done based on the Barcelona Clinic Liver Cancer (BCLC) staging protocol [18]. All patients were evaluated pre- and post-operatively using abdominal computed tomographic (CT) scan, magnetic resonance imaging (MRI), or fluorine-18 fluorodeoxyglucose positron emission tomography/computed tomographic scan (^{18}F -FDG PET/CT).

Immunohistochemistry

Five micromolar FFPE sections were cut, dewaxed, rehydrated, and subjected to antigen retrieval. After blocking endogenous peroxidase activity, the sections were incubated with the primary antibody against FRZB (Abcam, Cambridge, MA) (1:200) (overnight at 4 at 4°C). Immunohistochemistry was performed using the streptavidin-biotin peroxidase complex method (Lab Vision, Fremont, CA). The slides were examined and pictures were taken using an Olympus BX60 (Olympus, Japan). Sections known to stain positively were incubated in each batch and negative controls were also prepared by replacing the primary antibody with preimmune sera.

Expression analysis of FRZB in tumor tissue was performed by comparing staining intensity and the percentage of immunoreactive cells. Staining intensity was arbitrarily scored on a scale of four grades: 0 (no staining of cancer cells), 1 (weak staining), 2 (moderate staining), and 3 (strong staining), and the percentage of positive cells was scored as follows: 0 (0%), 1 (1% to 25%), 2 (26% to 50%), and 3 (>50%). FRZB staining positivity was determined using the following formula: overall score = positive percentage score \times intensity score. A score of 0 was defined as "0", >0 to \leq 2 as "1", >2 to \leq 6 as

FRZB expression in HCC bone metastasis

Table 1. Clinical characteristics of 13 hepatocellular carcinoma patients with synchronous or meta-chronous bone metastasis received surgery

	Gender (Male/ Female)	Age (Years)	AFP level (ng/ml)	ALT (IU/L)	AST (IU/L)	HBV (Po/Ne)	HCV (Po/Ne)	BCLC staging (A/B/C)	Child's score (A/B/C)	HCC NM	BM (S/M)	OS	Chem (Y/N)	Rad (Y/N)	MTT (Y/N)
Case 1	Female	67	NA	NA	NA	Po	Ne	NA	NA	2	M	84.0	Y	N	N
Case2	Male	39	8.4	NA	NA	Po	Ne	NA	NA	2	M	57.5	Y	Y	Y
Case 3	Male	49	24.2	349	229	Po	Ne	C	B	>3	M	NA	Y	N	N
Case 4	Male	58	27.1	NA	NA	Po	Ne	A	A	2	M	42.3	NA	N	N
Case 5	Male	74	5.7	41	32	Po	Ne	C	A	1	M	NA	Y	N	N
Case 6	Male	43	2335.3	48	83	Po	Ne	B	A	>3	M	3.0	Y	Y	Y
Case 7	Male	62	8.3	33	34	Po	Ne	A	A	1	M	NA	Y	N	N
Case 8	Male	50	14.7	27	117	Po	Ne	C	A	>3	M	25.0	Y	N	Y
Case 9	Male	67	89.6	NA	NA	Po	Ne	A	NA	>3	M	NA	Y	N	N
Case 10	Male	55	4.4	28	30	Po	Ne	NA	A	>3	S	9.3	Y	N	N
Case 11	Male	52	27.5	28	21	Po	Ne	B	A	>3	M	36.0	Y	N	N
Case 12	Male	26	2175.2	16	21	Po	Ne	C	A	3	M	21.6	Y	N	N
Case 13	Male	42	228.9	23	21	Po	Ne	B	A	>3	M	27.5	Y	N	Y

Abbreviations: HBV, hepatitis B virus infection. HCV, hepatitis C virus infection. Po, positive. Ne, negative. AST, aspartate aminotransferase. ALT, aspartate aminotransferase. AFP, alpha-fetoprotein. BCLC staging, Barcelona clinic liver cancer staging. NA, not available. OS, overall survival (months). Chem, chemotherapy. MTT, Molecularly targeted therapy. Rad, radiotherapy. HCC NM, hepatocellular carcinoma number of masses. BM (S/M), bone metastases (S, synchronous; M, metachronous). Y, yes. N, No.

"2", and >6 to ≤ 9 as "3". In the end, tumor samples rated as level 0 or 1 were defined as negative for expression, whereas samples rated as level 2 or 3 were defined as positive.

Data collection and follow-up

The clinical, laboratory, and radiologic records of all patients were retrospectively reviewed (Table 1). Liver function tests were checked in all patients every three months in order to evaluate hepatic functional reserve. The results of all 13 HCC patients with synchronous or metachronous bone metastasis were analyzed. Follow-up cross-sectional imaging (contrast-enhanced CT or MRI) was performed one month after treatment. Further treatments were based on clinical evaluation, laboratory values and imaging response. Patients were followed-up every 3 months. The patients were followed up until death or until the date of last follow-up. Follow-up was finished on February 28, 2015. Overall survival was calculated from the date after hepatic resection to the date of death for any cause or last follow-up.

Results

Clinicopathological characteristics of HCC patients with bone metastasis

The clinicopathological characteristics of the cohort are summarized in Table 1. The 13

patients (12 males, 1 female) had an age range from 26 to 74 years. Hepatitis B virus (HBV) infection was the most common etiological factor of HCC, seen in 13 (100%) patients. No patient with hepatitis C virus (HCV) infection was found. BCLC B patients were 3 (23.1%), and BCLC C patients were 4 (30.8%). Child's score a patients were 9 (69.2%), and Child's score B patients were 1 (7.7%). All the patients received synchronous or metachronous resections of the HCC and bone metastases. Of the patients, only 1 patient (7.7%) was treated with surgery alone, 12 (92.3%) patients received adjuvant chemotherapy, 2 (15.4%) patients received adjuvant radiotherapy, 4 (30.8%) patients received molecularly targeted therapy preoperatively or postoperatively.

FRZB up-regulated in HCC bone metastasis tissue

We evaluated the expression of FRZB in 13 HCC samples and paired bone metastatic samples using the method of immunohistochemical staining. We found that FRZB was positive in 9 HCC tissues (69.2%) and in 11 paired bone metastatic tissues (84.6%). The expression of FRZB in the bone metastases was noticeably higher than that in the paired HCC tissues (Figure 1). The expression of FRZB was up-regulated in 10 (76.9%) paired bone metastases tissues. The potential clinical relevance of

FRZB expression in HCC bone metastasis

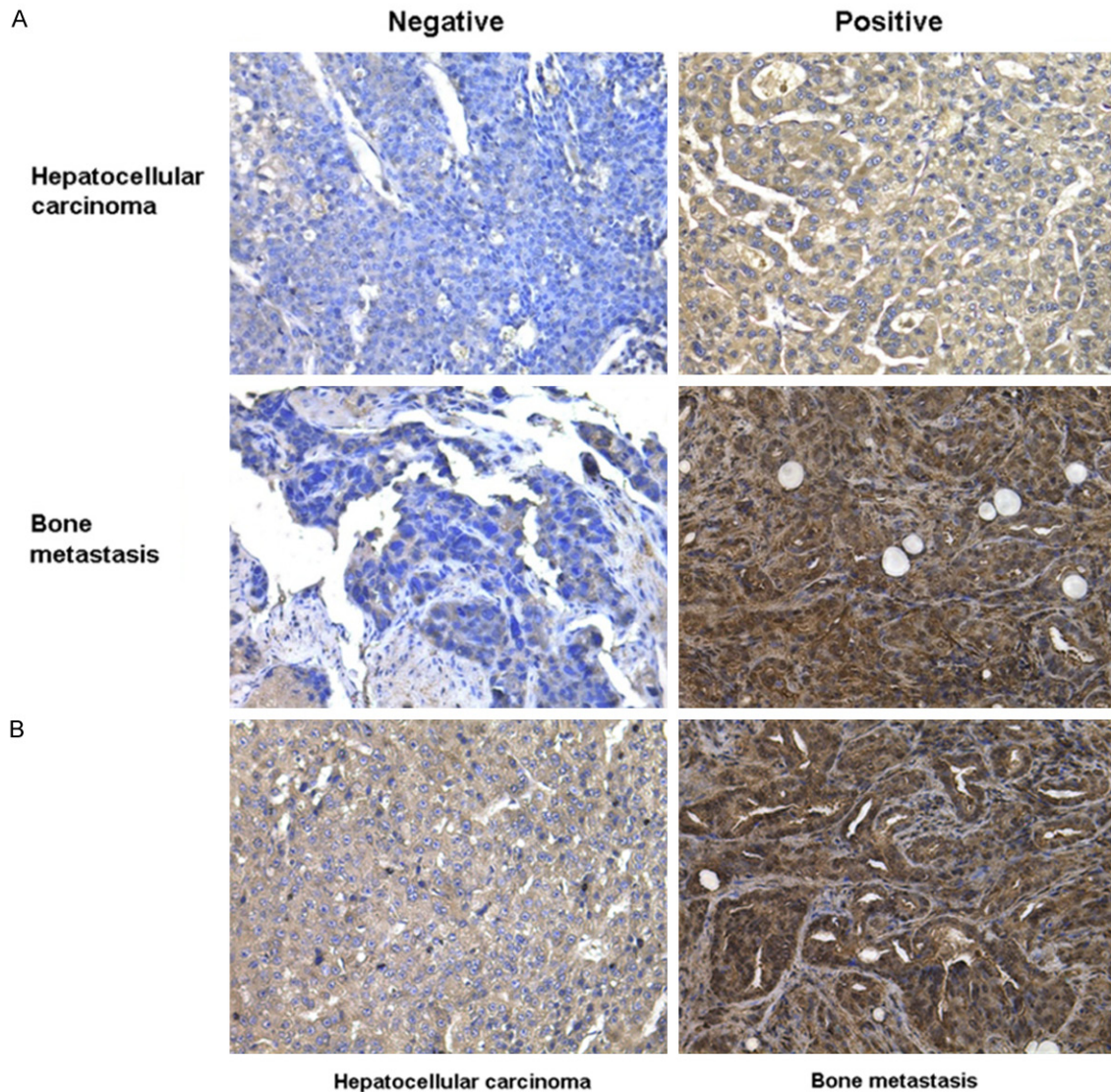


Figure 1. Expression of FRZB in hepatocellular carcinoma (HCC) and paired bone metastatic tissues. A. Negative and positive staining of FRZB in HCC and paired bone metastatic tissues (original magnification $\times 200$). B. Representative immunohistochemical staining of FRZB in HCCr tissues and paired bone metastatic tissues. The expression of FRZB is significantly greater in the HCC bone metastatic tissues than in HCC tissues (original magnification $\times 200$).

FRZB expression in HCC patients with synchronous or metachronous bone metastasis received surgery was shown in **Table 2**. These results suggested that FRZB might play a key role in the HCC bone metastasis.

Discussion

HCC is the fifth most common cancer in men worldwide [4]. The bone is well known to be the third most frequent site of metastases by all tumors, after the lungs and lymph nodes, and

HCC bone colonization has been reported in approximately 20 % of patients affected by this tumor [5, 19, 20]. Recently, the progress in both diagnostic modalities and therapeutic procedures, such as surgical resection, radiofrequency ablation, and transcatheter arterial chemoembolization in association with treatments using small molecules as multikinase inhibitors, has prolonged the survival in HCC patients which led to a concurrent worsening of the tumor progression within the skeleton and the formation of bone metastases [5-7, 19]. To

FRZB expression in HCC bone metastasis

Table 2. The clinical relevance of FRZB expression in HCC patients with synchronous or metachronous bone metastasis received surgery

	FRZB expression (Positive/Negative)		FRZB up-regulation in bone metastasis (Yes/No)	OS
	HCC	Paired bone metastasis		
Case 1	Negative	Negative	No	84.0
Case 2	Negative	Positive	Yes	57.5
Case 3	Positive	Positive	Yes	NA
Case 4	Positive	Positive	No	42.3
Case 5	Positive	Positive	Yes	NA
Case 6	Positive	Positive	Yes	3.0
Case 7	Negative	Negative	No	NA
Case 8	Positive	Positive	Yes	25.0
Case 9	Negative	Positive	Yes	NA
Case 10	Positive	Positive	Yes	9.3
Case 11	Positive	Positive	Yes	36.0
Case 12	Positive	Positive	Yes	21.6
Case 13	Positive	Positive	Yes	27.5

Abbreviations: HCC, hepatocellular carcinoma. NA, not available. OS, overall survival (months).

date, few data are yet available about bone involvement in patients with HCC, and the nature and the characteristics of bone metastases in HCC have not been fully explored.

FRZB, the first member of the sFRP family, was isolated as a chondrogenic factor in developing cartilage [11]. FRZB binds to both Wnt-8 and Wnt-1 and acts as a functional inhibitor of Wnt-8 activity [21, 22]. It was demonstrated that FRZB was seen to be acting as an oncogene in metastatic renal cancer [15]. Hirata, et al. found that FRZB protein was up-regulated in metastatic renal cancer tissues compared with primary renal cancer tissues [15]. However, FRZB is also involved in malignant tumor generation and progression. Numerous studies strongly suggest a tumor suppressor role of FRZB. Deregulation of FRZB is found in bone-originated malignant diseases. Expression of FRZB was also found to be related to bone involvement at diagnosis in myeloma plasma cells [23]. Loss of FRZB expression was commonly found in osteogenic sarcoma tissues [24]. Expression of FRZB suppresses epithelial original prostate cancer cell in vivo growth and progression [25]. FRZB can function as a melanoma migration and invasion suppressor by interfering with Wnt5a signaling [26]. FRZB decreases growth and invasiveness of fibrosar-

coma cells and this inhibition is associated with downregulation of c-Met expression and inhibited Met-mediated signaling [27]. FRZB suppressed gastric cancer cell proliferation and modulated the balance between proliferation and differentiation in gastric cancer [28]. Knockdown of FRZB in gastric cancer cells increased cell growth and migration/invasion [29]. FRZB knockdown may upregulate the Wnt/ β catenin pathway and promote aggressiveness in gastric cancer [29].

The aim of this study was to assess the clinical relationship of FRZB in patients with HCC bone metastasis after surgical resection. Herein, we evaluated the FRZB expres-

sion in HCC and paired bone metastatic tissues from 13 patients, which had clinical follow-up records. Our results indicated that the positive expression of FRZB in HCC bone metastasis might have a shorter overall survival and that FRZB might play a key role in the HCC bone metastasis. These data, for the first time, imply that FRZB has distinct roles in HCC bone metastasis and is worthy of further investigation.

In summary, this is the first study showing the expression of FRZB in HCC bone metastasis. Our results found that FRZB expression was up-regulated in HCC bone metastasis tissue, which suggested that FRZB might play a key role in the HCC bone metastasis. Our results indicated FRZB might be a novel predictor for poor prognosis of HCC patients with bone metastasis after surgical resection and FRZB might be a promising candidate for targeted therapy of HCC bone metastasis.

Acknowledgements

This work was supported by National Natural Science Foundation of China (Grants No. 81374014 and No. 81472210), Zhejiang Provincial Medical and Healthy Science and Technology Projects (Grant No. 2013KYA228), Zhejiang Provincial Science and Technology

Project (Grant No. 2013C33112), Science Research Fund of Taizhou (Grants No. A121KY08, A131KY13-3 and A131KY13-12), and Enze Medical Research Fund (Grants No. 12EZA1, 13EZA2 and 13EZB6).

Disclosure of conflict of interest

None.

Address correspondence to: Dr. Xuanwei Wang, Department of Orthopedics, The First Affiliated Hospital, Zhejiang University School of Medicine, 79 Qingchun Road, Hangzhou 310003, Zhejiang, P. R. China. E-mail: dr.wangxuanwei@aliyun.com; Dr. Ketao Jin, Department of Gastrointestinal Surgery, Shaoxing People's Hospital, Shaoxing Hospital of Zhejiang University, 568 Zhongxing North Road, Shaoxing 312000, Zhejiang, P. R. China. E-mail: jinketao2001@zju.edu.cn

References

- [1] Jemal A, Bray F, Center MM, Ferlay J, Ward E and Forman D. Global cancer statistics. *CA Cancer J Clin* 2011; 61: 69-90.
- [2] Perz JF, Armstrong GL, Farrington LA, Hutin YJ and Bell BP. The contributions of hepatitis B virus and hepatitis C virus infections to cirrhosis and primary liver cancer worldwide. *J Hepatol* 2006; 45: 529-538.
- [3] Chu CM and Liaw YF. Hepatitis B virus-related cirrhosis: natural history and treatment. *Semin Liver Dis* 2006; 26: 142-152.
- [4] El-Serag HB. Epidemiology of viral hepatitis and hepatocellular carcinoma. *Gastroenterology* 2012; 142: 1264-1273, e1.
- [5] Fukutomi M, Yokota M, Chuman H, Harada H, Zaito Y, Funakoshi A, Wakasugi H and Iguchi H. Increased incidence of bone metastases in hepatocellular carcinoma. *Eur J Gastroenterol Hepatol* 2001; 13: 1083-1088.
- [6] Si MS, Amersi F, Golish SR, Ortiz JA, Zaky J, Finklestein D, Busuttill RW and Imagawa DK. Prevalence of metastases in hepatocellular carcinoma: risk factors and impact on survival. *Am Surg* 2003; 69: 879-885.
- [7] Cho HS, Oh JH, Han I and Kim HS. Survival of patients with skeletal metastases from hepatocellular carcinoma after surgical management. *J Bone Joint Surg Br* 2009; 91: 1505-1512.
- [8] Ahmad Z, Nisa AU, Uddin Z and Azad NS. Unusual metastases of hepatocellular carcinoma (hcc) to bone and soft tissues of lower limb. *J Coll Physicians Surg Pak* 2007; 17: 222-223.
- [9] Kim S, Chun M, Wang H, Cho S, Oh YT, Kang SH and Yang J. Bone metastasis from primary hepatocellular carcinoma: characteristics of soft tissue formation. *Cancer Res Treat* 2007; 39: 104-108.
- [10] Santini D, Pantano F, Riccardi F, Di Costanzo GG, Addeo R, Guida FM, Ceruso MS, Barni S, Bertocchi P, Marinelli S, Marchetti P, Russo A, Scartozzi M, Faloppi L, Santoni M, Cascinu S, Maiello E, Silvestris F, Tucci M, Ibrahim T, Masi G, Gnoni A, Comandone A, Fazio N, Conti A, Imarisio I, Pisconti S, Giommoni E, Cinieri S, Catalano V, Palmieri VO, Infante G, Aieta M, Trogu A, Gadaleta CD, Brunetti AE, Lorusso V and Silvestris N. Natural history of malignant bone disease in hepatocellular carcinoma: final results of a multicenter bone metastasis survey. *PLoS One* 2014; 9: e105268.
- [11] Hoang B, Moos M Jr, Vukicevic S and Luyten FP. Primary structure and tissue distribution of FRZB, a novel protein related to Drosophila frizzled, suggest a role in skeletal morphogenesis. *J Biol Chem* 1996; 271: 26131-26137.
- [12] Banyai L and Patthy L. The NTR module: domains of netrins, secreted frizzled related proteins, and type I procollagen C-proteinase enhancer protein are homologous with tissue inhibitors of metalloproteases. *Protein Sci* 1999; 8: 1636-1642.
- [13] Killock D. Osteoarthritis: Frzb knockout reveals the complexity of Wnt signaling in joint homeostasis. *Nat Rev Rheumatol* 2012; 8: 123.
- [14] Lories RJ, Peeters J, Bakker A, Tylzanowski P, Derese I, Schrooten J, Thomas JT and Luyten FP. Articular cartilage and biomechanical properties of the long bones in Frzb-knockout mice. *Arthritis Rheum* 2007; 56: 4095-4103.
- [15] Hirata H, Hinoda Y, Ueno K, Majid S, Saini S and Dahiya R. Role of secreted frizzled-related protein 3 in human renal cell carcinoma. *Cancer Res* 2010; 70: 1896-1905.
- [16] Bruix J, Sherman M and Practice Guidelines Committee AAftSoLD. Management of hepatocellular carcinoma. *Hepatology* 2005; 42: 1208-1236.
- [17] Pugh RN, Murray-Lyon IM, Dawson JL, Pietroni MC and Williams R. Transection of the oesophagus for bleeding oesophageal varices. *Br J Surg* 1973; 60: 646-649.
- [18] Cillo U, Vitale A, Grigoletto F, Farinati F, Brolese A, Zanusi G, Neri D, Boccagni P, Srsen N, D'Amico F, Ciarleglio FA, Bricida A and D'Amico DF. Prospective validation of the Barcelona Clinic Liver Cancer staging system. *J Hepatol* 2006; 44: 723-731.
- [19] Uchino K, Tateishi R, Shiina S, Kanda M, Masuzaki R, Kondo Y, Goto T, Omata M, Yoshida H and Koike K. Hepatocellular carcinoma with extrahepatic metastasis: clinical features and prognostic factors. *Cancer* 2011; 117: 4475-4483.
- [20] Natsuzaka M, Omura T, Akaike T, Kuwata Y, Yamazaki K, Sato T, Karino Y, Toyota J, Suga T

FRZB expression in HCC bone metastasis

- and Asaka M. Clinical features of hepatocellular carcinoma with extrahepatic metastases. *J Gastroenterol Hepatol* 2005; 20: 1781-1787.
- [21] Wang S, Krinks M, Lin K, Luyten FP and Moos M Jr. Frzb, a secreted protein expressed in the Spemann organizer, binds and inhibits Wnt-8. *Cell* 1997; 88: 757-766.
- [22] Leyns L, Bouwmeester T, Kim SH, Piccolo S and De Robertis EM. Frzb-1 is a secreted antagonist of Wnt signaling expressed in the Spemann organizer. *Cell* 1997; 88: 747-756.
- [23] Kristensen IB, Haaber J, Lyng MB, Knudsen LM, Rasmussen T, Ditzel HJ and Abildgaard N. Myeloma plasma cell expression of osteoblast regulatory genes: overexpression of SFRP3 correlates with clinical bone involvement at diagnosis. *Leuk Lymphoma* 2013; 54: 425-427.
- [24] Mandal D, Srivastava A, Mahlum E, Desai D, Maran A, Yaszemski M, Jalal SM, Gitelis S, Bertoni F, Damron T, Irwin R, O'Connor M, Schwartz H, Bolander ME and Sarkar G. Severe suppression of Frzb/sFRP3 transcription in osteogenic sarcoma. *Gene* 2007; 386: 131-138.
- [25] Zi X and Simoneau AR. Flavokawain A, a novel chalcone from kava extract, induces apoptosis in bladder cancer cells by involvement of Bax protein-dependent and mitochondria-dependent apoptotic pathway and suppresses tumor growth in mice. *Cancer Res* 2005; 65: 3479-3486.
- [26] Ekstrom EJ, Sherwood V and Andersson T. Methylation and loss of Secreted Frizzled-Related Protein 3 enhances melanoma cell migration and invasion. *PLoS One* 2011; 6: e18674.
- [27] Guo Y, Xie J, Rubin E, Tang YX, Lin F, Zi X and Hoang BH. Frzb, a secreted Wnt antagonist, decreases growth and invasiveness of fibrosarcoma cells associated with inhibition of Met signaling. *Cancer Res* 2008; 68: 3350-3360.
- [28] Qu Y, Li JF, Cai Q, Wang YW, Gu QL, Zhu ZG and Liu BY. Over-expression of FRZB in gastric cancer cell suppresses proliferation and induces differentiation. *J Cancer Res Clin Oncol* 2008; 134: 353-364.
- [29] Qin S, Zhang Z, Li J and Zang L. FRZB knock-down upregulates beta-catenin activity and enhances cell aggressiveness in gastric cancer. *Oncol Rep* 2014; 31: 2351-2357.