



Published in final edited form as:

*Magn Reson Imaging*. 2016 January ; 34(1): 18–25. doi:10.1016/j.mri.2015.10.002.

## Isotropic 3D Black Blood MRI of Abdominal Aortic Aneurysm Wall and Intraluminal Thrombus

Chengcheng Zhu<sup>1,\*</sup>, Henrik Haraldsson<sup>1</sup>, Farshid Faraji<sup>1</sup>, Christopher Owens<sup>2</sup>, Warren Gasper<sup>2</sup>, Sinyeob Ahn<sup>3</sup>, Jing Liu<sup>1</sup>, Gerhard Laub<sup>3</sup>, Michael D. Hope<sup>1</sup>, and David Saloner<sup>1,4</sup>

<sup>1</sup>Department of Radiology and Biomedical Imaging, UCSF, San Francisco, CA, USA

<sup>2</sup>Vascular Surgery Service, VA Medical Center, San Francisco, USA

<sup>3</sup>Siemens Healthcare, CA, USA

<sup>4</sup>Radiology Service, VA Medical Center, San Francisco, USA

### Abstract

**Introduction**—The aortic wall and intraluminal thrombus (ILT) have been increasingly studied as potential markers of progressive disease with abdominal aortic aneurysms (AAAs). Our goal was to develop a high resolution, 3D black blood MR technique for AAA wall and ILT imaging within a clinically acceptable scan time.

**Methods**—Twenty two patients with AAAs (maximal diameter  $4.3 \pm 1.0$ cm), along with five healthy volunteers, were imaged at 3T with a 3D T<sub>1</sub>-weighted fast-spin-echo sequence using variable flip angle trains (SPACE) with a preparation pulse (DANTE) for suppressing blood signal. Volunteers and ten patients were also scanned with SPACE alone for comparison purposes. The signal to noise ratio (SNR) and the aortic wall/ILT to lumen contrast to noise ratio (CNR) were measured. Qualitative image scores (1–4 scale) assessing the inner lumen and outer wall boundaries of AAA were performed by two blinded reviewers. In patients with ILT, the ratio of ILT signal intensity (ILT<sub>SI</sub>) over psoas muscle SI (Muscle<sub>SI</sub>) was calculated, and the signal heterogeneity of ILT was quantified as standard deviation (SD) over the mean.

**Results**—All subjects were imaged successfully with an average scan time of  $7.8 \pm 0.7$  minutes. The DANTE preparation pulse for blood suppression substantially reduced flow artifacts in SPACE with lower lumen SNR (8.8 vs. 21.4,  $p < 0.001$ ) and improved the wall/ILT to lumen CNR (9.9 vs. 6.3,  $p < 0.001$ ) in patients. Qualitative assessment showed improved visualization of lumen boundaries (73% higher scores on average,  $p = 0.01$ ) and comparable visualization of outer wall boundary ( $p > 0.05$ ). ILT was present in ten patients, with relatively high signal and a wide SD

---

Corresponding author: Chengcheng Zhu, Department of Radiology and Biomedical Imaging, University of California San Francisco, Room BA34, VA Medical Center, 4150 Clement Street, San Francisco, CA, USA, 94121, Tel: +1 415 221 4810 x 3818, Chengcheng.Zhu@ucsf.edu.

#### Competing interests

None

**Publisher's Disclaimer:** This is a PDF file of an unedited manuscript that has been accepted for publication. As a service to our customers we are providing this early version of the manuscript. The manuscript will undergo copyediting, typesetting, and review of the resulting proof before it is published in its final citable form. Please note that during the production process errors may be discovered which could affect the content, and all legal disclaimers that apply to the journal pertain.

(average  $ILT_{SI}/Muscle_{SI}$   $1.42 \pm 0.48$  (range 0.75–2.11) ) and with SD/mean of  $27.7\% \pm 6.6\%$  (range 19.6% – 39.4%).

**Conclusion**—High resolution, 3D black blood MRI of AAAs can be achieved in a clinical accepted scan time with reduction of flow artifacts using the DANTE preparation pulse. Signal characteristics of ILT can be quantified and may be used for improved patient-specific risk stratification.

### Keywords

3D black blood; vessel wall MRI; abdominal aortic aneurysm; intra-luminal thrombus; blood suppression

## Introduction

Abdominal aortic aneurysm (AAA) disease is a common condition among men >60 years old, and is associated with a high rate of morbidity and mortality. Current management of patients with AAAs is based on the maximal diameter of the aneurysm, and intervention is recommended when the AAA has a diameter larger than 5.5 cm [1]. While straightforward and practical, diameter measurements alone do not always predict the progression and rupture of AAAs. A considerable fraction of small AAAs (< 5.5 cm) rupture, whereas many larger AAAs never rupture [2]. The annual rupture risk of small AAAs ranges 0.7% to ~10% [2]. It has been reported that imaging the pathology within the aneurysm wall and intraluminal thrombus (ILT) may play a key role in providing a more complete, patient-specific risk stratification [3].

Two-dimensional (2D) ultrasound (US) is the most widely used tool of AAA screening within the general population [4]. However, it is limited by inter-operator variability and is not able to capture the three-dimensional (3D) anatomy of an AAA as it is not a cross-sectional modality. Computed Tomography (CT) is also frequently used, but it requires radiation and iodinated contrast, and so would not be the preferred modality for serial monitoring.

MRI is a promising tool for AAA monitoring because it is a cross-sectional modality that does not require radiation and has excellent soft tissue contrast that allows characterization of the aortic wall and ILT. Previous MRI studies of the AAA wall, however, had limited coverage, coarse through-plane resolution (4mm – 5mm), and degraded image quality due to flow artifacts [5] [6].

High resolution, 3D black blood techniques using fast-spin-echo (FSE) sequences with variable flip angle trains (SPACE, Siemens Medical Systems) is advantageous in aorta wall/ILT imaging given its high scan efficiency enabled by the use of long echo trains [7] and its intrinsic black blood effect [8]. It has been successfully used for aorta wall imaging in healthy volunteers and patients with cardiovascular or atherosclerotic disease with high isotropic resolution ( $1.1\text{mm}^3$ ) [9] [10] [11]. However, blood suppression is less effective in the presence of slow or complex flow, and flow artifacts have been observed even in healthy volunteers with normal aorta geometry [9].

In patients with AAA disease, complex flow is common [3] and may lead to strong flow artifacts. Novel blood suppression techniques including flow-sensitive dephasing (FSD) [12] and Delay Alternating with Nutation for Tailored Excitation (DANTE) [13] can be used to improve the blood suppression in SPACE and they have been successfully applied in carotid plaque imaging [12] [14]. These techniques have not been evaluated in patients with AAA disease. Previous 3D MRI studies of aorta wall are also limited by the long scan times needed (~22min) [9] [10], which are poorly tolerated by patients.

ILT is commonly present in AAAs with diameter greater than 4cm [15]. A previous study suggested AAAs with fresh ILT could progress two times faster compared with those without fresh ILT [5]. Identification of ILT and its composition may improve the risk evaluation of AAA.

This study aims to: 1) optimize the SPACE acquisition such that it can achieve good image quality and be acquired within a clinically acceptable scan time; 2) evaluate the blood suppression performance of SPACE with and without DANTE preparation for aorta wall/ILT imaging in healthy volunteers and patients with AAA disease; and, 3) evaluate whether a  $T_1$ -weighted SPACE protocol would be able to characterize thrombus components within the AAA.

## Methods

### Technical considerations

Three dimensional black blood volume acquisitions were used with a para-coronal slab placed over the volume of interest. The diagram of the pulse sequence used in this study is shown in Figure 1.a. Two image data sets were acquired for comparison – one with DANTE preparation and the other without DANTE. If used, DANTE was applied prior to a fat saturation pulse, and this was followed by the SPACE acquisition. Immediately after DANTE preparation, a spoiler gradient was applied to eliminate the magnetization remaining in the XY plane. As the DANTE preparation was included in the TR, the total scan time was unchanged.

Compared to traditional 3D FSE sequences, SPACE allows a reduced scan time through the use of a long echo train. In traditional FSE sequences, when the echo train length (ETL) is long,  $T_2$  signal decay leads to image blurring. In SPACE, modulation of the refocusing flip angles keeps the magnetization relatively constant over the long echo train, and hence reduces blurring [16]. An echo train of 60 that was relatively long compared to previous studies [9] [10] was used in this study to reduce the scan time. A short echo spacing was used to minimize the duration of the echo train in order to reduce blurring. The flip angle train used in SPACE is shown in Figure 1.b.

The ability of DANTE to suppress signal from flowing blood depends on the number of RF pulses ( $N_p$ ), RF flip angles, and the time between RF pulses ( $t_D$ ) [13]. DANTE parameters used in this study were adopted from previous vascular studies [17]. The DANTE train number was reduced to 100 (preparation time 100ms) to minimize the signal loss in the vessel wall that might otherwise result from aortic wall motion with a long preparation. A

high flip angle ( $15^\circ$ ) was used to ensure that even in AAAs with complex recirculating flow, that there would be good suppression of signal from flowing blood.

### Study population

Twenty two patients (all male, age  $69 \pm 5$ ) with AAA disease ( $>3\text{cm}$  in diameter as identified on either ultrasound or CT) and five volunteers (all male, age 26–42) were recruited for this study. Both the volunteer and patient studies were conducted following IRB approval of Veteran Affairs Regional Counsel and University of California San Francisco (reference number: 10-03248). All subjects involved gave informed written consent to report individual's data.

### Scan parameters

All examinations were performed on a 3T Siemens Skyra scanner using a 32 channel body coil and a spine array coil. Both volunteers and patients underwent 3D  $T_1$  weighted SPACE with DANTE preparation. Volunteers and ten patients also underwent SPACE alone for comparison purposes.

The acquisition parameters of  $T_1$ w SPACE were: TR/TE = 800~1040ms/20ms; echo train length (ETL) 60; 44~60 coronal slices with 1.3mm slice thickness; slice oversampling factor: 15%; 32cm $\times$ 32cm field of view and 256 $\times$ 256 matrix; band width: 781 Hz/pixel; echo spacing: 3.58 ms; duration of the echo train: 215ms; k-space ordering: centric linear with elliptical acquisition; 3.4 averages (40% of the k-space at the center was acquired during the fourth averages); between 7.1 to 9 minutes scan time (depending on number of slices which was increased when necessary to accommodate the anatomy.) A 1.3mm isotropic resolution was achieved. The coronal slab was placed to cover the abdominal aorta from renal artery to aorta bifurcation. Frequency selective fat suppression was used. No respiratory or cardiac gating was used.

DANTE parameters: train length 100, RF gap 1ms; gradient amplitude 22mT/m; gradient duration 700 $\mu\text{s}$ ; RF flip angle  $15^\circ$ .

### Image Analysis

Axial slices were reformatted from acquired 3D datasets with a 1.3mm slice thickness. In volunteers, two slices were selected per subject: one slice at the renal arteries and one slice at the aorta bifurcation. In patients, axial slices with aneurysm presentation (defined as  $>3\text{mm}$  in diameter) were selected at 5.2mm intervals (every 5 slices). In total, 10 slices in the volunteer study and 106 slices in the patient study were included in the analysis.

Boundaries of the wall/ILT and the lumen of the aorta were manually contoured on reformatted axial slices using OsiriX dicom viewer (Version 6.0.1, Pixmeo SARL, USA) (Figure 2.a). The areas and signal intensities (SIs) of wall/ILT and lumen were measured. Standard deviation of the noise (Noise<sub>SD</sub>) was determined as the standard deviation of the signal in an artifact free background region (Figure 2.b).

Signal to noise ratio of wall/ILT (Wall/ILT<sub>SNR</sub>) and lumen (Lumen<sub>SNR</sub>) was calculated as:

$$\begin{aligned} \text{Wall/ILT}_{\text{SNR}} &= \text{SI}_{\text{wall/ILT}} / \text{Noise}_{\text{SD}} \\ \text{Lumen}_{\text{SNR}} &= \text{SI}_{\text{lumen}} / \text{Noise}_{\text{SD}} \end{aligned}$$

Wall/ILT to lumen contrast to noise ratio ( $\text{CNR}_{\text{wall/ILT-lumen}}$ ) was calculated as:

$$\text{CNR}_{\text{wall/ILT-lumen}} = (\text{SI}_{\text{wall/ILT}} - \text{SI}_{\text{lumen}}) / \text{Noise}_{\text{SD}}$$

The  $\text{Wall/ILT}_{\text{SNR}}$ ,  $\text{Lumen}_{\text{SNR}}$ ,  $\text{CNR}_{\text{wall/ILT-lumen}}$  and the areas of wall and lumen as measured on SPACE and DANTE-SPACE were compared.

Two readers with 10/11 years experience independently evaluated the image quality of the AAA images with a qualitative scores of 1 to 4 using the following criteria, and the readers were blinded to the sequences used.

Lumen boundary visualization quality: 1-bad: strong flow artifacts, lumen boundary was not visible, non-diagnostic; 2-fair: moderate flow artifacts, most of the lumen boundary was visible; 3-good: few flow artifacts, lumen boundary was not obscured; 4-excellent: No flow artifacts, lumen boundary was clearly shown.

Outer wall boundary visualization quality: 1-bad: not visible, not diagnostic. 2-fair: most of the outer wall boundary is visible; 3-good: outer wall boundary is not obscured; 4-outer wall boundary is clearly shown with good contrast.

Representative images with image scores 1–4 are shown in Figure 3.

In patients whose AAA manifested ILT, ILT were differentiated on the basis of signal intensity with reference to the psoas muscle on  $T_1$  weighted images (as validated by histology in a previous publication [5]) (Figure 2c). Three slices were selected for analysis for each AAA: one central slice at the maximal diameter, one slice at the middle of the upper part of ILT, and one slice at the middle of the lower part of ILT. The ratio of ILT signal intensity ( $\text{ILT}_{\text{SI}}$ ) over psoas muscle SI ( $\text{Muscle}_{\text{SI}}$ ) was calculated, and the signal heterogeneity of ILT was quantified as standard deviation (SD) over the mean. Then the ratios were averaged in three slices.

### Statistical analysis

Normality assumptions were formally assessed using a Shapiro-Wilk's test. Distributions were summarized using the median [inter-quartile range (IQR)] or the mean  $\pm$  SD. A paired t-test or Wilcoxon matched paired test was used to compare between methods when the data was/was not normally distributed, respectively. A p-value of less than 0.05 was considered significant. All p-values were 2-sided. Graph Pad prism 5 was used for data analysis.

## Results

High isotropic resolution ( $1.3\text{mm}^3$ ) 3D datasets of the whole abdominal aorta were acquired with an average scan time of 7.8 minutes (range: 7.1–9.2 minutes). SPACE and DANTE-SPACE were acquired with the same scan times.

Sample images of SPACE and DANTE-SPACE in volunteers and patients are shown in Figure 4–6. Quantitative comparisons of SNR/CNR and area measurements between SPACE and DANTE-SPACE are shown in Table 1 and Figure 7.

The addition of DANTE substantially reduced flow artifacts in SPACE. Lumen SNR in DANTE-SPACE was significantly lower than SPACE ( $p<0.001$ ) in both volunteers and patients. Flow artifacts were significantly severer in SPACE images in patients compared with that in volunteers with two-fold higher lumen SNR ( $p<0.001$ ). In DANTE-SPACE images, even though flow artefacts were rarely observed, lumen SNR was still higher in patients compared with volunteers ( $p<0.001$ ).

Even though DANTE decreased the wall/ILT SNR ( $p<0.001$ ), the wall/ILT-lumen CNR was increased in patients ( $p<0.001$ ) and remained equivalent in volunteers ( $p=0.41$ ). Wall/ILT area measurements were similar on DANTE-SPACE and SPACE ( $p>0.05$ ), and the lumen area was slightly larger with DANTE-SPACE ( $p<0.01$ ).

Qualitative image quality scores for visualization of the lumen/outer wall boundaries of SPACE and DANTE-SPACE images of AAAs are shown in Table 2. The additional DANTE module significantly improved the lumen boundary visualization (reader1:  $p=0.01$ ; reader 2:  $p=0.01$ ). Outer wall boundary visualization was equivalent between methods (reader 1:  $p=0.48$ ; reader 2:  $p=0.17$ ). Image scores given by two readers were comparable ( $p>0.05$ ).

Aortic wall boundaries in volunteers and patients were mostly clearly visualized in DANTE-SPACE images. In DANTE-SPACE, flow artifacts were only observed in one patient (Figure 6), and the aneurysm wall could still be defined. The maximal diameter of AAA measured in DANTE-SPACE was  $4.3\pm 1.0\text{cm}$  (range 3.0cm to 7.0cm).

ILT was present in ten patients and all ILT was clearly visualized. The average  $ILT_{SI}/Muscle_{SI}$  ratio was high with a large SD ( $1.42\pm 0.48$ , range 0.75–2.11). There was clear differentiation of regions of high SI and regions of lower SI within the ILT – presumed to be fresh and old thrombus respectively. The average SD/mean ratio was  $27.7\%\pm 6.6\%$  (range 19.6% – 39.4%), representing signal heterogeneity within ILT was common.

## Discussion

This study optimizes a 3D black blood MRI technique for abdominal aorta wall/ILT imaging that has high isotropic resolution, good blood suppression, and a clinically acceptable scan time. We found that DANTE preparation substantially reduced flow artifacts in SPACE, which was particularly usefully in patients with AAAs. DANTE-SPACE showed higher wall/ILT to lumen CNR in patients compared with SPACE, resulting in much clearer

delineation of the boundaries of aneurysms. ILT was clearly visualized and the signal characters can be quantified. To our knowledge, this is the first study evaluating 3D black blood techniques in patients with AAA diseases.

SPACE is a preferred 3D black blood technique for aorta wall imaging due to its high scan efficiency and intrinsic black blood effect [9] [10]. The intrinsic blood suppression ability of SPACE is as a result of the intravoxel dephasing of moving spins during the long echo train [8], and such effects are enhanced when the frequency encoding direction is parallel to the flow. Therefore, the 3D slab of SPACE was commonly placed in either the coronal or sagittal plane with frequency encoding in the head to feet direction. This also enabled a large longitudinal coverage of the aorta, which was advantageous over 2D axial scans. Despite these advantageous features, the suppression of signal from blood in the presence of complex flow may still be insufficient using SPACE [9].

Mihai et al. successfully used SPACE for whole body black blood imaging in healthy volunteers with a total scan time of around one hour [9]. Incomplete blood suppression was commonly found at the carotid bifurcation but only occasionally in the aorta. This is likely related to the geometry of the carotid bifurcation that is known to induce flow recirculation in the healthy bulb [18] while the flow within healthy aortas is mostly regular.

Similarly, flow artifacts observed in volunteers in this study were rare. However, we found much more severe flow artifacts in AAAs compared with healthy aortas, which we attribute to the complex flow within the aneurysm induced by its specific geometry. The severe flow artifacts in SPACE made it difficult to delineate aneurysm wall and ILT and present a challenge for clinical interpretation. In such cases, DANTE preparation proved to be particularly useful in reducing flow artifacts in AAAs, as proved by quantitative lumen SNR measurements and qualitative image scores. Strong suppression of blood signal on DANTE-SPACE provides improved confidence in the measurement of aneurysm dimension and characterization of ILT.

To achieve effective blood suppression in patients, the DANTE module used in this study was relatively strong (a big flip angle of  $15^\circ$  was used). Excellent blood suppression was observed across volunteers and patients, except that moderate flow artifacts were found in one patient with a 5.3cm AAA (Figure 5). However, even in this case, the artifacts did not obscure the boundaries of the aneurysm wall. The flexibility of DANTE preparation permits adjustments that can improve blood suppression, i.e., by increasing the DANTE train length, increasing the RF flip angles or reducing the gap between RF pulses.

A drawback of DANTE preparation is the signal reduction of the static tissues. The wall SNR was decreased by 42.2% in volunteers and wall/ILT SNR was decreased by 20% in patients. The decrease of wall/ILT SNR can be attributed to two reasons: the additional  $T_1/T_2$  weightings induced by DANTE and the signal loss resulting from the pulsatile motion of the wall/ILT [13]. The observation that wall/ILT SNR loss was greater in volunteers than in patients could be explained by the fact that healthy aorta walls have greater compliance than those in patients with AAA disease who have stiffer aortas [19]. As



the flow artifact is less severe in healthy volunteers, a weaker DANTE module may be sufficient when scanning those populations, thereby minimizing the wall SNR loss.

Although the wall/ILT SNR was reduced by DANTE preparation, the wall/ILT to lumen CNR was significantly increased in patients and remained equivalent in volunteers compared with SPACE. The ability of DANTE to improve visualization of the aneurysm wall/ILT contrast was clearly demonstrated.

When applying such techniques in a clinical setting, scan time is a major concern. Previous SPACE studies of the aorta wall in volunteers had a scan time of around 22 minutes [9] [10], which is poorly tolerated by the patient group with AAA disease, who are generally >65 years old. In this study, we reduced the scan time to 7.6 minutes on average by increasing the ETL to 60, which is substantially longer than in previous T<sub>1</sub> weighted SPACE protocols in the aorta (ETL ranged from 19 to 45) [9] [10], however, it was comparable with the ETL used in proton-density weighted intracranial vessel wall imaging (ETL = 58) [20]. To minimize blurring, a short echo spacing was used. As a result, no significant blurring was observed. The reduced scan time made this method a viable tool for clinical scanning of AAA disease. Quite recently, Mooiweer et al propose a 3D gradient echo sequence with 2D spatially selective excitation for imaging descending aorta within 5 minutes with a 1.5mm isotropic resolution [21]. Black blood contrast was obtained by partially inverting the blood's magnetization in the heart at the start of the cardiac cycle. However, this technique has only been tested in healthy volunteers, and its ability to suppress complex flow with in AAA need to be demonstrated in the future.

Artifacts induced by breathing motion are commonly observed in abdominal imaging. While navigators can be used to synchronize acquisition to breathing patterns and are essential in 3D imaging of the heart or aortic arch, those techniques typically have a scan time penalty of a factor of three or more. Since the abdominal aorta itself moves little we used a para-coronal slab through the abdominal aorta, thereby excluding the principle source of motion artifact, the anterior aspect of the belly, from the imaging volume and obviating the need for navigators. In order to smooth out motion artifacts and increase the SNR, a 3.4 signal averaging scheme was used.

Since the degree of compliance of the aorta is substantially reduced in AAA disease, we did not apply electrocardiogram (ECG) gating. Furthermore, it has been shown that the pulsatile motion of the aorta aneurysm is of the order of 1 mm [22], which is below the resolution of this study.

Fresh thrombus within the AAA wall has been suggested to be a risk factor for more rapid AAA progression [5]. In this study, T<sub>1</sub>w DANTE-SPACE demonstrated its ability in quantifying ILT signal intensity and heterogeneity. Compared with previous techniques for imaging AAA thrombus, DANTE-SPACE had a higher isotropic resolution, which is favorable for accurate thrombus volume/signal intensity quantification. A limitation of this study is the lack of histological validation. Future histological studies should be performed to confirm such findings.



CT angiography (CTA) is considered the gold standard for AAA dimension measurements given its high isotropic resolution and excellent image quality. However, CTA fails to identify different thrombus components within the aneurysm, is associated with radiation exposure which makes it not an ideal tool for serial monitoring, and requires the injection of iodinated contrast agents. The advantage of the proposed technique over CTA is that it is totally non-invasive and can differentiate between different thrombus components. The non-invasiveness is perfect for monitoring patient with small AAAs. One AAA patient who was scanned by both DANTE-SPACE MRI and CTA (within 45 days interval) is shown in Figure 8. Different ILT components are shown clearly in MRI images with heterogeneous signal intensity, while ILT signal is homogenous in CTA images. Nevertheless, the accuracy of DANTE-SPACE in measuring AAA dimensions needs to be validated against CTA in the future.

## Conclusion

This study optimizes a high resolution, 3D MRI technique for AAA imaging using a preparation pulse (DANTE) to suppress blood signal in a clinically acceptable scan time. The DANTE preparation module substantially reduces flow artifacts that are otherwise noted on SPACE in patients with AAAs, and increases the wall/ILT to lumen CNR. DANTE-SPACE shows promise as a non-invasive tool for AAA size measurement and its feasibility to differentiate ILT components is demonstrated. These methods may potentially improve patient-specific risk stratification.

## Acknowledgments

This study is supported by NIH grants R01HL114118, R01NS059944 and R01HL123759.

## List of abbreviations

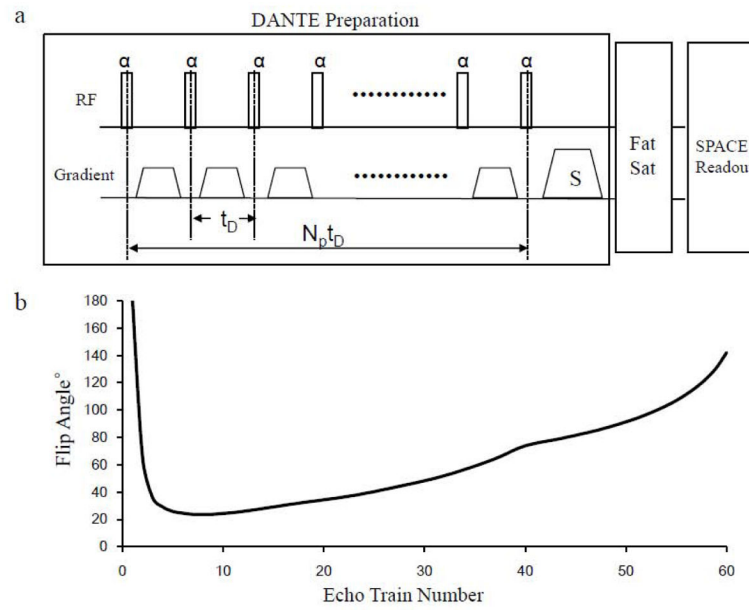
<b>ILT</b>	intraluminal thrombus
<b>AAA</b>	abdominal aortic aneurysms
<b>SNR</b>	signal to noise ratio
<b>CNR</b>	contrast to noise ratio
<b>SD</b>	standard deviation
<b>US</b>	ultrasound
<b>2D</b>	two-dimensional
<b>3D</b>	three-dimensional
<b>CT</b>	computed Tomography
<b>FSE</b>	fast-spin-echo
<b>FSD</b>	flow-sensitive dephasing
<b>DANTE</b>	elay Alternating with Nutation for Tailored Excitation

<b>ETL</b>	echo train length
<b>IQR</b>	inter-quartile range
<b>ECG</b>	electrocardiogram
<b>CTA</b>	computed tomography angiography

## References

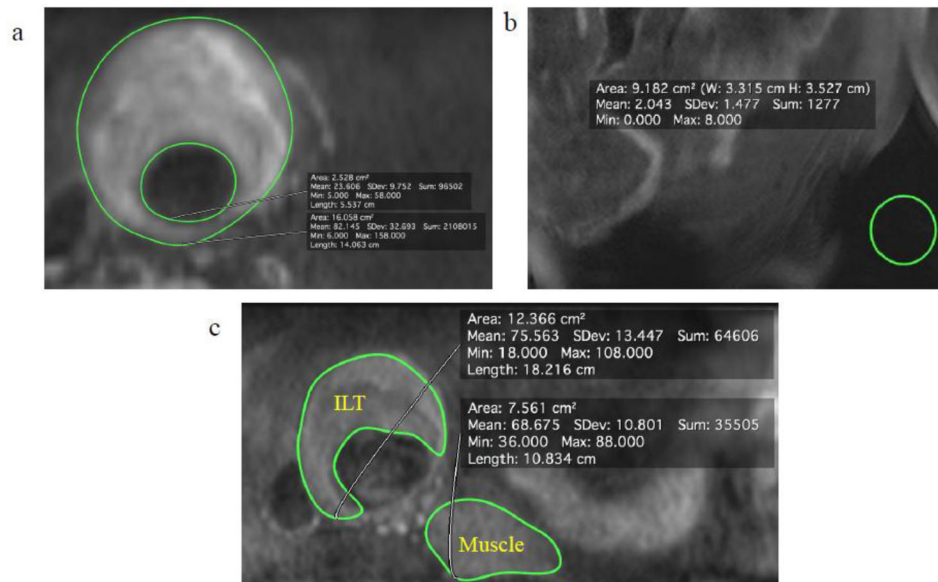
- Lederle FA, Wilson SE, Johnson GR, Reinke DB, Littooy FN, Acher CW, Ballard DJ, Messina LM, Gordon IL, Chute EP, et al. Immediate repair compared with surveillance of small abdominal aortic aneurysms. *N Engl J Med.* 2002; 346:1437–1444. [PubMed: 12000813]
- Brewster DC, Cronenwett JL, Hallett JW Jr, Johnston KW, Krupski WC, Matsumura JS. Guidelines for the treatment of abdominal aortic aneurysms. Report of a subcommittee of the Joint Council of the American Association for Vascular Surgery and Society for Vascular Surgery. *J Vasc Surg.* 2003; 37:1106–1117. [PubMed: 12756363]
- Hope TA, Hope MD. Improved risk assessment for abdominal aortic aneurysm rupture: off-the-wall imaging. *J Am Coll Cardiol.* 2011; 58:2531–2532. [PubMed: 22133854]
- Screening for abdominal aortic aneurysm: recommendation statement. *Ann Intern Med.* 2005; 142:198–202. [PubMed: 15684208]
- Nguyen VL, Leiner T, Hellenthal FA, Backes WH, Wishaupt MC, van der Geest RJ, Heeneman S, Kooi ME, Schurink GW. Abdominal Aortic Aneurysms with High Thrombus Signal Intensity on Magnetic Resonance Imaging are Associated with High Growth Rate. *Eur J Vasc Endovasc Surg.* 2014
- Richards JM, Semple SI, MacGillivray TJ, Gray C, Langrish JP, Williams M, Dweck M, Wallace W, McKillop G, Chalmers RT, et al. Abdominal aortic aneurysm growth predicted by uptake of ultrasmall superparamagnetic particles of iron oxide: a pilot study. *Circ Cardiovasc Imaging.* 2011; 4:274–281. [PubMed: 21304070]
- Busse RF, Brau AC, Vu A, Michelich CR, Bayram E, Kijowski R, Reeder SB, Rowley HA. Effects of refocusing flip angle modulation and view ordering in 3D fast spin echo. *Magn Reson Med.* 2008; 60:640–649. [PubMed: 18727082]
- Jara H, Yu BC, Caruthers SD, Melhem ER, Yucel EK. Voxel sensitivity function description of flow-induced signal loss in MR imaging: implications for black-blood MR angiography with turbo spin-echo sequences. *Magn Reson Med.* 1999; 41:575–590. [PubMed: 10204883]
- Mihai G, Chung YC, Merchant A, Simonetti OP, Rajagopalan S. T1-weighted-SPACE dark blood whole body magnetic resonance angiography (DB-WBMRA): initial experience. *J Magn Reson Imaging.* 2010; 31:502–509. [PubMed: 20099365]
- Mihai G, Varghese J, Lu B, Zhu H, Simonetti OP, Rajagopalan S. Reproducibility of thoracic and abdominal aortic wall measurements with three-dimensional, variable flip angle (SPACE) MRI. *J Magn Reson Imaging.* 2013
- Wong SK, Mobolaji-Iawal M, Arama L, Cambe J, Biso S, Alie N, Fayad ZA, Mani V. Atherosclerosis imaging using 3D black blood TSE SPACE vs 2D TSE. *World J Radiol.* 2014; 6:192–202. [PubMed: 24876923]
- Fan Z, Zhang Z, Chung YC, Weale P, Zuehlsdorff S, Carr J, Li D. Carotid arterial wall MRI at 3T using 3D variable-flip-angle turbo spin-echo (TSE) with flow-sensitive dephasing (FSD). *J Magn Reson Imaging.* 2010; 31:645–654. [PubMed: 20187208]
- Li L, Miller KL, Jezzard P. DANTE-prepared pulse trains: A novel approach to motion-sensitized and motion-suppressed quantitative magnetic resonance imaging. *Magn Reson Med.* 2012; 68:1423–1438. [PubMed: 22246917]
- Zhu C, Patterson A, Graves M, Gillard J. 2D and 3D multi-contrast black blood carotid vessel wall imaging applying DANTE preparation. *Proc Intl Soc Mag Reson Med.* 2014; 22:2538.

15. Behr-Rasmussen C, Grondal N, Bramsen MB, Thomsen MD, Lindholt JS. Mural thrombus and the progression of abdominal aortic aneurysms: a large population-based prospective cohort study. *Eur J Vasc Endovasc Surg.* 2014; 48:301–307. [PubMed: 24969094]
16. Mugler JP 3rd. Optimized three-dimensional fast-spin-echo MRI. *J Magn Reson Imaging.* 2014; 39:745–767. [PubMed: 24399498]
17. Li L, Chai JT, Biasioli L, Robson MD, Choudhury RP, Handa AI, Near J, Jezzard P. Black-Blood Multicontrast Imaging of Carotid Arteries with DANTE-prepared 2D and 3D MR Imaging. *Radiology.* 2014:131717.
18. Antiga L, Wasserman BA, Steinman DA. On the overestimation of early wall thickening at the carotid bulb by black blood MRI, with implications for coronary and vulnerable plaque imaging. *Magn Reson Med.* 2008; 60:1020–1028. [PubMed: 18956420]
19. Cavalcante JL, Lima JA, Redheuil A, Al-Mallah MH. Aortic stiffness: current understanding and future directions. *J Am Coll Cardiol.* 2011; 57:1511–1522. [PubMed: 21453829]
20. Qiao Y, Steinman DA, Qin Q, Etesami M, Schar M, Astor BC, Wasserman BA. Intracranial arterial wall imaging using three-dimensional high isotropic resolution black blood MRI at 3.0 Tesla. *J Magn Reson Imaging.* 2011; 34:22–30. [PubMed: 21698704]
21. Mooiweer R, Sbrizzi A, El Aidi H, Eikendal AL, Raaijmakers A, Visser F, van den Berg CA, Leiner T, Luijten PR, Hoogduin H. Fast 3D isotropic imaging of the aortic vessel wall by application of 2D spatially selective excitation and a new way of inversion recovery for black blood imaging. *Magn Reson Med.* 2015
22. Malina M, Lanne T, Ivancev K, Lindblad B, Brunkwall J. Reduced pulsatile wall motion of abdominal aortic aneurysms after endovascular repair. *J Vasc Surg.* 1998; 27:624–631. [PubMed: 9576074]

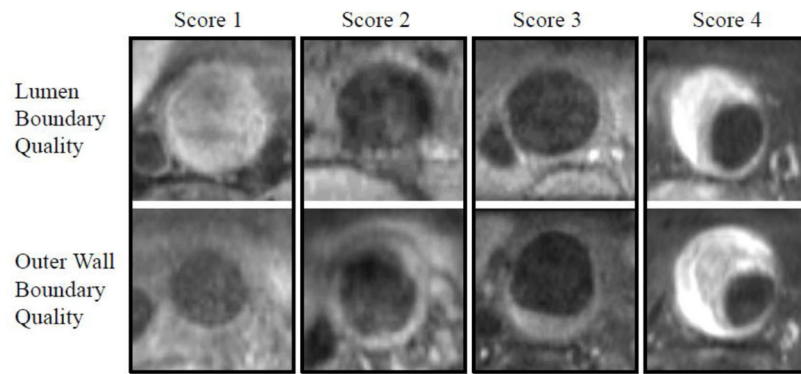


**Figure 1.**

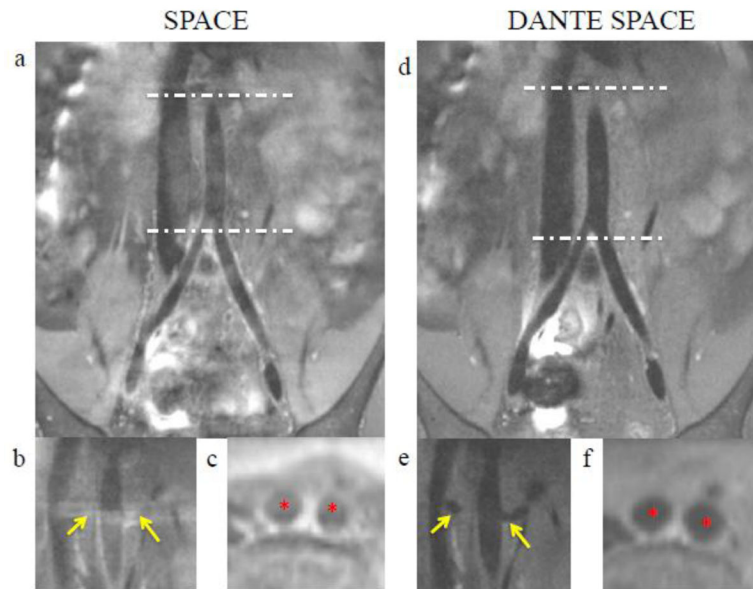
(a) Pulse sequence diagram of DANTE prepared SPACE sequence with fat saturation.  $t_D$ : gap between RF pulses;  $N_p$ : number of RF pulse in DANTE; S: spoiler gradient after DANTE preparation. (b) Variable-flip-angle refocusing trains used for SPACE acquisitions.



**Figure 2.** Region of interests (ROIs) segmentation. (a) Segmentation of the lumen and outer wall contours of AAA. (b) Noise measurement in the background noise-free region. (c) Quantification of intraluminal thrombus (ILT) and psoas muscle signal intensity.

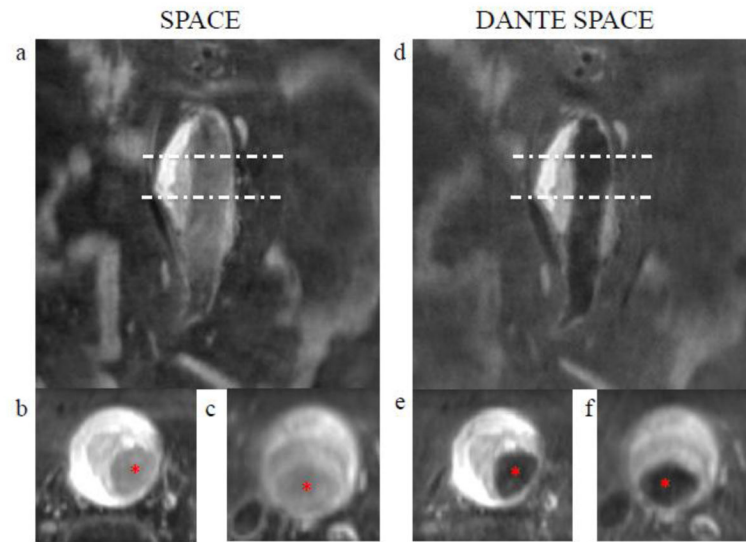


**Figure 3.** Representative images of AAA patients with image quality score 1–4.

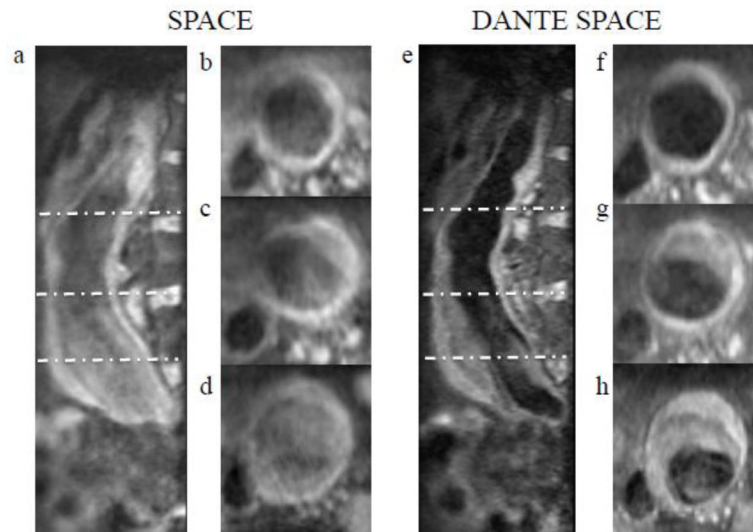


**Figure 4.** SPACE (left) and DANTE-SPACE (right) images in a volunteer. (a, d): Images in originally acquired coronal plane. (b, e): Reformatted oblique coronal images at renal bifurcation. (c, f): Reformatted axial images at aorta bifurcation. Arrows show the renal artery and stars show the iliac lumen.

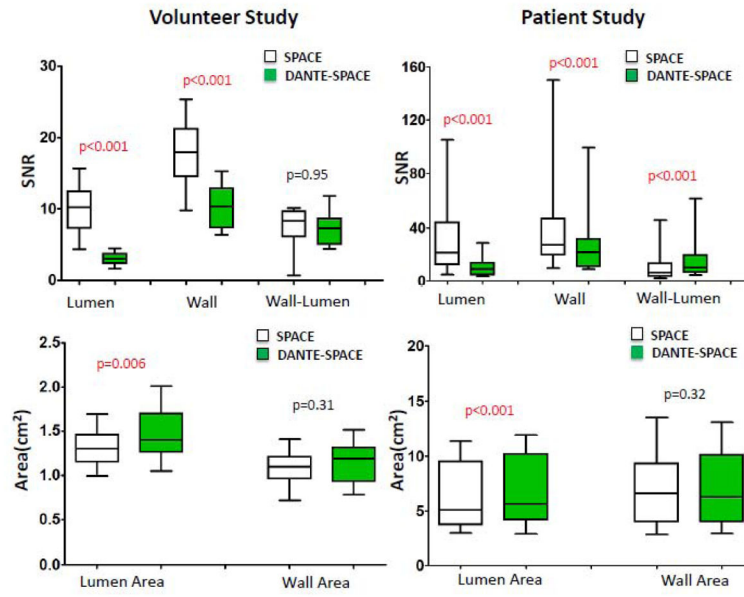




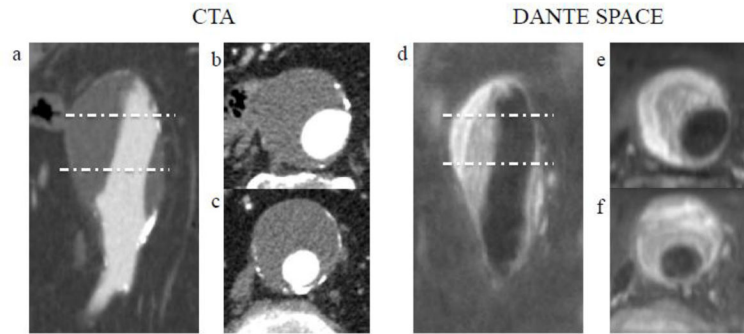
**Figure 5.** SPACE (left) and DANTE-SPACE (right) images in a patient with a 4.9cm AAA. (a, d): Images in originally acquired coronal plane. (b-c, e-f): Reformatted axial images at different levels of the aneurysm. Stars show the aorta lumen. Intraluminal thrombus with high signal intensity is clearly shown, with  $ILT_{SI}/Muscle_{SI}$  of 2.0 and SD/mean of 21.6%.



**Figure 6.** SPACE (left) and DANTE-SPACE (right) images in a patient with a 5.3cm AAA. (a, e): Images in reformatted sagittal plane. (b-d, f-h): Reformatted axial images at different levels of the aneurysm. In DANTE-SPACE, moderate flow artifacts were observed at the bottom of the aneurysm (h). Intraluminal thrombus with iso-intense/hypo-intense signal is shown, with  $ILT_{SI}/Muscle_{SI}$  of 0.9 and  $SD/mean$  of 23.1%.



**Figure 7.** Box plots of wall and lumen SNR and areas measurements using SPACE and DANTE-SPACE. Median and inter quartile range (within box) and 10th and 90th percentile (between bars) values are given.



**Figure 8.** CTA images (left) and DANTE-SPACE images (right) in an AAA patients with intraluminal thrombus (ILT). Coronal (a, d) and two axial slices (b-c, e-f) at identical locations are shown. ILT signal heterogeneity is noted in DANTE-SPACE images but not in CTA.

**Table 1**

Comparison of the SNR/CNR and areas measurements between SPACE and DANTE-SPACE.

		SPACE Median [IQR]	DANTE-SPACE Median [IQR]	p
Volunteer Study	Lumen SNR	10.3 [8.0, 11.5]	3.0 [2.4, 3.6]	<0.001
	Wall SNR	18.0 [15.9, 20.6]	10.4 [8.0, 12.1]	<0.001
	Wall-lumen CNR	8.3 [6.5, 9.6]	7.3 [5.6,7.7]	0.95
	Lumen Area (cm <sup>2</sup> )	1.3 [1.2,1.4]	1.4 [1.3,1.6]	0.006
	Wall Area (cm <sup>2</sup> )	1.1 [1.0,1.2]	1.2 [1.0,1.3]	0.31
Patient Study	Lumen SNR	21.4 [12.6, 43.8]	8.8 [4.5, 13.6]	<0.001
	Wall/ILT SNR	27.0 [19.6, 46.8]	21.6 [10.7, 31.2]	<0.001
	Wall/ILT-lumen CNR	6.3 [3.3, 13.2]	9.9 [6.4, 19.3]	<0.001
	Lumen Area (cm <sup>2</sup> )	5.1 [3.7, 9.3]	5.6 [4.2, 10.1]	<0.001
	Wall/ILT Area (cm <sup>2</sup> )	6.6 [4.0, 9.3]	6.3 [4.0, 10.0]	0.32

**Table 2**

Comparison of the qualitative image scores of SPACE and DANTE-SPACE in patients.

		SPACE	DANTE-SPACE	p
Lumen Boundary Quality	Reader 1	1.4±0.7	2.7±0.7	0.01
	Reader 2	1.5±0.5	2.3±0.5	0.01
Outer Wall Boundary Quality	Reader 1	2.2±0.4	2.4±1.0	0.48
	Reader 2	2.1±0.7	2.3±0.5	0.17

Author Manuscript

Author Manuscript

Author Manuscript

Author Manuscript