

# Hujin Pill's antisteatosis of rat liver: evaluation of histopathology and ultrastructure \*

HUANG Zhao-Sheng, WANG Zong-Wei, HUANG Zhen-Yan, ZHONG Shi-Qing, LI Qiao-Mei and XU Qin

**Subject headings** Hujin pills; fatty liver/ pathology; disease models, animal

## INTRODUCTION

Hujin Pill, is composed of *rhizoma polygoni cuspidati*, *radix curcumae*, *rhizoma alismatis*, *radix notoginseng*, *fructus czataegi* and *ganoderma lucidum*, and has the actions of soothing the liver, removing the blood stasis, promoting the blood circulation and lowering the blood-fat<sup>[1]</sup>. Our clinical practice have revealed that it has a marked effect in treating fatty liver<sup>[1]</sup>. Our pharmacodynamic study also indicated that Hujin Pill could evidently improve the experimental rat fatty liver and markedly decrease the concentration of cholesterol, triglyceride and malondialdehyde in serum and liver, it also could reduce the plasma medium molecular level<sup>[2]</sup>. In order to further testify these effects and investigate its mechanism, the effects of Hujin Pill on the histomorphology of rat fatty liver were observed.

## MATERIALS AND METHODS

### Animals

SD rats, female, 200 g ± 18.5 g, were supplied by the Experimental Animal Center of Guangzhou University of Traditional Chinese Medicine. According to their body weight, the 50 experimental rats were divided randomly into control group A, pathology group B, tabellae jiaogulosidi treatment group C, low dose Hujin Pill group D (5g/kg body weight) and high dose Hujin Pill group E (4g/kg body weight).

### Diet

Chojkier's method was slightly modified<sup>[3]</sup>. This high fat diet was composed of 79.5% standard diet,

20% lard, 0.4% cholesterol and 0.1% bile salt. The control group was fed with standard diet and others with high fat diet.

### Drugs

According to the ratio of the formula, the herbs were decocted and filtered for three times, then merged and condensed to a concentration of 1g/mL. Before reuse, it was diluted to 0.5g/mL or concentrated to 1.4g/mL. Tabellae jiaogulosidi (No. 960738), provided by Shaanxi Ankang Chinese Pharmaceutical Factory, was administered at a dose of 0.5g/kg body weight (BW).

### Animal model duplication

The animals were given 30% ethanol at a dose of 1.0mL/100g BW per day except the control group, 40% CCl<sub>4</sub> vegetableoil solution was given to posterior limb by subcutaneous injection of each rat on the 1st, 5th, 10th and 15th day. On the first day, the dose was 0.5 mL/100 g BW, and was 0.3mL/100g BW on the other three days. The rats were treated with different drugs at a dose of 1mL/100g BW each day 2 hours before ethanol was given. At the same time, the control group was given (*i.g. s.c*) the same dose of physiological saline solution.

### Sample preparation

The rats were killed after 15 days of treatment and their livers were taken out and weighed. The left liver lobe was cut into 4mm<sup>3</sup> - 5mm<sup>3</sup> masses and fixed in 200mL/L formaldehyde solution, the paraffin masses were embedded routinely, HE stained, frozen and sectioned. The samples were stained with Sudan III and observed under light microscope. On the other hand, the central part of another liver lobe was cut into 1mm<sup>3</sup> masses and fixed in 25mL/L glutaraldehyde and 10mL/L OsO<sub>4</sub>. After they were rinsed and dehydrated step by step, osmosis and embedding were conducted. The Ultracut-E microtome was used to cut these liver masses into sections, which were stained in uranium acetate and lead citrate and observed under JEM-1200EX electron microscope.

## RESULTS

### Macroscopy

The livers of control group had no abnormal

Guangzhou University of Traditional Chinese Medicine (TCM), College of Chinese Herbal Drugs, Guangzhou 510407, China

Professor HUANG Zhao-Sheng, male, born on 1953-09-02 in Jieyang City, Guangdong Province, and graduated from Guangzhou University of TCM as a postgraduate in 1984, master of Chinese Herbal Drugs, now head of the College of Chinese Herbal Drugs, Guangzhou University of TCM, having more than 30 papers and 10 books published.

\*Supported by the State Administration Bureau of TCM, No. 97A06.

Correspondence to: HUANG Zhao-Sheng, College of Chinese Herbal Drugs, Guangzhou University of TCM, 12 Jichang Road, Guangzhou 510407, Guangdong Province, China

Tel. +86-20-86591233 Ext. 2425

Received 1999-01-09

manifestation. However, the pathological model of livers changed evidently. It could be seen that both their volume and weight increased remarkably (Table 1), their capsules were tense, their edges were obtuse, their sections were greasy and milk-yellow. These were the typical features of hepatocyte steatosis. On the other hand, different doses of Hujin Pill and tabelae jiaogulosidi could markedly improve the color, quality, volume and weight of rat livers.

**Table 1** The comparison of liver weight of rats after experiment ( $\bar{x}\pm s$ )

Group	Number of rats	Liver weight (g)
A	10	6.34±0.77 <sup>b</sup>
B	8	10.01±1.03
C	9	8.12±0.90 <sup>a</sup>
D	10	7.93±0.91 <sup>a</sup>
E	10	7.46±1.28 <sup>b</sup>

Compared with group B, <sup>a</sup> $P<0.01$ , <sup>b</sup> $P<0.001$ .

#### Light microscopy

No abnormal change was found in the livers of control rats, but diffuse steatosis was found in the pathological model of rat livers and some severe cases became involved with inflammatory infiltration, fat necrosis and fibrosis. These fatty hepatocytes were mainly located in the peripheral zone and middle zone of hepatic lobules. They extremely swelled and were round in shape. Their volume was 2 to 3 times larger than normal one. A large amount of little fat vacuoles, which are very like foam cells, were found in cytoplasm and some of them became bullous or locally necrosed. The degree of liver steatosis was significantly alleviated with the number of fat drops decreased and the volume of livers reduced. Other changes such as inflammatory infiltration and fat necrosis were also largely decreased with almost no proliferation of fibrous tissue.

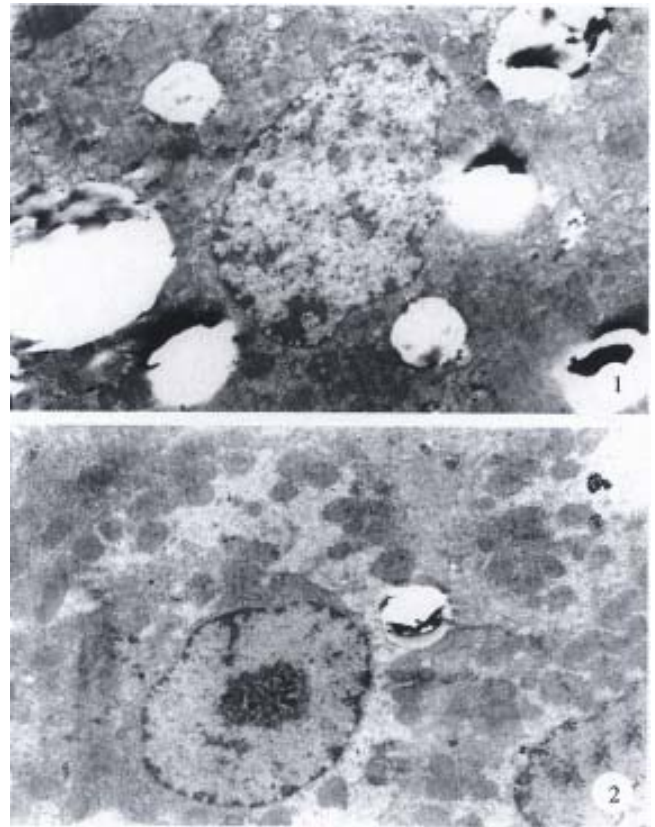
#### Statistical analysis of pathology

According to the range and extent of pathological changes in liver and hepatic lobules, liver steatosis could be divided into five grades. Meanwhile, by using rank test, a statistical analysis was made for the number of rat liver steatosis in each group. The results showed that, compared with control group, significant difference was found in the degree of steatosis in the other four groups. The rate of steatosis was 100%, the serious steatosis rate was 80% in group B, while it was much lower in groups C, D and E. Administration of Hujin Pill at a dose of 5g/kg had the best effect, and no significant difference was found between the two groups. These results suggested that there was no dose-effect relationship for Hujin Pill (Table 2).

**Table 2** The results of liver steatosis in rats of each group

Group	The degree of liver steatosis					Number of liver steatosis	Rate of liver steatosis
	-	+	++	+++	++++		
A	9	1	0	0	0	1	10
B	0	1	1	4	4	10	100
C	4	4	1	0	1	6	60
D	5	2	1	2	0	5	50
E	4	2	0	3	1	6	60

The standard of assessing the degree of hepatocytes steatosis: -, no steatosis; +, the steatosis in hepatic lobules  $<1/3$ ; ++, the steatosis in hepatic lobules was between  $1/3-2/3$ ; +++, the steatosis in hepatic lobules was between  $1/2-2/3$ ; +++++, the steatosis in hepatic lobules  $>2/3$ .



**Figure 1** The ultrastructure of rat hepatocytes in pathology group. The hepatocyte nuclei were crushed by lots of fat drops and became distorted and shrunken. A lot of fat drops were densely accumulated in cytoplasm and the diameter of some single fat drops could reach 4 $\mu$ m. The roughly surfaced endoplasm was broken with distortion, concentration or desalination around mitochondria. HE $\times$ 5000

**Figure 2** The ultrastructure of hepatocytes of rats that administered Hujin Pill at a dose of 5g/kg BW. The fat drops in cytoplasm were largely lessened with insignificantly dilated endoplasm and enlarged mitochondria. Most of the nuclei were regular in shape. The perinuclear space became normal, some of them were slightly shrunken and the chromatin was evenly distributed.

#### Ultrastructural observation

The volume of normal rat hepatocytes was relatively great. These hepatocytes were closely arranged with some desmosomes near the cholangiole. Most of these cells were circular or oval in shape and had monokaryons with reticular or angular 1-3 nucleoli.

There was abundant roughly surfaced endoplasmic reticulum in cytoplasm that was usually distributed near the mitochondrion. However, there was only a small number of smoothly surfaced endoplasmic reticula and ample mitochondria in the cytoplasm, most of which had clear cristae. Meanwhile, a small part of them had high electron densities and indistinct cristae. Occasionally, in cytoplasm, there were a few round or elliptic fat drops which were irregular in tint and their diameter was less than 1 $\mu$ m.

In pathological group, obvious ultrastructure change of hepatocytes was found (Figure 1). A lot of fat drops were densely accumulated in cytoplasm. Most of them were circular in shape and the diameter of some single fat drops could reach 4 $\mu$ m. The roughly surfaced endoplasm was broken, degranulated and dilated into vesicular with distortion, concentration, desalination, swelling and adventitia destruction around mitochondria. Mitochondrial crista was unclear and accompanied by more lysosomes. The nuclei were crushed by lots of fat drops and became distorted and shrunken. The diameter of nucleus was decreased obviously and perinuclear space was large. The sinusoidal endothelial cells obviously swelled with the sinusoid and Diss space became wide, and microvilli were found in some of them. Fat-storing cell and Kupffer cell were obviously hyperplastic. The perinuclear space of Kupffer cell near the sinusoid was obviously broadened. Masses could be found occasionally in the space.

The structure of hepatocytes of rats administered with 5g/kg BW (Figure 2), 14g/kg BW Hujin Pill or tabelle jiaogulosidi, was markedly improved. The best effect was achieved in those that administered Hujin Pill at the dose of 5g/kg BW and the cell ultrastructure almost returned to normal. It also could be observed that the fat drops in cytoplasm were largely lessened with insignificantly dilated endoplasm and enlarged mitochondria. The deletion of mitochondria crista was mild and most of the nuclei were regular in shape. The perinuclear space became normal and some of them were slightly shrunken and the chromatin was

evenly distributed. Now and then, some fat-storing cells could be found.

## DISCUSSION

Generally, it was considered that CCl<sub>4</sub> in hepatocytes could be activated by liver microsome cytochrome P<sub>450</sub> and turned into CCl<sub>3</sub> which could induce microsome lipid peroxide and cause liver steatosis. In this research, we duplicated rat models of fatty liver with comprehensive pathologic factors. The results confirmed that this method not only is reliable and consistent with that reported in literature<sup>[4]</sup>, but also need shorter time than other methods. On the other hand, the effect of Hujin Pill on steatosis hepatocytes also suggested that this drug could be used in treating fatty liver. Our conclusion was coincided with that of pharmacodynamic study. It provides a further basis for the treatment of fatty liver with Hujin Pill.

The pathogenesis of fatty liver is so far unclear. Some researchers hold that the phospholipid of hepatocyte membrane is involved in its formation. Lu *et al*<sup>[5]</sup> showed that the relative percentage of phosphatidyl choline and sphingomyelin in total phospholipid would change when liver was damaged by CCl<sub>4</sub>. From this point of view, we believe that improvement of steatosis hepatocytes by Hujin Pill can be achieved by means of protecting membrane structure and cell organ stabilizing the content of phospholipid. Its exact mechanism needs to be further studied.

## REFERENCES

- 1 Huang ZS, Xu ZH, Zhong SQ, Xiao XH. Clinic observation of Hujin Pill in treating fatty liver. *Shiyong Zhongxiyi Jiehe Zazhi*, 1997,10: 21-28
- 2 Huang ZS, Wang ZW, Liu MP, Zhou L. Pharmacodynamic study on Hujin Pill in treating fatty liver. *Zhongcheng Yao*, 1998;20:27-28
- 3 Chojkier M, Lyche KD, Filip M. Increased production of collagen *in vivo* by hepatocytes and nonparenchymal cells in rats with CCl<sub>4</sub> induced hepatic fibrosis. *Hepatology*, 1988;8:808-814
- 4 Huang ZP, Liang KH, Wang HJ, Ruan YB. Influence of radix *angelica sinensis* on liver ultrastructure in the rat with chronic CCl<sub>4</sub>-induced liver injury. *Zhongxiyi Jiehe Ganbing Zazhi*, 1996;6:16-17
- 5 Lu LG, Wang ZM, Zhang YX, Zhu QS, You YZ. A study on mechanism of liver lesion induced by carbon tetrachloride in rats. *Zhongxiyi Jiehe Ganbing Zazhi*, 1996;6:24-25

Edited by WANG Xian-Lin