

# Relation between abnormalities in the chest radiograph and changes in pulmonary function in chronic bronchitis and emphysema

G. SIMON, N. B. PRIDE, N. L. JONES, and A. C. RAIMONDI

*Departments of Radiology and Medicine, Hammersmith Hospital, London W.12*

Chest radiographs of 101 patients with chronic airflow obstruction were assessed for evidence of over-inflation (increased retrosternal space, low diaphragm, and increased total lung capacity), pulmonary hypertension (increase in size of heart and major pulmonary vessels) and attenuation of medium-sized pulmonary vessels. The radiological abnormalities were related to the alterations in pulmonary function.

When the position of the diaphragm was low or the retrosternal space was 4.5 cm or more the average FEV<sub>1</sub> was below 1.0 litre, but severe impairment of the FEV<sub>1</sub> could be present when the position and contour of the diaphragm were normal and the retrosternal space was 2.5 cm or less. The radiological method for estimating total lung capacity agreed well with the results obtained with body plethysmography, but there was not a close correlation between the standard radiological signs of over-inflation and a large total lung capacity.

When the radiograph showed widespread vascular attenuation as well as over-inflation the impairment in FEV<sub>1</sub> and other tests of pulmonary function was considerably more severe than when the radiograph showed over-inflation alone. Severe reduction in transfer factor was usually associated with changes in the pulmonary vessels.

It is concluded that the radiological diagnosis of widespread emphysema can be made with confidence only when there is attenuation of pulmonary vessels as well as evidence of over-inflation. In attempting to diagnose emphysema in life all available clinical and functional data should be considered in conjunction with the radiographic appearances.

Potentially radiology offers the simplest and most widely applicable method for diagnosing emphysema in life, but there is controversy about its accuracy and sensitivity. Burrows *et al.* (1966) found they could predict reliably the presence of emphysema in patients with severe airflow obstruction by using a combination of abnormalities in the chest radiograph (areas of attenuation of medium-sized pulmonary arteries) and in pulmonary function (a low transfer factor per litre lung volume and a low PCO<sub>2</sub> in relation to the severity of airways obstruction). In contrast, Sutinen, Christoforidis, Klugh, and Pratt (1965) have claimed that radiological evidence of 'over-inflation' (a low diaphragm and an enlarged retrosternal space) alone is sufficient to diagnose emphysema. In this paper we attempt to assess the functional significance of the radiological signs of over-inflation and vascular attenuation by comparing these signs with the abnormalities in pul-

monary function found in 101 patients with chronic airways obstruction.

## METHODS

**RADIOLOGICAL ASSESSMENT** Standard six-foot postero-anterior and left lateral chest radiographs, taken in the position of full inflation, were assessed by one of us (G.S.), who was not aware of the clinical or functional findings in the patients. Three points were considered in all radiographs:

(1) *Evidence of 'over-inflation'* (a) Position of diaphragm: The diaphragm was recorded as 'low' if the level of the right dome was at the anterior end of the seventh rib or lower. The diaphragm was recorded as 'flat' if the maximum curvature of the right dome was less than 1.5 cm (Simon, 1971).

(b) Size of the retrosternal space: On the lateral radiograph the distance from the posterior aspect of the sternum 3 cm below the sterno-manubrial junction horizontally to the anterior margin of the aorta was measured.

(2) *Evidence of alveolar destruction* The only direct evidence of alveolar destruction is a hypertransradiant area without vessel shadows within it, that is a bulla. This may or may not be demarcated by a white line of indented pleura. Alveolar loss or distension, however, was presumed to be present if there were areas with small or absent vessel shadows. This change in the vessels can be observed objectively if in other parts of the lung there are vessels which are normal or even dilated, which can be used as 'marker vessels' (Simon, 1970). For analysis the lungs were divided into an upper and lower half on each side, and the presence or absence of vessel narrowing or loss was recorded for each zone.

(3) *Evidence of pulmonary artery hypertension* Heart size was regarded as abnormal if its transverse diameter was outside the range 11.5–14.0 cm. The main pulmonary artery was considered to be definitely enlarged if its maximum curvature projected more than 0.5 cm from a line joining the points where the shadow meets the aorta above and the left heart border below. Hilar pulmonary arteries (right and left descending) were regarded as enlarged if their transverse diameter in the postero-anterior radiograph was greater than 14 mm.

On the basis of these observations, an opinion was then offered as to the presence of emphysema and pulmonary hypertension. Emphysema was diagnosed if there were localized zones of narrowing of pulmonary vessels in association with evidence of 'over-inflation' (low and flat diaphragm, large retrosternal space). Over-inflation was not regarded as indicating emphysema if the pulmonary vessels were normal. Emphysema was recorded as 'limited' if the vessels were narrowed in only one or two zones, 'widespread' if three or four zones were involved. Pulmonary hypertension was diagnosed if the transverse diameter of the heart was greater than 14 cm and the main and hilar pulmonary arteries were enlarged; if, however, widespread emphysema was diagnosed (as outlined above) then pulmonary hypertension was regarded as being present if there was increase in size of the main and hilar pulmonary arteries, even without enlargement of the heart.

In 28 of the patients lung volume was measured from the chest radiograph, using the modification of the Barnhard method (Barnhard, Pierce, Joyce, and Bates, 1960) introduced by Loyd, String, and DuBois (1966). In this method the shape of the lung is simplified into a number of ellipsoids the volumes of which are measured.

**PULMONARY FUNCTION TESTS** The forced expiratory volume in one second ( $FEV_1$ ) and vital capacity (VC) were each taken as the greatest of three measurements using a dry spirometer. The mixed venous carbon dioxide pressure ( $P\bar{v}, CO_2$ ) was obtained by the re-breathing method of Campbell and Howell (1962). The expected value of  $P\bar{v}, CO_2$  was calculated from the equation derived by Burrows, Strauss, and Niden (1965):

$$P\bar{v}, CO_2 \text{ (mmHg)} = \frac{11.5}{FEV_1 \text{ (litres)}} + 36.7 \text{ (SE}=6.1)$$

The transfer factor was measured by the single-breath method of Ogilvie, Forster, Blakemore, and Morton (1957) and expressed per litre of lung volume (TF/VA). In calculating this ratio lung volume was expressed at STPD; the mean of two tests was taken. Total lung capacity (TLC) was measured by the body plethysmograph technique (DuBois *et al.*, 1956), the patient inspiring to full inflation from a spirometer immediately after thoracic gas volume was measured by panting against a closed shutter. The result recorded was the mean of three measurements. Residual volume (RV) was obtained by subtracting VC from TLC. Normal values for TLC were predicted from the formulae of Goldman and Becklake (1959). Specific airways conductance (SGaw), a measure of airway narrowing which allows for differences in lung size and volume (Guyatt, Alpers, Hill, and Bramley, 1967), was also measured at resting lung volume in the body plethysmograph. Again the mean of three measurements was recorded.

The measurements of  $FEV_1$ , VC, and  $P\bar{v}, CO_2$  were made on the day the chest radiograph was obtained, but transfer factor and body plethysmograph measurements were often made at a different visit, which was four months before or after the other data were obtained. Full data were not obtained in all patients. In the subgroup of patients in whom the TLC was assessed by the radiological method and by the body plethysmograph method both measurements were taken on the same day.

**PATIENTS STUDIED** One hundred and one men attending the Bronchitis Clinic at Hammersmith Hospital were studied. All had had chronic expectoration for at least two years and this was not attributable to localized lung disease. At the time of entry to the Clinic all patients had an  $FEV_1$  of 60% or less of predicted normal values (Cotes, 1968) and an  $FEV_1/VC$  % of 60 or less. Patients with marked variability of symptoms or with seasonal or allergic features suggestive of asthma were excluded.

## RESULTS

**OVERALL RADIOLOGICAL ASSESSMENT** Of the 101 patients, 15 were judged to show radiological evidence of widespread emphysema, and 24 evidence of emphysema limited to one or two zones. Of the remaining 62 patients, 8 had a low position of the diaphragm, 11 had a retrosternal space of 4.0 cm or more, and another 19 had a retrosternal space of 3.0 or 3.5 cm.

## RELATION OF SIGNS OF 'OVER-INFLATION' TO FUNCTIONAL ABNORMALITIES

*Position and contour of diaphragm* When the diaphragm was low, the  $FEV_1$  was usually 1.5 litres or less, regardless of whether the diaphragm

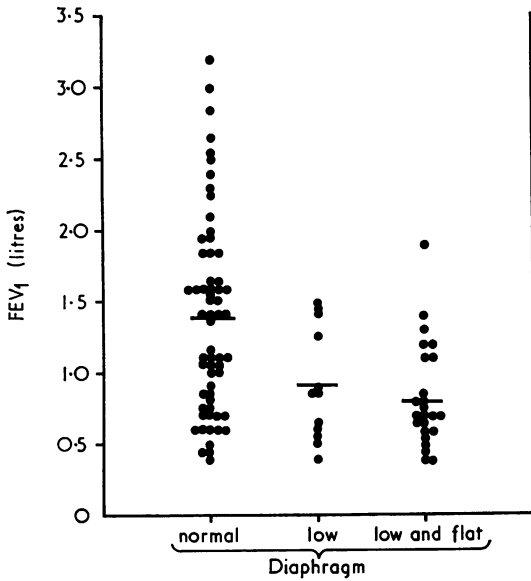


FIG. 1. Relation between FEV<sub>1</sub> and position and contour of the diaphragm. Horizontal lines indicate mean values for each subgroup in this and subsequent figures.

remained curved or not (Fig. 1). Many patients with severe airflow obstruction had a normal position and contour of the diaphragm. There was a tendency for a low and flat diaphragm to be associated with a large TLC (Fig. 2) but again this was not invariably the case; furthermore, a large

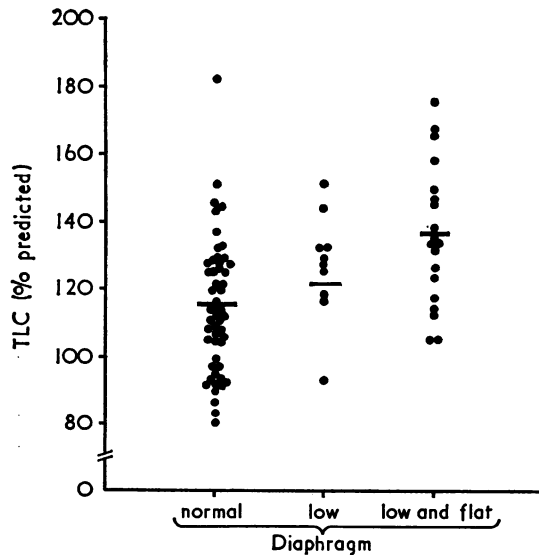


FIG. 2. Relation between TLC (expressed as percentage predicted value) and position and contour of the diaphragm.

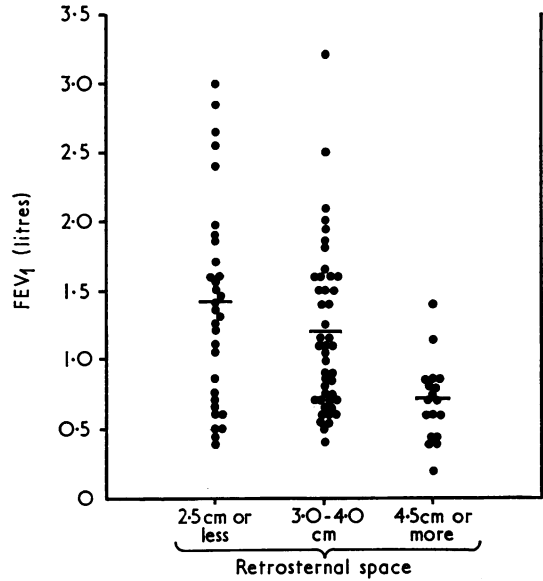


FIG. 3. Relation between FEV<sub>1</sub> and the size of the retrosternal space.

TLC could be present without the diaphragm being abnormally low.

**Size of retrosternal space** When the retrosternal space was 4.5 cm or more there was a striking predominance of patients with severe airflow obstruction (Fig. 3); but a normal retrosternal

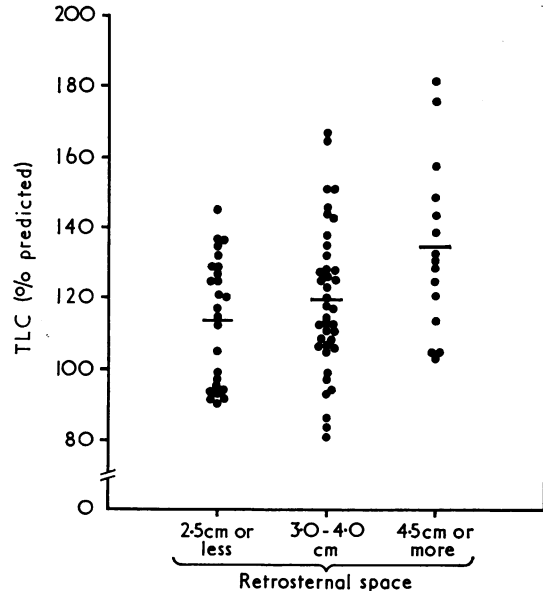


FIG. 4. Relation between TLC (expressed as percentage predicted value) and the size of the retrosternal space.

space did not exclude the presence of severe airways obstruction. Conversely, a space in the range 3.0–4.0 cm was present in some of the patients with relatively mild impairment of the  $FEV_{1.0}$ . When TLC was above 140% of the predicted value the retrosternal space was usually at least 3 cm (Fig. 4).

**RELATION OF RADIOGRAPHIC ABNORMALITIES TO PRESENCE OF AIRWAYS OBSTRUCTION** For this comparison the radiographs were divided into four groups—normal, over-inflation, limited emphysema, and widespread emphysema. A radiograph was accepted as normal if there was a normal position of the diaphragm, no changes in the vessels, and the retrosternal space was 3.5 cm or less. Over-inflation was diagnosed if the position of the diaphragm was low and/or the retrosternal space was 4.0 cm or more and there were no

associated vessel changes. The position of the diaphragm was low in all the radiographs assessed as showing widespread emphysema (vessel changes in three or four zones) but the size of the retrosternal space varied from 2.5 to 6.0 cm. The  $FEV_1$  tended to be lower in the patients whose radiographs showed limited or widespread emphysema than in those whose radiographs were considered to be normal or to show over-inflation (Fig. 5, Table). All the patients whose radiographs showed widespread emphysema had an  $FEV_1$  of 1.25 litres or less, but a substantial proportion of the patients with severe airflow obstruction were not judged to show any radiological abnormality.

All the patients with radiological evidence of widespread emphysema had abnormalities of other tests of airflow obstruction ( $FEV_1/VC$  % of 45 or less,  $RV/TLC$  % more than 50, and  $SGaw$  less than 0.13 l/sec per cm  $H_2O$  per litre); in general, the results of these tests paralleled those for the  $FEV_1$  and they will not be further considered.

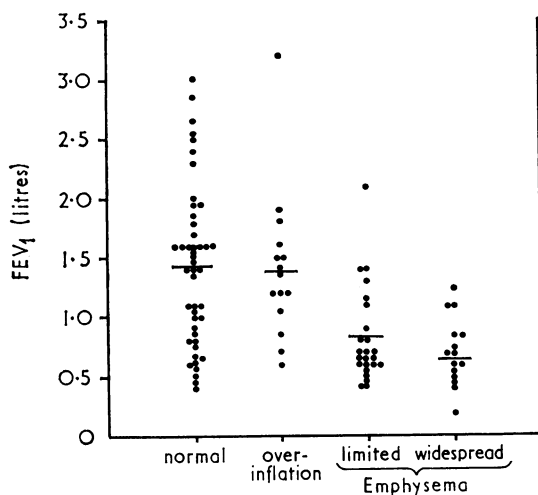


FIG. 5. Relation between  $FEV_1$  and the radiographic abnormalities. See text for criteria for subgroups.

**RELATION OF RADIOGRAPHIC ABNORMALITIES TO FUNCTIONAL ABNORMALITIES WHICH PREDICT EMPHYSEMA** We assessed the relation of radiographic abnormalities (grouped as for the comparison with  $FEV_1$  above) to changes in the three lung function tests which are thought to be useful in diagnosing emphysema ( $TF/VA$ , deviation from predicted  $Pco_2$ , TLC as % of predicted value) (see Table). This comparison was confined to patients whose  $FEV_1$  was less than 1.5 litres, since differences in lung function between the emphysematous and bronchial types of airways obstruction only become manifest when obstruction is severe. Of 74 patients available for this comparison, 15 were judged to have widespread and 23 to have limited emphysema on the chest radiograph. Measurements of TLC were available in only 58 of these patients; these omissions occurred either because the patients could not perform the panting manoeuvre required or be-

TABLE  
RELATION BETWEEN MEAN RESULTS OF PULMONARY FUNCTION TESTS AND ABNORMALITIES IN THE CHEST RADIOGRAPH

	Normal			Overinflation			Limited Emphysema			Widespread Emphysema		
	No.	Mean	SD	No.	Mean	SD	No.	Mean	SD	No.	Mean	SD
$FEV_1$ (litres) . . . . .	47	1.43	(±0.67)	15	1.37	(±0.64)	24	0.83	(±0.40)	15	0.71	(±0.29)
Transfer factor per litre lung volume <sup>1</sup> (ml/min/mmHg/litre) . . . . .	25	4.37	(±1.27)	11	3.30	(±1.32)	23	2.98	(±1.32)	15	2.29	(±1.53)
Total lung capacity <sup>1</sup> (% predicted value) . .	20	111.9	(±18.8)	8	133.2	(±28.0)	19	126.4	(±15.0)	11	141.7	(±17.7)
Deviation from predicted $Pco_2$ <sup>1</sup> (mmHg) . .	25	+1.6	(± 7.1)	11	-0.3	(± 6.7)	23	-2.7	(± 7.3)	15	-4.2	(± 9.9)

<sup>1</sup> Analysis confined to 74 patients in whom  $FEV_1$  was 1.5 l. or less

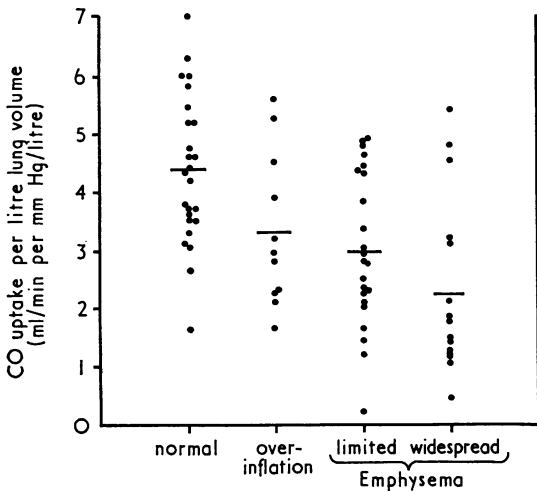


FIG. 6. Relation between transfer factor (expressed per litre lung volume) and the radiographic abnormalities. Analysis confined to patients with severe airflow obstruction ( $FEV_1$  1.5 litres or less).

cause TLC was measured more than four months before or after the radiograph was taken. A review of all the available data on the 16 patients omitted showed a wide range of functional and radiological abnormality and we do not believe that their omission will have systematically biased our analysis.

The radiological diagnosis of widespread emphysema was usually associated with a low TF/VA (Fig. 6) and a TLC of greater than 120% of the predicted value (Fig. 7), but in this series there was

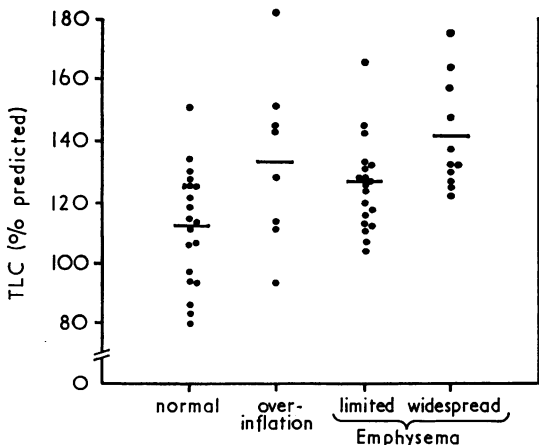


FIG. 7. Relation between TLC (expressed as percentage predicted value) and the radiographic abnormalities. Analysis confined to patients with an  $FEV_1$  of 1.5 litres or less.

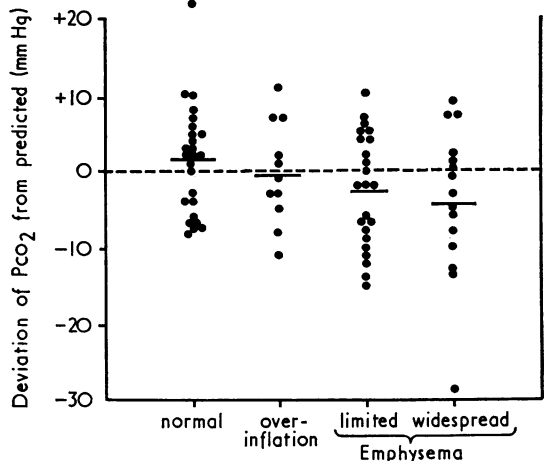


FIG. 8. Relation between deviation of  $PCO_2$  (mmHg) from value predicted from  $FEV_1$  (see text) and the radiographic abnormalities. Analysis confined to patients with an  $FEV_1$  of 1.5 litres or less.

not a significant relation to the deviation of  $PCO_2$  from predicted values (Fig. 8). The changes in the patients whose radiographs showed limited emphysema were somewhat less marked than in those with widespread emphysema.

COMPARISON OF RADIOLOGICAL AND PLETHYSMOGRAPHIC ESTIMATES OF TOTAL LUNG CAPACITY (Fig. 9)

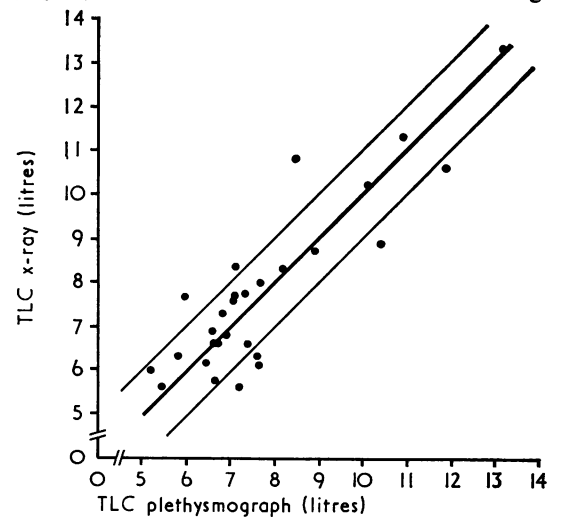


FIG. 9. Relation of radiological and plethysmographic estimates of total lung capacity in 28 patients with severe airways obstruction. Heavy diagonal indicates line of identity; thinner diagonal lines represent a difference between the two estimates of 1.0 litre. Correlation coefficient between the two measurements = 0.874.

difference of 720 ml in the estimates of TLC by the two methods. Mean values for each method for the whole group were identical, indicating that there was no systematic difference between the two methods. There was no tendency for the discrepancy between the two methods to increase with increasing TLC or with severity of airways obstruction.

**PULMONARY HYPERTENSION** Radiological evidence of pulmonary hypertension was noted in only 11 patients. All these patients had severe airways obstruction (average FEV<sub>1</sub> of 0.64 l.) and six had radiological evidence of widespread emphysema. No striking trends in change in TLC, TF/VA, and PCO<sub>2</sub> were observed in these patients but the mean TLC was slightly greater and mean TF/VA somewhat less than the average values for all the 101 patients.

#### DISCUSSION

In recent years it has been recognized that four prominent features of 'chronic bronchitis and emphysema'—airflow obstruction, over-inflation of the lungs with increase in total lung capacity, alveolar destruction (emphysema), and cor pulmonale—can occur to some extent independently. Radiographs taken during breath-holding can be used to assess the last three of these abnormalities, but airflow obstruction itself can be detected only by observing slow emptying or dynamic airway narrowing.

**SIGNS OF 'OVER-INFLATION': INCREASED RETROSTERNAL SPACE, A LOW FLAT DIAPHRAGM, AND INCREASED TOTAL LUNG CAPACITY** Only when the retrosternal space was very large (4.5 cm or more) was it a reliable indicator of severe airways obstruction and commonly associated with a low diaphragm and vascular attenuation. In the range 3.0–4.0 cm, many patients had only slight airflow obstruction, while even if the space was 2.5 cm or less, severe airflow obstruction could be present. In contrast, a low and flat diaphragm usually indicated severe airflow obstruction.

At the onset of this study we had thought that these signs of 'over-inflation' might be put on a more quantitative basis by measuring TLC from the radiograph: although the radiological technique agreed reasonably well with the plethysmographic method, we found that a large TLC was by no means invariably associated with a large retrosternal space or a low and flat diaphragm. In part this will be because the variation in TLC between normal subjects of similar height, age, and sex is considerable, one standard deviation

covering 10–15% above and below the mean value (Cotes, 1968). A low and flat diaphragm may be a more reliable indicator that a change in TLC has taken place in an individual; although the right dome of the diaphragm is at or below the anterior end of the seventh rib in some 5% of subjects without respiratory symptoms, it is very rarely flat (Lennon and Simon, 1965).

The extent to which an increase in lung size or the development of 'over-inflation' implies the presence of emphysema is controversial. A good overall relationship between the size of the TLC and the anatomical changes of emphysema at necropsy has been reported by Nicklaus, Watanabe, Mitchell, and Renzetti (1967). Furthermore, signs of over-inflation alone have been found to predict the presence of emphysema at necropsy in asymptomatic subjects without significant airflow obstruction (Sutinen *et al.*, 1965; Nicklaus, Stowell, Christiansen, and Renzetti, 1966). Both these groups took 2.5 cm as the upper limit of normal for the retrosternal space. In the present series the pulmonary function of patients in whom the retrosternal space was 3.0 cm or 3.5 cm was not significantly different from those in whom the space was 2.5 cm or less. However, patients with a retrosternal space of 4.0 cm or more or a low diaphragm but without attenuation of vessels had a lower TF/VA, a slightly lower PCO<sub>2</sub> than predicted from the FEV<sub>1</sub> and a larger TLC than those with normal chest radiographs. These changes are all in the direction expected if there was a greater incidence of emphysema in the group whose radiographs showed over-inflation. Despite these associations, we believe that signs of over-inflation and increase in TLC cannot be regarded as unequivocal evidence of destructive emphysema since considerable enlargement of TLC can occur in severe attacks of asthma (Woolcock and Read, 1966).

**ATTENUATION OF SMALL PULMONARY VESSELS** This sign has been shown to relate well to extensive alveolar destruction in the core of lung which is abnormal on the radiograph (Laws and Heard, 1962; Reid and Millard, 1964). Vascular attenuation was found in three or four lung zones in 15% of the present patients, giving a similar proportion of patients with 'widespread' emphysema to that previously reported in groups of patients with chronic airways obstruction whose radiographs were assessed by similar criteria (Simon and Galbraith, 1953; Fletcher, Jones, Burrows, and Niden, 1964; Burrows, Niden, Barclay, and Kasik, 1965). All the patients whose radiographs showed areas of vascular attenuation had severe airflow

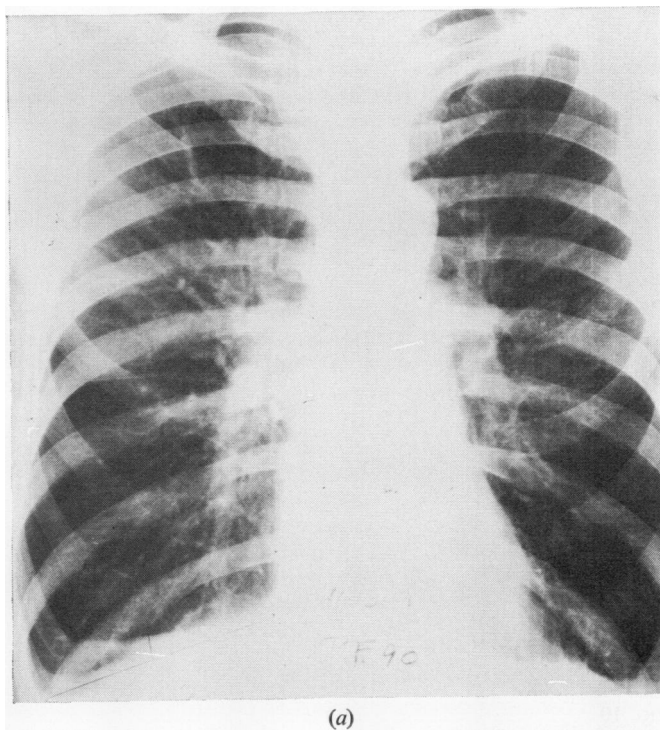
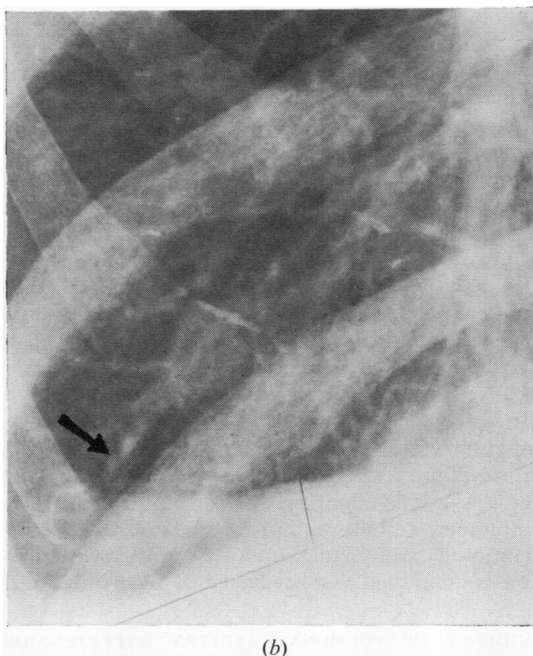


FIG. 10 contd.  
overleaf.

FIG. 10. (a) Man aged 56 with radiological evidence of emphysema (marker vessels right upper zone and medial part of right lower zone: all other lung vessels small): (b) enlargement of right lower zone of same radiograph showing attenuation of small vessels; (c) radiograph of same patient during an episode of congestive cardiac failure (raised jugular venous pressure and ankle oedema). Diaphragm now higher and curved. Heart larger. (d) Enlargement of right lower zone showing small vessels are now larger than in (b).

obstruction, but over 40% of severely obstructed patients were not judged to have vascular changes. As previous experience suggests that only about 15% of lungs from patients with severe, chronic airways obstruction have little or no emphysema at necropsy (Fletcher, 1968), the present results again suggest that only the more severe grades of emphysema result in vascular attenuation that is detected on the radiograph.

The pulmonary function test which correlated best with the presence of vascular attenuation was transfer factor per litre lung volume (TF/VA). Of 15 patients with TF/VA below 2.0 ml/min per mmHg per litre, 13 were judged to show vascular attenuation on the radiograph. TLC was greater than 120% of the predicted value in all the patients with widespread attenuation, but many patients without change in the vessels had a TLC as much



above the predicted value. The changes in lung function in the patients whose radiographs were judged to show 'limited' vascular changes were

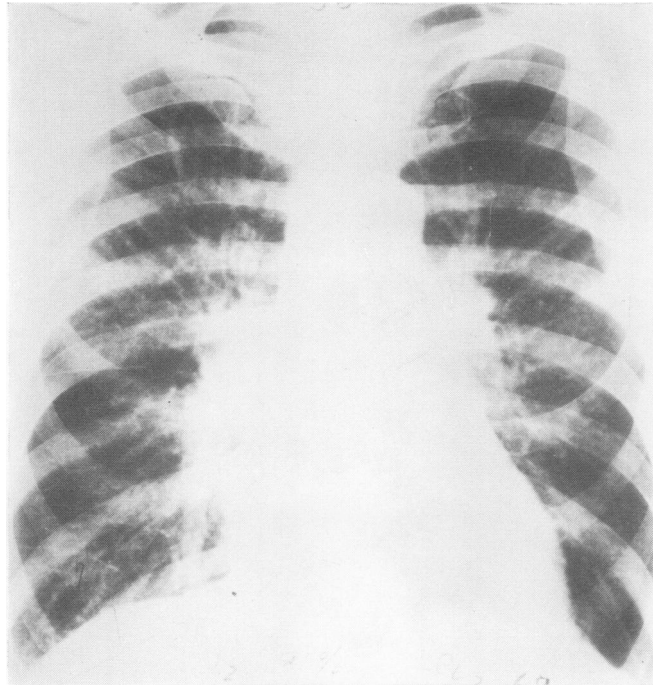


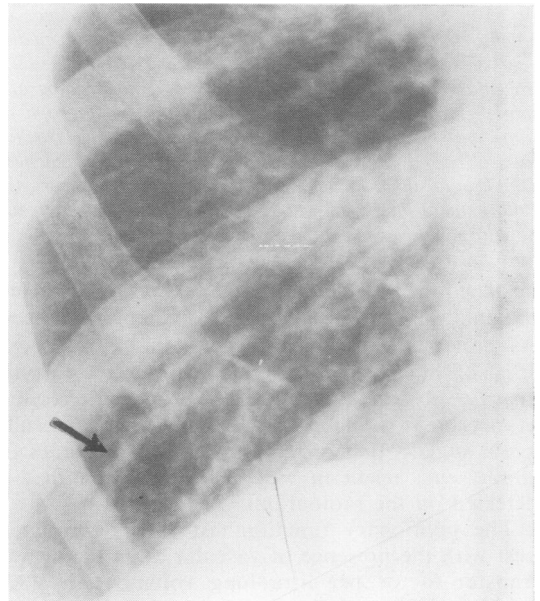
FIG. 10

(c)

similar to those shown by the patients with 'wide-spread' changes, but the abnormalities were less severe. We interpret this finding as indicating that in many patients emphysema was more widespread than appeared from the radiograph and that there were few examples in this series of truly local emphysema associated with otherwise normal lungs. In part this is a consequence of our criteria for selection, since all our patients had evidence of chronic bronchitis and of airflow obstruction. In a population survey, examples of subjects with isolated bullae without symptoms and with little change in lung function would probably be found.

Attenuation of the vessels in emphysema appears to have a functional basis since it can disappear if congestive heart failure develops (Fig. 10). Further, apparent vessel loss in the radiograph or angiogram in life is not always confirmed by angiography at necropsy. The sign may also be produced by pulmonary embolism, and for this reason we have diagnosed emphysema only when vascular attenuation is combined with evidence of over-inflation.

**EVIDENCE OF PULMONARY ARTERY HYPERTENSION**  
This was found rather infrequently in the present series. The incidence would have been higher if the complete sequence of radiographs available in any one patient had been considered. Cor pul-



(d)

monale can occur in patients with chronic obstructive bronchitis without evidence of emphysema, so we regard signs of pulmonary



hypertension as supporting evidence for the presence of severe airflow obstruction but not as direct evidence of destructive emphysema.

In conclusion, we believe that the radiological diagnosis of widespread emphysema can be made with confidence only when there is evidence of alveolar destruction—as indicated by attenuation of medium-sized pulmonary arteries—as well as of over-inflation. Using these demanding criteria, probably only the severer grades of destructive emphysema will be detected. If the diagnosis is based solely on the diaphragmatic contour and the size of the retrosternal space many radiographs will be classified as abnormal in patients who are asymptomatic (and perhaps have emphysema without airflow obstruction (Sutinen *et al.*, 1965)) or who have asthma. The major disadvantages of radiology are that it is very difficult to grade the severity of changes and to assess the overall functional significance of localized changes in the radiograph. Previous studies from Chicago and this department (Burrows, Niden, Fletcher, and Jones, 1964; Burrows *et al.*, 1966) have suggested that in attempting to diagnose emphysema in life it is unwise to rely on any single sign or test but that all available clinical, radiological, and functional data should be considered together. The present results support this conclusion.

We are grateful to Jan Newton-Howes, who made the plethysmographic measurements, and to Staff Nurses Rosemary Chalmers and Patricia Austin, who performed some of the other lung function tests and helped with data analysis. The study was supported by grants from the Wates Foundation, The Tobacco Research Council, and the Chest and Heart Association. Computational assistance was provided by P.M.A. Consultants Limited.

#### REFERENCES

- Barnhard, H. J., Pierce, J. A., Joyce, J. W., and Bates, J. H. (1960). Roentgenographic determination of total lung capacity. *Amer. J. Med.*, **28**, 51.
- Burrows, B., Fletcher, C. M., Heard, B. E., Jones, N. L., and Wooltiff, J. S. (1966). The emphysematous and bronchial types of chronic airways obstruction. *Lancet*, **1**, 830.
- , Niden, A. H., Barclay, W. R., and Kasik, J. E. (1965). Chronic obstructive lung disease. I. Clinical and physiologic findings in 175 patients and their relationship to age and sex. *Amer. Rev. resp. Dis.*, **91**, 521.
- , Fletcher, C. M., and Jones, N. L. (1964). Clinical types of chronic obstructive lung disease in London and in Chicago. *Amer. Rev. resp. Dis.*, **90**, 14.
- , Strauss, R. H., and Niden, A. H. (1965). Chronic obstructive lung disease: III. Interrelationships of pulmonary function data. *Amer. Rev. resp. Dis.*, **91**, 861.
- Campbell, E. J. M., and Howell, J. B. L. (1962). Rebreathing method for measurement of mixed venous  $PCO_2$ . *Brit. med. J.*, **2**, 630.
- Cotes, J. E. (1968). *Lung Function*, 2nd ed. Blackwell, Oxford.
- DuBois, A. B., Botelho, S. Y., Bedell, G. N., Marshall, R., and Comroe, J. H. Jr. (1956). A rapid plethysmographic method for measuring thoracic gas volume: a comparison with a nitrogen washout method for measuring functional residual capacity in normal subjects. *J. clin. Invest.*, **35**, 322.
- Fletcher, C. M. (1968). Some observations on the bronchial and emphysematous types of patient with severe generalised airways obstruction. In *Form and Function in the Human Lung*, edited by G. Cumming and L. B. Hunt, p. 230. Livingstone, Edinburgh.
- , Jones, N. L., Burrows, B., and Niden, A. H. (1964). American emphysema and British bronchitis: a standardized comparative study. *Amer. Rev. resp. Dis.*, **90**, 1.
- Goldman, H. I., and Becklake, M. R. (1959). Respiratory function tests. Normal values at median altitudes and the prediction of normal results. *Amer. Rev. Tuberc.*, **79**, 457.
- Guyatt, A. R., Alpers, J. H., Hill, I. D., and Bramley, A. C. (1967). Variability of plethysmographic measurements of airways resistance in man. *J. appl. Physiol.*, **22**, 383.
- Laws, J. W., and Heard, B. E. (1962). Emphysema and the chest film: a retrospective radiological and pathological study. *Brit. J. Radiol.*, **35**, 750.
- Lennon, E. A., and Simon, G. (1965). The height of the diaphragm in the chest radiograph of normal adults. *Brit. J. Radiol.*, **38**, 937.
- Loyd, H. M., String, S. T., and DuBois, A. B. (1966). Radiographic and plethysmographic determination of total lung capacity. *Radiology*, **86**, 7.
- Nicklaus, T. M., Stowell, D. W., Christiansen, W. R., and Renzetti, A. D. Jr. (1966). The accuracy of the roentgenologic diagnosis of chronic pulmonary emphysema. *Amer. Rev. resp. Dis.*, **93**, 889.
- , Watanabe, S., Mitchell, M. M., and Renzetti, A. D. (1967). Roentgenologic, physiologic and structural estimations of the total lung capacity in normal and emphysematous subjects. *Amer. J. Med.*, **42**, 587.
- Ogilvie, C. M., Forster, R. E., Blakemore, W. S., and Morton, J. W. (1957). A standardized breath-holding technique for the clinical measurement of the diffusing capacity of the lung for carbon monoxide. *J. clin. Invest.*, **36**, 1.
- Reid, L., and Millard, F. J. C. (1964). Correlation between radiological diagnosis and structural lung changes in emphysema. *Clin. Radiol.*, **15**, 307.
- Simon, G. (1970). Radiology and chronic airways obstruction. In: *Modern Trends in Diagnostic Radiology*, edited by J. W. McLaren, vol. 4, chap. 2, p. 21. Butterworths, London.
- (1971). *Principles of Chest X-ray Diagnosis*, 3rd ed., p. 30. Butterworths, London.
- and Galbraith, H. J. B. (1953). Radiology of chronic bronchitis. *Lancet*, **2**, 850.
- Sutinen, S., Christoforidis, A. J., Klugh, G. A., and Pratt, P. C. (1965). Roentgenologic criteria for the recognition of non-symptomatic pulmonary emphysema: correlation between roentgenologic findings and pulmonary pathology. *Amer. Rev. resp. Dis.*, **91**, 69.
- Woolcock, A. J., and Read, J. (1966). Lung volumes in exacerbations of asthma. *Amer. J. Med.*, **41**, 259.