

Vascular anomalies of the head and neck in children

Kate Mahady¹, Stefanie Thust², Rupert Berkeley³, Sam Stuart², Alex Barnacle², Fergus Robertson¹, Kshitij Mankad^{2,3}

¹Lysholm Department of Neuroradiology, National Hospital for Neurology and Neurosurgery, Queen Square, London, UK; ²Department of Radiology, Great Ormond Street Hospital for Children NHS Foundation Trust, London, UK; ³Department of Radiology, Chelsea & Westminster Hospital NHS Foundation Trust, London, UK

Correspondence to: Dr. Kshitij Mankad. Department of Radiology, Great Ormond Street Hospital for Children NHS Foundation Trust, Great Ormond Street, London, WC1N 3JH, UK. Email: Kshitij.Mankad@gosh.nhs.uk.

Abstract: Sixty percent of vascular anomalies in children are found in the head and neck. These lesions can present throughout antenatal, perinatal and childhood development. They broadly fall into two categories: vascular tumours and vascular malformations. Their clinical and, often, psychological impact is determined by both pathological type and location: many lesions follow an uncomplicated natural course and other more complex, extensive or progressive lesions can present a threat to life from mass effect, haemorrhage or large volume arteriovenous shunting. Vascular tumours include infantile haemangioma (IH), congenital haemangioma (CH) and kaposiform hemangioendothelioma (KH); of which IH is the most common. Management options for vascular tumours include conservative approaches, oral medications and surgical intervention as determined by tumour type, location and associated complications. Vascular malformations can be categorised into low flow and high flow lesions. Low flow lesions include capillary, venous and lymphatic malformations (LMs). High flow lesions describe the arteriovenous malformations (AVMs), a highly heterogeneous group of lesions which can present in a variety of ways—the mainstay of treatment for these dynamic lesions is endovascular or surgical obliteration. We provide a practical framework for clinical classification of vascular anomalies of the head and neck in children. We also explore principles of their clinical and radiological assessment along with management, highlighting the importance of a multi-disciplinary approach.

Keywords: Vascular; malformation; infantile; haemangioma; birthmark; kaposiform; arteriovenous

Submitted Jan 14, 2015. Accepted for publication Apr 10, 2015.

doi: 10.3978/j.issn.2223-4292.2015.04.06

View this article at: <http://dx.doi.org/10.3978/j.issn.2223-4292.2015.04.06>

Introduction

Vascular anomalies of the head and neck region constitute approximately 60% of vascular anomalies diagnosed in children and affect approximately 1 in 22 children (1,2). There is a wide spectrum of putative underlying causative factors. These lesions broadly fall into two categories—vascular tumours and vascular malformations—and both have physical and psychological implications for both the patient and their family, particularly if visibly disfiguring. The psychological impact should be considered at each stage of the child's clinical management. Early assessment

of specific clinical features including age at presentation, rate of growth, location and secondary local, systemic and psychological effects is essential to allow timely investigation and appropriate management.

Infantile haemangiomas (IHs) can usually be distinguished from other vascular tumours and malformations by their classic history and presentation, detailed below. In almost all IH cases the diagnosis can be made with history and examination alone and no further investigation or intervention is required.

For other lesions, imaging with ultrasound (US) and/or magnetic resonance imaging (MRI) offers exquisite soft

Table 1 Key features of history and examination in paediatric vascular anomalies

History	
Age at onset	
Growth pattern—proportional to child; slow/rapid; involution	
Pain or itching	
Bleeding	
Past medical, infective & immune, drug, family, social and birth history	
Examination	
Isolated or multiple	
Size	
Fluctuance	
Site—position relative to eye, nose, mouth and trachea	
Tenderness	
Features of infection	
Cardio-respiratory; ear, nose & throat; central and peripheral nervous system; abdomen	

tissue detail with delineation of blood vessel architecture and flow patterns. A diverse group of lesions presenting in complex anatomical locations, a multidisciplinary approach is vital with representation from specialists in paediatrics, dermatology, plastic surgery, orthopaedic and craniofacial surgery, otorhinolaryngology, oncology, neurosurgery, interventional radiology and neuro-radiology, as well as supportive input from psychology, physiotherapy and occupational therapy when needed.

Treatment options for vascular malformations include conservative management, drug treatment, minimally invasive interventions by interventional radiology, laser therapy and open surgery. A combination of several of these therapies is often required. Treatment is often multi-staged: aims and end-points of treatments must be clearly defined by the multidisciplinary team (MDT) at the outset and agreed with patients and/or their families.

Clinical presentation and assessment

Vascular anomalies of the head and neck usually present in childhood. They may be detected with antenatal imaging, present as a ‘birthmark’ in the neonate or emerge as a cutaneous lesion or palpable mass in later childhood. A full clinical history should be taken and examination performed in order to establish if the lesion is symptomatic, isolated

or multiple, whether it is stable or evolving and the extent to which it involves local structures, particularly the airway, eye or other neural structures (*Table 1*).

The physician should exclude features of associated syndromes as a vascular lesion may herald more extensive underlying pathology. For example, widespread cutaneous telangiectasia is found in hereditary haemorrhagic telangiectasia (HHT) which is associated with arteriovenous malformations (AVMs) elsewhere in the brain, liver and lung. Patients with Sturge-Weber syndrome have a facial port wine stain (PWS) [a capillary malformation (CM)] and an associated intracranial pial angioma predisposing to seizures. The ‘PHACES’ syndrome (posterior fossa malformation, haemangioma of the face or neck, arterial stenosis, aneurysm or occlusion, cardiovascular anomalies, eye abnormalities, sternal cleft and supra-umbilical raphe) is used to describe patients with a variety of midline structural abnormalities and a characteristic flat, telangiectatic form of facial haemangioma.

At this stage the cosmetic and psychological impact of the lesion should be considered and relevant support arranged.

Classification

Haemangiomas and vascular malformations are endothelial disorders divided into two distinct pathological groups: vascular tumours (including haemangiomas) and vascular malformations (3). They were first dichotomised in this way by Mulliken and Glowacki in 1982, based on the natural history, histology and cellular activity of these lesions (4) (*Table 2*).

Vascular tumours are composed of rapidly proliferating cells and incomplete blood vessels (5); historically, descriptive terms such as ‘blood-containing lesions’, ‘angiomas’ or ‘birthmarks’ were used; and lesions were categorised as capillary, strawberry or cavernous based upon their component vessel size. This distinction is no longer considered clinically relevant and has been replaced by the now widely recognised International Society for the Study of Vascular Anomalies (ISSVA) classification of 2007, based on the original Mulliken and Glowacki dichotomous system (3).

IH makes up the large majority of lesions in the vascular tumours category and are described below.

Vascular malformations, by contrast, are present at birth and grow proportionately with the child. They are composed of dysplastic arterial, venous and/or lymphatic vessels rather than proliferating cells. Unlike IH

Table 2 Differentiation of vascular tumours and malformations

Differentiation	Vascular tumours			Vascular malformations
	Infantile haemangioma	Congenital haemangioma	Kaposiform hemangioendothelioma; tufted angioma	
Presentation	Absent or small at birth	Present at birth—commonly large	Present before age of 5 years	Present at birth
Growth	Rapid growth during infancy	No growth	Slow growth during childhood; hemangioendothelioma can be locally aggressive	Proportional to growth of child
Involution	Involution through childhood (90% by 9 years)	Rapid involution (RICH) within first year of life; or non-involuting (NICH)	No involution	No spontaneous regression
Lesion	Solid lesion	Solid lesion	Solid lesion	Lesion comprises dysplastic vessels, spaces or channels

RICH, rapidly involuting congenital haemangioma; NICH, non-involuting congenital haemangioma.

spontaneous involution does not occur (6). They are named according to the predominant vessel type and are further classified as ‘high-flow’ and ‘low-flow’ lesions. Lesions that demonstrate arteriovenous shunting such as arteriovenous malformations (AVMs) and arteriovenous fistulae (AVF) are described as high flow, whereas venous malformations (VMs), lymphatic malformations (LMs) or combined lympho-venous/veno-lymphatic malformations (VLMs), together with CMs are described as low flow (7).

Differential diagnosis

Vascular tumours

Infantile haemangioma (IH)

Background and epidemiology

IHs are the most common tumours of infancy, affecting between 5% and 10% of the Caucasian population, with 60% being located in the head and neck (8). They are more common in Caucasian females with a female: male ratio of 2.4-4:1 (9) and can be associated with low birth weight, prematurity, multiple gestation and chorionic villus sampling (4). Lesions undergo a rapid proliferative period lasting months during young infancy, followed by a longer period of gradual involution throughout childhood. Up to 90% resolve completely by the age of 9 years (10).

They are principally composed of highly proliferative hyperplastic endothelial cells and the majority cause no clinical issue, require no investigation and can be left alone

to involute with time. Some lesions of the head and neck cause disturbance of the visual axis or airway compromise due to mass effect and therefore require early intervention (*Figure 1*).

Presentation

IH typically present as a small lesion 2-6 weeks after birth. They undergo a period of rapid proliferation in the first 12-18 months of life followed by a phase of involution. Most appear as bright red exophytic lesions of the skin, though deep-seated lesions can cause no discoloration.

Up to 20% of IH are multiple—if more than five are present, this can indicate internal haemangiomatosis. The liver is the most common site of extra-cutaneous lesions and hepatic haemangiomas are associated with high output cardiac failure that can threaten life. If more than five IHs are found, therefore, imaging with liver US should be arranged (11).

Management

For simple lesions conservative management following a comprehensive clinical history and examination at initial presentation is sufficient. In approximately 10% of patients IH can be complicated, particularly those involving the airway, the oral cavity or the eye (1,12,13). In this situation, imaging with US or MRI and referral to a specialist should be arranged.

Definitive management of almost all complicated IHs is with oral propranolol alone (14). Propranolol has replaced oral corticosteroids as a first line treatment for IH and has been shown in multiple studies to be safe and effective

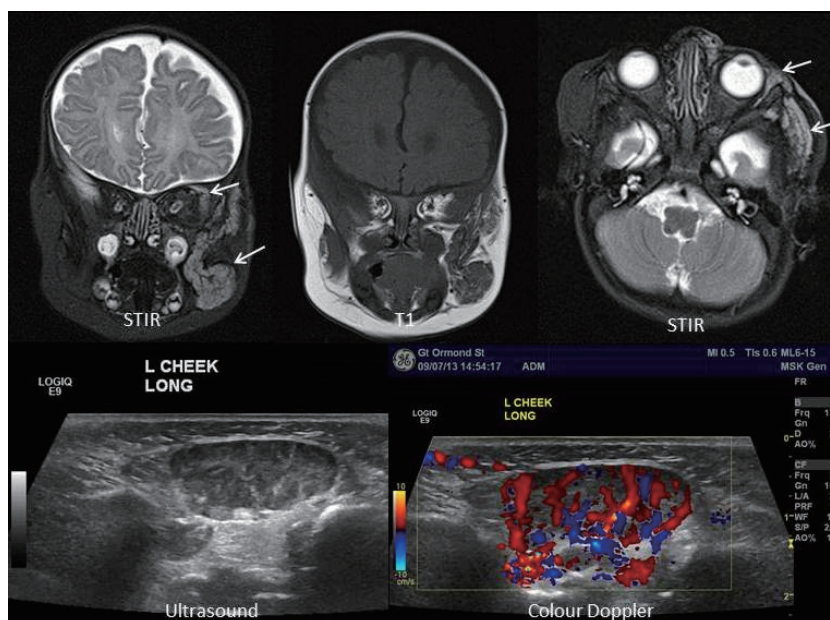


Figure 1 Infantile haemangioma on the face with orbital extension. Note the typical high vascularity demonstrated on colour Doppler ultrasound assessment.

in reducing the size and discolouration of IH, possibly by induction of vasoconstriction (15). More complicated lesions can be managed surgically with laser treatment or resection, although surgical therapy is limited by lesion vascularity and a combined approach is often adopted (16).

Prognosis

In uncomplicated lesions, prognosis is excellent with 90% resolution by 9 years of age and a low incidence of scarring.

For complicated lesions prognosis is variable, with considerable morbidity but low mortality largely associated with lesions in certain locations or underlying syndromes such as PHACES syndrome (17) (*Figure 2*).

Congenital haemangioma (CH)

Background and epidemiology

In contrast to IH, CHs are rare. They are fully formed at birth.

CHs are classified into two types depending on their clinical behaviour: rapidly involuting congenital haemangioma (RICH) and non-involuting congenital haemangioma (NICH). Histologically both differ from IH in that they lack glucose transporter-1 protein expression. They differ from each other in component vessel size, endothelial cell and pericyte size, although there is some overlap between the two (18,19).

RICH begin their rapid involutinal phase soon after

birth and usually resolve by 1 year of age, whereas NICH never involute. Like all haemangiomas these lesions are highly vascular. RICHs can be very large at birth and cause high output cardiac failure in the neonatal period because of significant blood flow to the lesion.

Presentation

Patients present at birth following antenatal suspicion or observation of a cutaneous lesion postpartum. RICHs are round or oval, raised and sometimes infiltrating vascular lesions that can be ulcerated at presentation. NICHs present as a warm, pink to blue/violet mass associated with central, coarse telangiectasia—occasionally peripheral draining veins are seen.

Investigation

If involution is not observed after a period of 4–6 months further assessment with imaging may be indicated, although conservative management is preferred where NICH is suspected. Primary investigation is usually by US and can demonstrate a low resistance, variable flow lesion of varying echogenicity during the proliferative phase.

Contrast enhanced MRI (CE-MRI) will demonstrate a homogeneously enhancing, vascular, solid mass. This also allows assessment of lesion extent and mass effect on surrounding structures (*Figure 3*).

Digital subtraction angiography (DSA) is reserved for patients undergoing endovascular treatment because of the

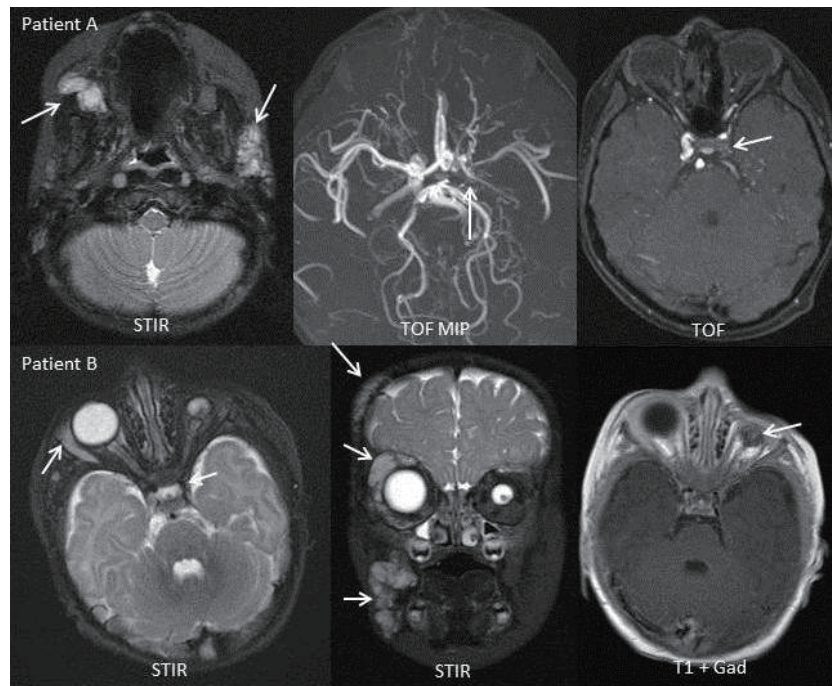


Figure 2 PHACES syndrome with multifocal facial haemangioma, narrowing of the internal carotid artery and unilateral phthisis bulbi. PHACES syndrome: posterior fossa malformation; haemangioma of the face or neck; arterial stenosis, aneurysm or occlusion; cardiovascular anomalies; eye abnormalities; sternal cleft and supra-umbilical raphe.

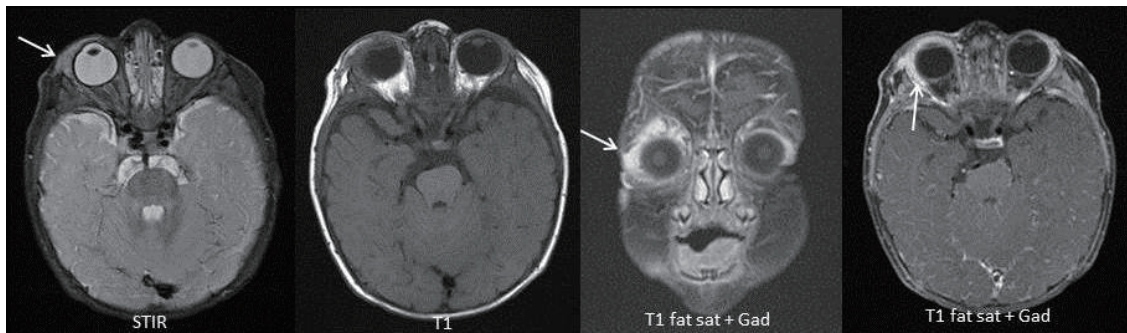


Figure 3 Congenital right-sided orbital haemangioma. Note the homogenous avid enhancement (high T1 signal), which is typical.

invasive nature of the examination and should be arranged only after MDT discussion and performed in a specialist centre with experience in paediatric cerebral angiography.

Management

Conservative management with a 'watch-and-wait' approach is adopted in most cases. Those complicated by haemorrhage, ulceration, heart failure, airway obstruction or ophthalmic involvement and those causing severe psychological distress or disfigurement warrant further discussion and consideration for treatment

RICH presenting with acute cardiac failure may require emergency embolisation to reduce arteriovenous shunting. NICH can be surgically treated but are usually small and do not require treatment.

Prognosis

The majority of RICH resolve by 1 year of age.

Kaposiform hemangioendothelioma (KH)

KH is a rare, locally aggressive but benign lesion that is usually seen in infants and children. It is locally invasive,

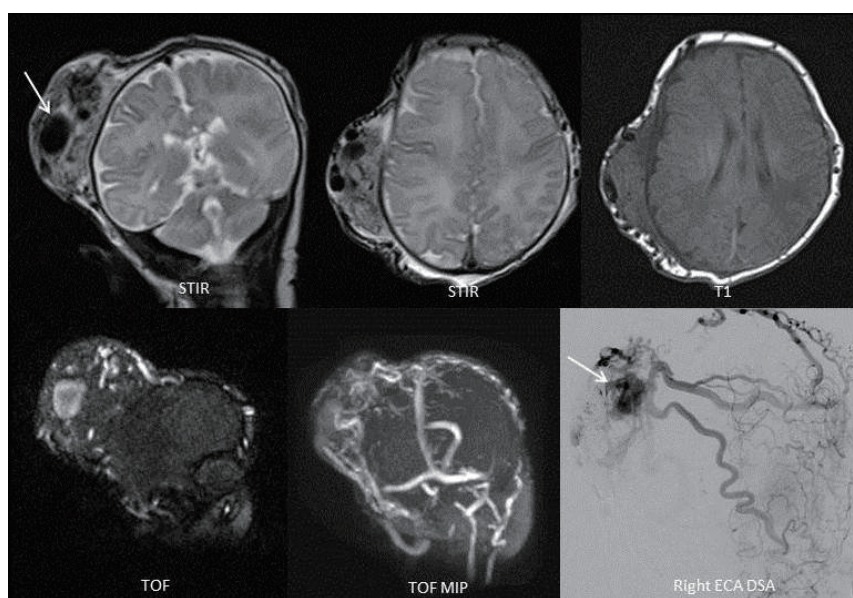


Figure 4 MRI and right external carotid injection DSA demonstrating kaposiform hemangioendothelioma. MRI, magnetic resonance imaging; DSA, digital subtraction angiography.

but has very low malignant potential. KH is associated with Kasabach-Meritt phenomenon, a term which describes a severe coagulopathy due to massive consumption of platelets in the lesion vascular bed causing a profound thrombocytopenia (20). KH lesions typically present as isolated or multiple purplish, purpuric macules which can macroscopically resemble IH or RICH (21,22) (*Figure 4*).

Tufted angioma (TA)

Also associated with Kasabach-Meritt phenomenon, TA is most often seen in the neck and upper body of children younger than 5 years (23). The lesion presents as a red, maculopapular plaque. TAs are slow growing, benign lesions but can be very painful and cause contractures resulting in major disfigurement. They are not known to have malignant potential but are sometimes confused with malignant lesions (Kaposi's sarcoma or angiosarcoma), clinically (24).

Vascular malformations: low flow

Capillary malformations (CMs)

CMs are low flow, sporadic, congenital, persisting post-capillary venule malformations that affect the head or neck. Most are asymptomatic but can be treated with laser therapy to decrease skin thickening and discolouration.

Port Wine Stains (PWSs)

Background and epidemiology

PWSs are an important subtype of CM that affect less than 1% of children with no sex predominance (25). These lesions should be differentiated from simple CM because of important associations with conditions such as Sturge-Weber syndrome and Klippel-Trenaunay syndrome (26).

Presentation

PWS present at birth, growing and darkening in colour with age, and are associated with varying degrees of disfigurement as a result of local soft tissue and bony hypertrophy. They are unilateral in 90% and commonly affect the cutaneous distribution of the ophthalmic and maxillary trigeminal nerve divisions, although lesions of the mandibular division are also seen.

Where a facial PWS is present, an underlying diagnosis of Sturge-Weber syndrome should be considered. In this syndrome the skin lesion is associated with a pial angioma, a vascular malformation over the surface of a region of the brain, which may cause seizures, cerebral hypometabolism and intracranial haemorrhage. This association is seen in up to one in four children with a unilateral ophthalmic-distribution PWS, and in up to one in three children where the lesion is bilateral. There is no association of Sturge-Weber syndrome with lesions of the maxillary or

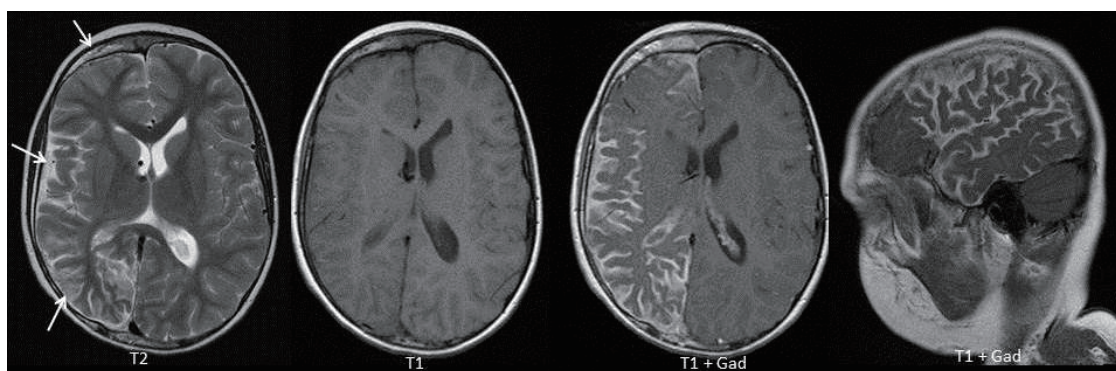


Figure 5 Sturge-Weber syndrome with typical features of enhancing pial angioma and unilateral cerebral hemispheric atrophy. Also note associated thickening of the ipsilateral skull vault.

mandibular regions of the face (27).

Investigation

Although the cutaneous lesion can be diagnosed clinically, in patients with ophthalmic lesions a paediatric neurologist should arrange CE-MRI of the brain as early diagnosis and management of a pial angioma can minimise subsequent seizure activity and resultant brain injury (28) (*Figure 5*).

Management

Referral to a vascular anomaly MDT is recommended with a view to arranging appropriate psychological, medical and potentially surgical support. In ophthalmic lesions, the eye of the affected side is at risk of glaucoma and therefore paediatric ophthalmologists should be consulted.

The psychological impact of a disfiguring facial lesion is the major rationale for active management, primarily by laser photocoagulation. Several treatments can be required and the lesion might never be cleared, although prognosis is improved if treatment is instigated at less than 6 months of age (because of the lesions' smaller size and reduced disruption to the underlying tissues) (29). Surgery for debulking, reconstructive flaps or for haemostasis of bleeding nodules is sometimes indicated.

Prognosis

PWSs are persistent and can cause severe disfigurement if untreated. Apart from complications of glaucoma and underlying intracranial disease in Sturge-Weber syndrome, however, PWS follow an otherwise benign clinical course.

Venous malformations (VMs)

Background and epidemiology

VMs constitute up to 40% of all diagnosed vascular anomalies (30). They affect males and females equally like all malformations that are present at birth.

Unlike IH, they grow with the child and do not spontaneously involute, typically becoming larger around puberty, when they may require intervention. VMs can involve soft tissue and bone and can cause disfigurement or disability.

Presentation

Children usually present with a bluish, fluctuant, soft skin lesion on either the cutaneous skin or mucous membranous surface, although deep-seated lesions may not cause discolouration. The lesion can swell (particularly in the morning because of stasis of flow overnight) but chronic pain is a more common feature secondary to mass effect, venous congestion and intermittent painful thrombosis. There is no palpable thrill or audible bruit on clinical examination. The lesions are soft and can be compressed (or 'emptied'). They change with patient position and Valsalva manoeuvres as they are flow dependent.

Investigation

Full clinical assessment of the extent of the lesion and associated deformity must be undertaken. VMs comprise abnormal vessels lined with abnormal endothelium and can be associated with coagulopathy and elevated D-Dimer levels (31).

The imaging investigation of choice is US which may show characteristic phleboliths (well defined, round calcific lesions) representing areas of spontaneous thrombosis. Doppler US will demonstrate slow flow in compressible, dilated vascular channels.

CE-MRI provides anatomical assessment of lesion extent and complications such as bone or orbital involvement (*Figure 6*).

Management

The majority of lesions are small and relatively

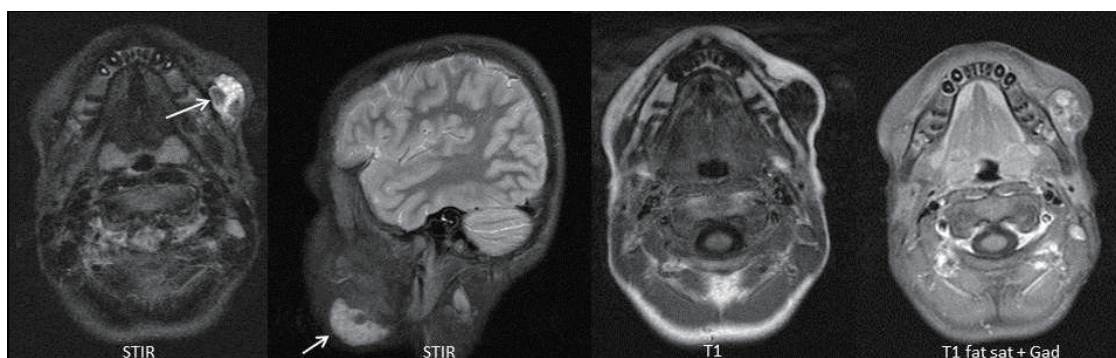


Figure 6 Venous malformation adjacent to the left mandible. Note the low signal foci within the lesion representing phleboliths.

asymptomatic, requiring no intervention. Compression of larger extremity lesions with graded compression garments can help to alleviate swelling and pain. Medical management remains controversial but early studies have shown some benefit from long-term low molecular weight heparin (32) and anti-platelet drugs (33) in provision of some symptomatic relief and possible prevention of localised intravascular coagulopathy and thrombosis.

Percutaneous sclerotherapy is generally regarded as the mainstay of treatment or can form part of a combined approach, together with surgery. Most patients require multistage treatment and sclerotherapy is used to manage symptoms, not as a cure.

Surgical resection can be definitive in well-defined lesions. However, it is usually complex and complete resection is often precluded by the diffuse nature of most VMs. Recurrence rates are high.

Prognosis

Treatment is targeted towards prevention of progression and symptomatic relief rather than cure for most VM patients. Even when surgery is undertaken recurrence rates are high. Misdiagnosis as IH can lead to mismanagement and catastrophic surgical complications and so MDT-centred care is critical for these patients.

Lymphatic malformations (LMs)

Background and epidemiology

LMs affect the sexes equally. They are sub-classified depending upon the size of the lymphatic spaces. In general, if the cysts are ≥ 1 cm in diameter the lesions are macrocystic; whereas channels of ≤ 1 cm constitute a microcystic lesion. Lesions can be mixed.

Presentation

LM present at birth in up to 60% of patients and by the age

of 2 years in approximately 90%. Lesions can be confined to the skin or can infiltrate and disrupt local anatomical spaces, viscera and bone or soft tissues. Clinical presentation can therefore be diverse and include airway obstruction, neurovascular dysfunction and deformity.

Investigation and management

For LM this is comparable to that of VM and demands thorough clinical assessment and referral to a vascular anomaly MDT.

Imaging with US is performed to classify lesion components and their channel size, to assess anatomical extent of the lesion and to plan treatment. MRI of macrocystic lesions will show a non-enhancing, thin walled, uni- or multi-loculated cystic lesion with septal enhancement (*Figure 7*). Management should be strictly MDT-led. Management of symptomatic lesions involves surgery and/or sclerotherapy.

Surgical resection has a larger role in the treatment of LM than in VM. Pre-operative image-based staging of lesions is performed to help predict risk and outcome as surgery can be complex (34).

Prognosis

As for VM, treatment for LM is largely symptomatic rather than curative. These lesions can be difficult to treat (35) and MDT involvement is crucial.

Vascular malformations: high flow

Arteriovenous malformations (AVMs)

Background and epidemiology

AVMs are rare, congenital, dynamic vascular lesions. A nidus forms a direct communication between the arterial and venous systems (in the absence of a normal capillary bed) resulting in shunting of blood under arterial pressure into the low pressure venous system (36).

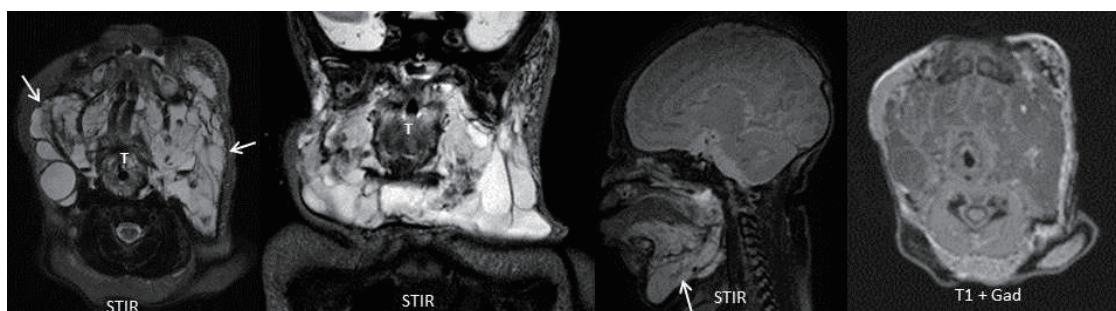

Figure 7 Extensive facial lymphatic malformation. In a lesion this large there is risk of airway compromise (note the narrowed trachea ‘T’).

Table 3 Classification and presentation of AVM [Adapted from Schöbinger, ISSVA 1990 (38)]

Stage	Description
I—Quiescence	Usually no discolouration; pink/blue and warm; Doppler demonstrates A-V shunting
II—Expansion	As stage I plus enlargement, pulsation, thrill, bruit, tense veins
III—Destruction	As stage II plus dystrophic skin change, ulceration, bleeding, pain, necrosis
IV—Decompensation	As stage III plus high output congestive cardiac failure and left ventricular hypertrophy

AVM, arteriovenous malformation; ISSVA, International Society for the Study of Vascular Anomalies; A-V, arteriovenous.

Presentation

Many AVMs are small and asymptomatic, although a proportion shows progression in adolescence.

Growth and local invasion can cause disfigurement, functional disturbance, haemorrhage and high output cardiac failure (37). Clinical progression is staged by the Schöbinger classification (*Table 3*) (38).

Investigation

Referral to the MDT with input from an interventional neuroradiologist is preferable for suspected high flow lesions of the head and neck. Most can be diagnosed and adequately assessed by clinical examination although Doppler US can be used to confirm the presence of AV shunting and initial investigation typically includes DSA performed by an interventional neuroradiologist. MRI of the head and neck can be performed to assess the lesion’s extent and intracranial involvement.

Suitability for diagnostic DSA and endovascular embolisation should be decided by the MDT and the performing interventional neuroradiologist.

Management

Treatment is centred on obliteration of the nidus which can be achieved percutaneously, endovascularly or surgically (*Figure 8*).

Prognosis

AVMs are a highly heterogeneous group of lesions and

general predictions over outcome cannot be made: small lesions may never enlarge or progress beyond Schöbinger stage I and, as such, can be left alone. A proportion of symptomatic lesions can be adequately treated by embolization and then remain quiescent through life. Some, however, prove difficult to manage and require repeated intervention. More complex lesions can result in life threatening complications.

Vascular malformations: mixed lesions

Any combination of venous, lymphatic and arterial components can be seen within complex vascular malformations (3,30,32,34,35).

Conclusions and main messages

- Not all vascular anomalies of the head and neck are haemangiomas. Accurate early clinical assessment can be of great benefit to clinical outcome.
- Lesions are classified into vascular tumours and vascular malformations according to their natural history and histological components.
- Vascular anomalies of the head and neck can cause disfigurement and disability and have a severe psychological impact on patients and their families.
- Where there is any clinical doubt about diagnosis of

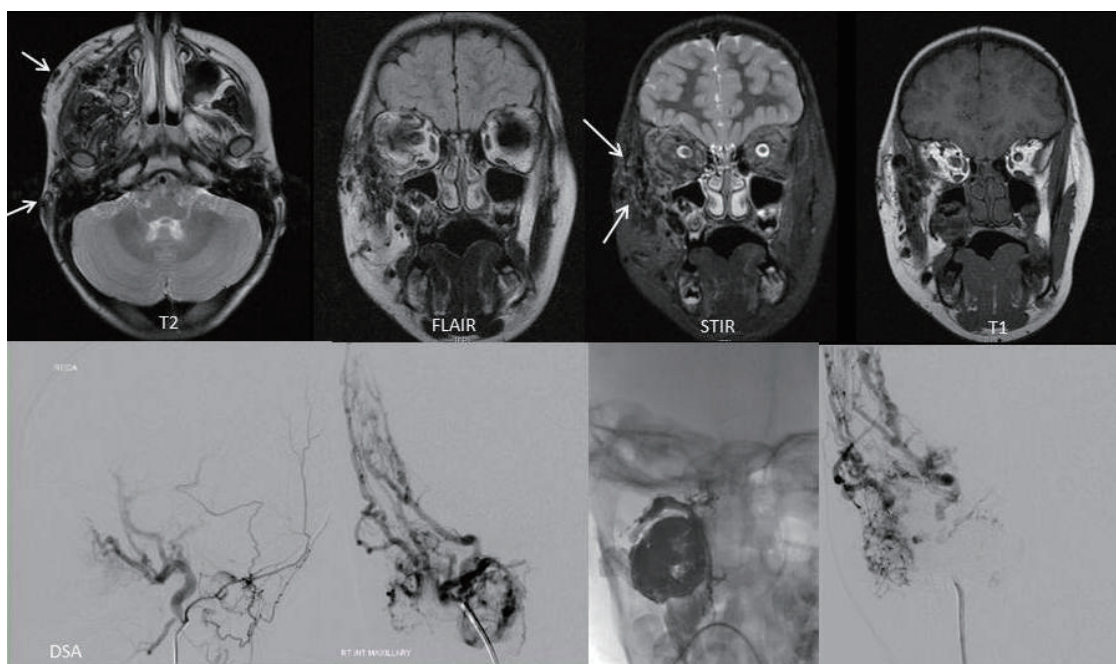


Figure 8 Arteriovenous malformation of the right side of the face with feeding vessels from the right anterior branch of the maxillary artery which was treated with endovascular glue injection. The subsequent DSA demonstrates improved appearances. DSA, digital subtraction angiography.

vascular anomalies, referral to a specialist centre is mandatory.

- Imaging, where required, usually includes US and MRI.
- The majority of lesions can be managed conservatively. A small proportion requires medical, endovascular or surgical intervention.

Acknowledgements

None.

Footnote

Conflicts of Interest: The authors have no conflicts of interest to declare.

References

1. Hemangioma Investigator Group, Haggstrom AN, Drolet BA, Baselga E, Chamlin SL, Garzon MC, Horii KA, Lucky AW, Mancini AJ, Metry DW, Newell B, Nopper AJ, Frieden IJ. Prospective study of infantile hemangiomas: demographic, prenatal, and perinatal characteristics. *J Pediatr* 2007;150:291-4.
2. Drolet BA, Esterly NB, Frieden IJ. Hemangiomas in children. *N Engl J Med* 1999;341:173-81.
3. Enjolras O, Wassef M, Chapot R. Introduction: ISSVA Classification. In: Odile Enjolras, Michel Wassef, Rene Chapot, editors. *Color Atlas of Vascular Tumors and Vascular Malformations*. New York: Cambridge University Press, 2007.
4. Mulliken JB, Glowacki J. Hemangiomas and vascular malformations in infants and children: a classification based on endothelial characteristics. *Plast Reconstr Surg* 1982;69:412-22.
5. Nozaki T, Matsusako M, Mimura H, Osuga K, Matsui M, Eto H, Ohtake N, Manabe A, Kusakawa I, Tsutsumi Y, Nosaka S, Kamo M, Saida Y. Imaging of vascular tumors with an emphasis on ISSVA classification. *Jpn J Radiol* 2013;31:775-85.
6. Buckmiller LM, Richter GT, Suen JY. Diagnosis and management of hemangiomas and vascular malformations of the head and neck. *Oral Dis* 2010;16:405-18.
7. Jackson IT, Carreño R, Potparic Z, Hussain K. Hemangiomas, vascular malformations, and lymphovenous malformations: classification and methods of treatment.

- Plast Reconstr Surg 1993;91:1216-30.
8. Léauté-Labrèze C, Taïeb A. Efficacy of beta-blockers in infantile capillary haemangiomas: the physiopathological significance and therapeutic consequences. *Ann Dermatol Venereol* 2008;135:860-2.
 9. Drolet BA, Swanson EA, Frieden IJ; Hemangioma Investigator Group. Infantile hemangiomas: an emerging health issue linked to an increased rate of low birth weight infants. *J Pediatr* 2008;153:712-5, 715.e1.
 10. Starkey E, Shahidullah H. Propranolol for infantile haemangiomas: a review. *Arch Dis Child* 2011;96:890-3.
 11. Nord KM, Kandel J, Lefkowitz JH, Lobritto SJ, Morel KD, North PE, Garzon MC. Multiple cutaneous infantile hemangiomas associated with hepatic angiosarcoma: case report and review of the literature. *Pediatrics* 2006;118:e907-13.
 12. Broeks IJ, Hermans DJ, Dassel AC, van der Vleuten CJ, van Beynum IM. Propranolol treatment in life-threatening airway hemangiomas: a case series and review of literature. *Int J Pediatr Otorhinolaryngol* 2013;77:1791-800.
 13. Hernandez JA, Chia A, Quah BL, Seah LL. Periocular capillary hemangioma: management practices in recent years. *Clin Ophthalmol* 2013;7:1227-32.
 14. Hartzell LD, Buckmiller LM. Current management of infantile hemangiomas and their common associated conditions. *Otolaryngol Clin North Am* 2012;45:545-56, vii.
 15. Shayan YR, Prendiville JS, Goldman RD. Use of propranolol in treating hemangiomas. *Can Fam Physician* 2011;57:302-3.
 16. Frieden IJ, Haggstrom AN, Drolet BA, Mancini AJ, Friedlander SF, Boon L, Chamlin SL, Baselga E, Garzon MC, Nopper AJ, Siegel DH, Mathes EW, Goddard DS, Bischoff J, North PE, Esterly NB. Infantile hemangiomas: current knowledge, future directions. Proceedings of a research workshop on infantile hemangiomas, April 7-9, 2005, Bethesda, Maryland, USA. *Pediatr Dermatol* 2005;22:383-406.
 17. Haggstrom AN, Drolet BA, Baselga E, Chamlin SL, Garzon MC, Horii KA, Lucky AW, Mancini AJ, Metry DW, Newell B, Nopper AJ, Frieden IJ. Prospective study of infantile hemangiomas: clinical characteristics predicting complications and treatment. *Pediatrics* 2006;118:882-7.
 18. Krol A, MacArthur CJ. Congenital hemangiomas: rapidly involuting and noninvoluting congenital hemangiomas. *Arch Facial Plast Surg* 2005;7:307-11.
 19. Berenguer B, Mulliken JB, Enjolras O, Boon LM, Wassef M, Josset P, Burrows PE, Perez-Atayde AR, Kozakewich HP. Rapidly involuting congenital hemangioma: clinical and histopathologic features. *Pediatr Dev Pathol* 2003;6:495-510.
 20. Sarkar M, Mulliken JB, Kozakewich HP, Robertson RL, Burrows PE. Thrombocytopenic coagulopathy (Kasabach-Merritt phenomenon) is associated with Kaposiform hemangioendothelioma and not with common infantile hemangioma. *Plast Reconstr Surg* 1997;100:1377-86.
 21. Chang JM, Kwon BJ, Han MH, Kang HS, Chang KH. Kaposiform hemangioendothelioma arising from the internal auditory canal. *AJNR Am J Neuroradiol* 2006;27:931-3.
 22. Mac-Moune Lai F, To KF, Choi PC, Leung PC, Kumta SM, Yuen PP, Lam WY, Cheung AN, Allen PW. Kaposiform hemangioendothelioma: five patients with cutaneous lesion and long follow-up. *Mod Pathol* 2001;14:1087-92.
 23. Jones EW, Orkin M. Tufted angioma (angioblastoma). A benign progressive angioma, not to be confused with Kaposi's sarcoma or low-grade angiosarcoma. *J Am Acad Dermatol* 1989;20:214-25.
 24. Wilmer A, Kaatz M, Bocker T, Wollina U. Tufted angioma. *Eur J Dermatol* 1999;9:51-3.
 25. Sidoroff A. Epidemiology of cutaneous vascular neoplasms and malformations in childhood. *Handchir Mikrochir Plast Chir* 2009;41:65-9.
 26. Burns AJ, Navarro JA, Cooner RD. Classification of vascular anomalies and the comprehensive treatment of hemangiomas. *Plast Reconstr Surg* 2009;124:69e-81e.
 27. Hochman M, Adams DM, Reeves TD. Current knowledge and management of vascular anomalies, II: malformations. *Arch Facial Plast Surg* 2011;13:425-33.
 28. Juhasz C, Batista CE, Chugani DC, Muzik O, Chugani HT. Evolution of cortical metabolic abnormalities and their clinical correlates in Sturge-Weber syndrome. *Eur J Paediatr Neurol* 2007;11:277-84.
 29. Chapas AM, Eickhorst K, Geronemus RG. Efficacy of early treatment of facial port wine stains in newborns: a review of 49 cases. *Lasers Surg Med* 2007;39:563-8.
 30. Greene AK. Vascular anomalies: current overview of the field. *Clin Plast Surg* 2011;38:1-5.
 31. Domp Martin A, Acher A, Thibon P, Tourbach S, Hermans C, Deneys V, Pocock B, Lequerrec A, Labbé D, Barrellier MT, Vanwijck R, Vikkula M, Boon LM. Association of localized intravascular coagulopathy with venous malformations. *Arch Dermatol* 2008;144:873-7.
 32. Domp Martin A, Vikkula M, Boon LM. Venous malformation: update on aetiopathogenesis, diagnosis and

- management. *Phlebology* 2010;25:224-35.
33. Hein KD, Mulliken JB, Kozakewich HP, Upton J, Burrows PE. Venous malformations of skeletal muscle. *Plast Reconstr Surg* 2002;110:1625-35.
 34. de Serres LM, Sie KC, Richardson MA. Lymphatic malformations of the head and neck. A proposal for staging. Lymphatic malformations of the head and neck. A proposal for staging. *Arch Otolaryngol Head Neck Surg* 1995;121:577-82.
 35. Balakrishnan K, Edwards TC, Perkins JA. Functional and symptom impacts of pediatric head and neck lymphatic malformations: developing a patient-derived instrument. *Otolaryngol Head Neck Surg* 2012;147:925-31.
 36. Young AE, Mulliken JB. Arteriovenous malformations. In: JB Mulliken, AE Young, editors. *Vascular Birthmarks: Haemangiomas and Malformations*. Philadelphia: Philadelphia WB Saunders, 1988:228-45.
 37. Liu AS, Mulliken JB, Zurakowski D, Fishman SJ, Greene AK. Extracranial arteriovenous malformations: natural progression and recurrence after treatment. *Plast Reconstr Surg* 2010;125:1185-94.
 38. Schöbinger R. In: *Proceedings of International Society for the Study of Vascular Anomalies Congress*. Rome, Italy, 1996.

Cite this article as: Mahady K, Thust S, Berkeley R, Stuart S, Barnacle A, Robertson F, Mankad K. Vascular anomalies of the head and neck in children. *Quant Imaging Med Surg* 2015;5(6):886-897. doi: 10.3978/j.issn.2223-4292.2015.04.06