

Mushroom worker's lung – two outbreaks

C. J. STEWART

Department of Chest Medicine, Ipswich

Stewart, C. J. (1974). *Thorax*, 29, 252–257. **Mushroom worker's lung—two outbreaks.** The clinical picture, immunological findings, and working environment of six mushroom farm workers who developed the characteristic features of mushroom worker's lung while handling pasteurized compost are reported and discussed.

A specific antigen has not been identified. The sporadic occurrence of the condition suggests that the antigen is present only intermittently in the working environment in sufficient concentrations to cause alveolitis. Until such time as the constitutional, immunological, and environmental factors predisposing to the development of alveolitis are better understood preventive measures must be empirical.

An acute feverish illness with constitutional and respiratory symptoms (principally dyspnoea) and chest radiographic changes was first described in 16 Puerto Rican mushroom farm workers in Pennsylvania by Bringhurst, Byrne, and Gershon-Cohen in 1959. A further nine cases have been reported, six of them in Britain (Sakula, 1967; Jackson and Welch, 1970; Craig and Donevan, 1970; Chan-Yeung, Grzybowski, and Schonell, 1972). Mushroom worker's lung is a form of extrinsic allergic alveolitis (Pepys, 1969) due to the inhalation of organic dust particles derived from either the mushrooms, their spores or the compost in which the mushrooms are grown. A lung biopsy on a patient gave a histological pattern of alveolitis and interstitial lung fibrosis (Jackson and Welch, 1970).

Since the summer of 1969, 15 mushroom farm workers from two farms in Suffolk have been seen because of respiratory illness in the Chest Department. Six of them presented a characteristic clinical and radiological picture of extrinsic alveolitis. The essential clinical details of these six patients are given in Table I. One (case 1) had a subacute onset and course to his illness, and the other five had an acute illness, of which case 3 is typical.

CASE REPORTS

CASE 1 A.W., aged 54 years, started work in April 1969 on a mushroom farm doing various jobs, chiefly driving a fork lift tractor in the area in which the compost is prepared and for two days each week in the spawning shed. For the first four months he was

TABLE I
CLINICAL AND RADIOGRAPHIC FINDINGS IN SIX PATIENTS WITH MUSHROOM WORKER'S LUNG

	Patient						Total
	1	2	3	4	5	6	
Age (yr)	54	24	50	19	23	33	
Dyspnoea	(+)	+	(+)	+	+	+	6
Cough	0	+	+	+	+	+	5
Sputum	0	+	0	0	+	+	3
Fever and malaise	0	(+)	+	(-)	(+)	(+)	5
Joint pains and aching muscles	0	+	0	+	+	+	4
Weight loss	0	+	0	0	+	+	3
Creptitations	0	+	+	+	+	+	5
Abnormal chest radiograph	+	+	+	+	+	+	6
Duration of work on farm	5 mth	3 wk	4 dy	4 wk	6 dy	3 mth	
No. of days working in spawning shed	30–40	3–6	2	1	3	20+	

(+) = presenting symptom

fit. One afternoon, after working all morning in the spawning shed, he noticed that he was short of breath. For the next four weeks he became progressively more disabled. He then gave up work and saw his doctor. Almost immediately his breathing improved and he was practically normal when first seen at the clinic a week later. Although his chest radiograph showed widespread change (Fig. 1) there were no abnormal physical signs in the chest. A week later, having had no special treatment, he was symptomless and there was considerable clearing of the abnormal shadows in the chest radiograph.

CASE 3 While on holiday at the end of May 1970, T.R., aged 50, was employed as a labourer on a mushroom farm. At the end of the first day's work in the spawning shed he noticed that he was breath-

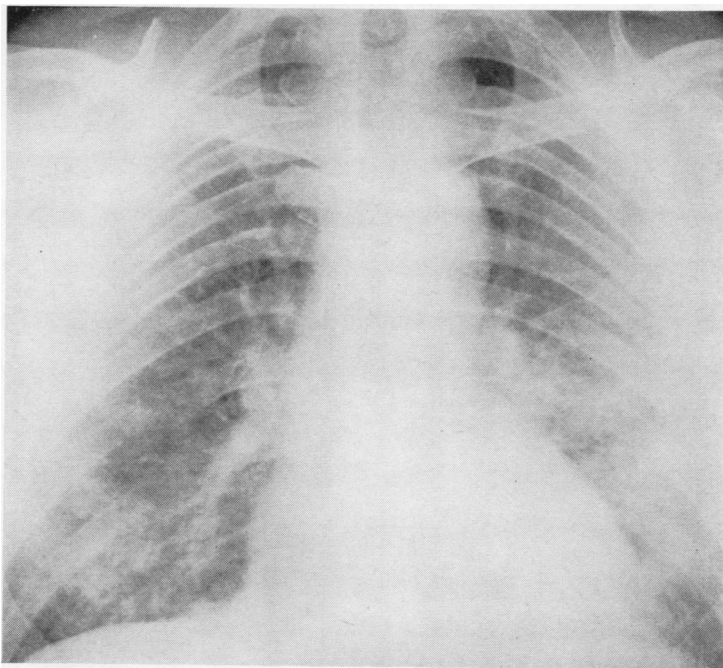


FIG. 1. *Case 1. Chest radiograph taken two weeks after the patient left work on a mushroom farm. Note soft confluent infiltration in the mid and lower zones of both lungs.*

less. He continued work for three more days and then went to see his doctor who found him breathless and feverish. In spite of two 'courses' of antibiotics he remained breathless and pyrexial, and 'had moist sounds all over his lungs'. When he attended clinic four weeks after leaving work the clinical picture was unchanged and the chest radiograph showed 'fine punctate' shadows throughout both lungs. A week later his chest radiograph showed an increase and confluence of the nodular shadows, yet he was feeling fitter and there was no increase of breathlessness. Eight weeks after the start of his illness he was asymptomatic. A few basal crepitations were audible and his chest radiograph was normal.

CLINICAL FINDINGS

All six patients attributed the onset of their symptoms to work in the spawning shed with pasteurized compost. Only one patient (case 1), employed previously as a farm worker, had had contact with mouldy vegetable matter (grain). All were casual labourers who had worked on the farms for a few hours to five months. Three of the five acutely ill patients (cases 3, 4, and 5) are exceptional in that they had worked with the pasteurized compost for less than three days and

one (case 4) for only about six hours before the onset of symptoms. The other three patients (cases 1, 2, and 6) had worked in the spawning shed on one or two days per week for up to eight weeks. On the day they became ill most of them had worked with the compost for from four to six hours before being aware of their symptoms. Fever, malaise, vomiting, generalized joint pains, and aching muscles were the presenting features in four patients (cases 2, 4, 5, and 6). Although all patients complained of dyspnoea at some stage of the illness, it was the presenting symptom in two (cases 1 and 3). In one patient (case 1) the onset was insidious and in the other (case 3) it was associated with generalized symptoms. Two patients (cases 4 and 5) had a severe exacerbation of dyspnoea 10 days after the onset of their illness. All acutely ill patients were initially treated for bronchopneumonia. Case 6 was admitted to hospital, but the other four (cases 2, 3, 4, and 5) were referred to the Chest Department because of their failure to respond to treatment. Cough was not a prominent symptom in reported cases and was not so in our patients, but when it occurred it was irritating and distressing. Only two patients

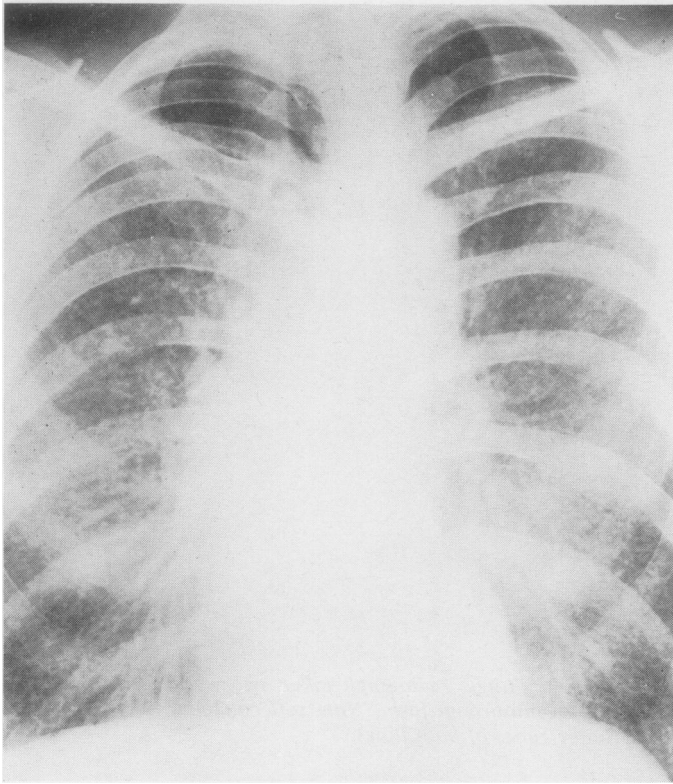


FIG. 2. *Case 3. Discrete nodular shadowing throughout both lungs five weeks after leaving work on a mushroom farm because of dyspnoea and an acute feverish illness.*

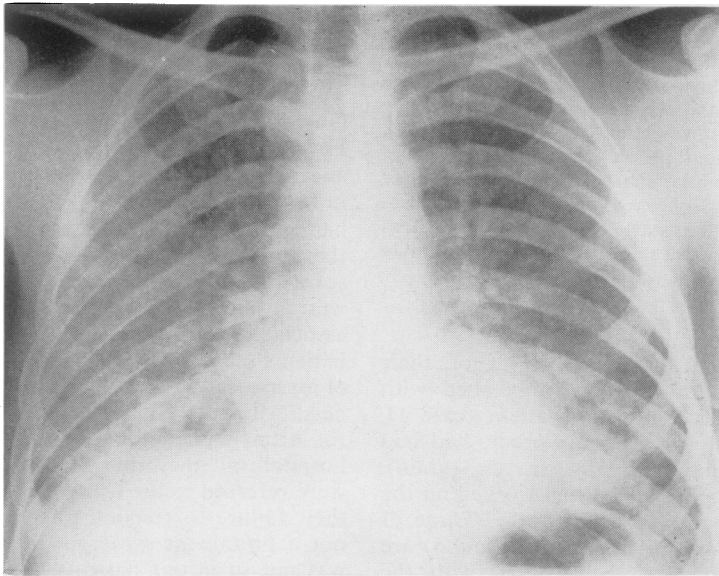


FIG. 3. *Case 6. Nodular infiltration in the mid and lower zones of both lungs with more confluence at the bases. Radiograph taken 12 days after leaving work on a mushroom farm.*

TABLE II
SERUM PRECIPITIN REACTIONS TO VARIOUS EXTRACTS OF ANTIGENIC MATERIAL
ENCOUNTERED ON MUSHROOM FARMS

Antigen	Patient						Total Tested	Positive	Doubtful Positive
	1	2	3	4	5	6			
Farmer's lung antigen	0	0	0	0	0	0	6	0	0
Aspergillus							1	0	0
Mushroom spores	+	0	0	0	+	-	5	2	0
Mushroom extract	(+)					-	2	0	1
Mushroom composts									
Untreated	-	(+)	0	+	(+)	-	4	1	2
During pasteurization	-	0	(+)	0	(+)	-	4	0	2
Pasteurized pre-spawning	-	0	0	0	(+)	-	4	0	1
Pasteurized immediate post spawning	-	(+)	0	0	(+)	-	4	0	2
Pasteurized 14 days post spawning	-	(+)	(+)	+	(+)	-	4	1	3

(cases 2 and 6) had sputum in any quantity, and in case 2 it was bloodstained during the acute phase of the illness. Characteristic fine basal crepitations were present at some stage of the illness in the acutely ill patients and in three (cases 3, 4, and 6) they were generalized. They cleared shortly before the radiograph returned to normal. Severe loss of weight (up to 15 kg) has been reported in most patients but was only moderate (3 to 5 kg) in three of our patients (cases 2, 5, and 6).

All our patients had abnormal chest radiographs. In four (cases 2, 3, 4, and 5) the abnormality consisted of the granular or miliary shadows in the mid and lower zones, and in two (cases 3 and 4) they extended to the whole of both lungs (Fig. 2). One patient (case 4) had a normal chest radiograph a week after the onset of his illness. He then had a severe exacerbation of dyspnoea and, when seen at the Chest Department two weeks later, the radiograph showed miliary shadows throughout his lungs. Two patients, one presenting with dyspnoea only (case 1) and one who was acutely ill (case 6), had confluent ill-defined shadows affecting the lower half of each lung (Figs. 1 and 3).

All but the first patient (case 1) had received antibiotics when first ill; none appeared to respond. Only case 6 was given corticosteroids and two months later he still had basal crepitations and changes in the chest radiograph.

Total and differential white blood cell counts were normal in all patients, except in case 6, when they were done two or more weeks after the onset of the illness. Eosinophil counts were below 450 mm³ in all patients. Four patients (cases 1, 2, 4, and 5) had no reaction to allergy prick tests to a standard range of common allergens including mushroom, mushroom spore, and aspergillus extracts. One patient (case 1) reacted to the house dust mite antigen.

Two patients (cases 1 and 6) had spirometric measurements of ventilatory function. All results were within predicted normal limits. Three patients (cases 2, 3, and 5) had more detailed studies, including lung volumes, compliance, transfer factor, and blood gases; all were within normal limits except that the transfer factor was reduced in one patient (case 3). These tests were performed three to 10 weeks after the onset of their illness. No serial respiratory function tests were done.

ALLERGY TESTS

The results of serum precipitin tests to a range of allergens present in their working environment are shown in Table II. There were no precipitins, even with concentrated serum to farmer's lung antigen (FLH) (*Micropolyspora faeni*). Precipitins to FLH have not been found in five other reported patients (Craig and Donevan, 1970; Jackson and Welch, 1970; Chan-Yeung *et al.*, 1972), but were present in two of Sakula's (1967) four patients. The serum of two of our patients (cases 1 and 5) reacted to extract of mushroom spores and one (case 4) reacted to untreated compost and compost 14 days after pasteurization (post spawning). Only the concentrated serum of the other three patients reacted to two or more of the compost extracts. They all gave some reaction to the 14-day post pasteurized compost. Three other patients have been reported whose serum reacted to mushroom compost extract after spawning (Jackson and Welch, 1970; Chan-Yeung *et al.*, 1972). However, Chan-Yeung obtained precipitins with the serum of persons without contact with mushroom compost.

The concentrated serum of three of our patients (cases 2, 3, and 5) gave no precipitins with extracts of the cultures of three strains of thermophilic fungi isolated from the air sample from the

spawning shed (*Actino bifida chromogens*, *Humicala grisea*, and *Torula thermophilia*).

None of the four patients tested (cases 2, 3, 4, and 5) reacted to inhalation tests with antigens prepared from mushrooms or the compost immediately after spawning. One of Jackson and Welch's two patients reacted to the mushroom compost. Three patients (cases 2, 4, and 5) inhaled extracts of the thermophilic fungi isolated from one of the spawning sheds; a doubtful febrile reaction was obtained in one patient to the *Torula thermophilia* antigen.

These immunological tests have not identified a specific antigen which might be the cause of the alveolitis. They do, however, suggest some immunological reaction by the patients from contact with the many antigens in the working environment.

CULTIVATION OF MUSHROOMS AND WORKING ENVIRONMENT

The commercial cultivation of mushrooms has been described by Sakula (1967) and Craig and

Donevan (1970). All our patients, like those reported by others, related the onset of their symptoms to working with pasteurized compost in the spawning shed. During the pasteurization of the fermented compost a temperature of 130°F and 100° humidity is maintained for five days. These conditions are conducive to the growth of certain strains of fungi, particularly the theraphilic actinomyces, which appears as a grey film impregnating the compost known as 'fire fang'. During the sowing of the mushroom spawn this pasteurized compost is handled mechanically (Fig. 4), giving rise to clouds of dust and steam. A random air sample in the spawning shed of farm II in the autumn of 1971 (Lacey, 1971) gave a count of 700×10^6 spores per cubic metre. As well as the fungal spores the dust contains large quantities of vegetable and animal particles derived from the compost (Sakula, 1967; Craig and Donevan, 1970). The workers are therefore exposed to an abundance of antigenic and other organic materials in the spawning shed.

The six patients became ill during the late spring or summer, two on farm I in 1969 and four on




FIG. 4. Spawning shed. On extreme right is an elevator which tips pasteurized compost into a container which travels to the left. Man on right rakes the compost level. Man on top of machine (centre) pours mushroom spawn into hopper, which distributes it evenly throughout compost. Finally, the spawned compost is compressed (left).

farm II in 1970. In the other reported cases, each occurrence appears to have been isolated, and in those instances where the date of the onset is reported it is equally spread between hot and cold seasons (Sakula, 1967; Craig and Donevan, 1970). The sporadic occurrence of the complaint implies that the antigen is not always present in the working environment or, if present, is not in sufficient quantities to cause alveolitis.

Not all persons at risk appear to be affected, and it would seem that there is some individual constitutional factor which predisposes to the development of the lung lesion. Craig and Donevan (1970) reported two patients out of a total of approximately 100 working in contact with the compost. In the case of farm II four of the workers, 30% of the labour force employed in the spawning shed over the period of the outbreak, had alveolitis and another two had respiratory illnesses without evidence of alveolitis. Another seven remained well and two of them are still working in the spawning shed three years later. As well as the two patients with alveolitis on farm I there were two others with respiratory illness, and the remaining six were apparently unaffected.

Although the clinical picture and histology (Jackson and Welch, 1970) indicated that the inhalation of dust of pasteurized mushroom compost will cause a type III allergic alveolitis in susceptible persons in certain circumstances, there remain a number of unanswered problems. Why is it that some workers react with severe constitutional symptoms after only brief exposure whereas others require much longer periods for sensitization? Why is it that lung changes occur early in some patients (case 6) and in others they are delayed (case 4)? What is it in the dust or the working environment that makes the condition sporadic? Who are the susceptible individuals and can they be identified and protected from the risk of exposure to the dust? Finally, does long-term exposure to small or large doses of the dust have any damaging effect upon the lungs?

Until the answers to these questions are known it will not be possible to adopt a rational approach to prevention. In the present state of our knowledge dust suppression and adequate ventilation are probably the most important. Masks are probably largely ineffective as they only partially

filter off the dust particles of the size 3μ to 10μ (Craig and Donevan, 1970) and they are not well tolerated by the worker, particularly under the conditions in which they are most necessary.

Removal of the patient from contact with the dust is the first essential in the management of both acute and chronic forms of the illness, and it is probably unwise for the patient ever to return to work in contact with vegetable dusts, particularly those likely to have high concentrations of actinomycete spores.

The author is very much indebted to Professor J. Pepys and Dr. A. Pickering, of the Department of Immunology of the Institute of Cardiorespiratory Diseases of the Brompton Hospital, and to Mr. J. Lacey of Rothamsted Experimental Station for the immunological studies and the studies of the mycology of the air samples. The material for this report has been collected from numerous sources—general practitioners in the area, colleagues in the Ipswich Group Hospitals, Mr. John Gooch and Mr. F. Townes, manager of one of the mushroom farms. Reproduction of the chest radiographs and the photographs was done by Mr. P. Dove, of the Photographic Department of the Ipswich Hospitals. Secretarial and clerical assistance was given by Mrs. E. Hart and Mr. R. Cuthbert.

REFERENCES

- Bringhurst, L. S., Byrne, R. N., and Gershon-Cohen, J. (1959). Respiratory disease of mushroom workers. *Journal of the American Medical Association*, **171**, 15.
- Chan-Yeung, M., Grzybowski, S., and Schonell, M. E. (1972). Mushroom worker's lung. *American Review of Respiratory Disease*, **105**, 819.
- Craig, D. B. and Donevan, R. E. (1970). Mushroom worker's lung. *Canadian Medical Association Journal*, **102**, 1289.
- Jackson, E. and Welch, K. M. A. (1970). Mushroom worker's lung. *Thorax*, **25**, 25.
- Lacey, J. (1971). Personal communication.
- Pepys, J. (1969). Hypersensitivity Diseases of the Lung due to Fungi and Organic Dusts. *Monographs in Allergy*, Vol. 4. Karger, Basle.
- Sakula, A. (1967). Mushroom worker's lung. *British Medical Journal*, **3**, 708.

Requests for reprints to: Dr. C. J. Stewart, The Ipswich Hospital Chest Department, St. Helen's Wing, Foxhall Road, Ipswich, Suffolk.