

Re-expansion pulmonary oedema

M. WAQARUDDIN and A. BERNSTEIN

Department of Thoracic Medicine, Hope and Ladywell Hospitals, Salford M6 8HD

Waqaruddin, M. and Bernstein, A. (1975). *Thorax*, 30, 54-60. **Re-expansion pulmonary oedema.** Clinical details are given of two patients who developed ipsilateral pulmonary oedema following re-expansion of their spontaneous pneumothoraces by intercostal drainage of air. The possible mechanisms underlying the oedema are discussed, and prior literature is analysed. Reference is made particularly to its predictability and to precautions recommended to minimize the frequency of this potentially fatal complication in the management of spontaneous pneumothorax.

CASE REPORTS

CASE 1. A 21-year-old man was admitted to Ladywell Hospital on 13 February 1973. Five weeks prior to admission he had had an influenza-like illness associated with cough, sputum production, and dyspnoea. His general condition improved after one week, but his dyspnoea persisted and became gradually worse on exertion. There was no history of chest pain nor any past history of chest disease.

On examination he was comfortable at rest. The heart rate was regular at 80 beats per minute, and blood pressure 130/80 mmHg. The physical signs suggested left-sided pneumothorax, and a chest radiograph confirmed this, showing complete left-sided pulmonary collapse with some mediastinal shift towards the right side (Fig. 1). On the following day an intercostal tube was inserted in the second left intercostal space anteriorly on the left side and a Heimlich valve was attached to the distal end of the catheter. An immediate egress of air through the valve was observed. Within minutes the patient had a bout of severe coughing productive of small amounts of clear sputum. His cough persisted, and although there was no deterioration in his general condition, his sputum showed a pink discolouration within ten minutes. Examination at this stage revealed fine crepitations audible over the left middle and lower chest. An anteroposterior chest radiograph taken one hour after intubation showed almost complete expansion of the left lung but with an homogenous infiltration involving the left middle and lower zones (Fig. 2). Within two hours of intubation he appeared pale and anxious with tachypnoea, sweating, and a

tachycardia of 100 beats per minute. His blood pressure fell to 90/60 mmHg. A pink serous fluid was seen to be draining from the intercostal tube and this was therefore reconnected to an underwater seal system because of the possibility of blockage of the Heimlich valve cusps. His general condition improved spontaneously over the next 24 hours, and during this period about one litre of serous fluid drained into the underwater seal bottle. Serial chest radiographs over the following five days showed clearing of the pulmonary infiltration. Within six days his radiograph returned to normal (Fig. 3) and the intercostal tube was removed on the seventh day. Full expansion was maintained thereafter. He was discharged on 2 March 1973 and has subsequently remained symptom-free.

CASE 2. A 24-year-old man was admitted to Ladywell Hospital on 28 August 1973. Three days prior to his admission he developed left-sided chest pain of sudden onset accompanied by dyspnoea. There was no previous history of chest disease.

On examination he was dyspnoeic at rest. He had signs suggesting a left-sided pneumothorax, and a chest radiograph confirmed this, showing almost complete pulmonary collapse with some mediastinal shift towards the right side (Fig. 4). An intercostal tube was inserted in the fifth left intercostal space in the anterior axillary line, and a Heimlich valve was attached to the distal end of the catheter. An immediate egress of air through the valve was observed. The patient's dyspnoea was considerably relieved, but within three hours crepitations were audible over the left lung posteriorly, and an anteroposterior chest

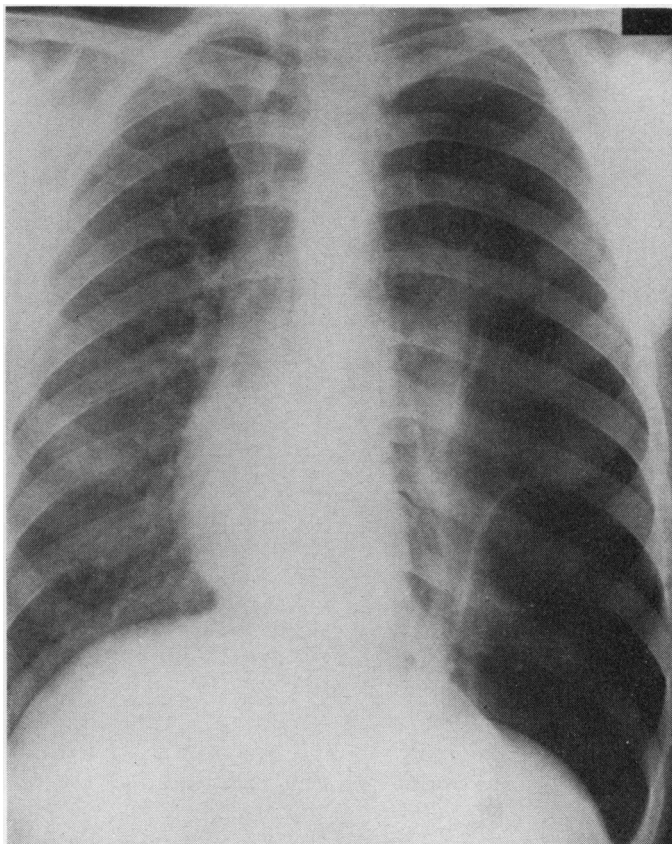


FIG. 1. Case 1. Posteroanterior chest radiograph prior to intubation.

radiograph taken at this time showed a fully expanded left lung, though with diffuse shadowing throughout the whole lung field, excluding only the apical region (Fig. 5).

Serous fluid was seen draining from the intercostal tube, and therefore the drainage system was changed to an underwater seal system. The patient's condition did not deteriorate at any time, and by the fifth day there was complete radiological clearing of the left lung. Extubation was performed and the lung remained fully expanded (Fig. 6). He was discharged on 4 September 1973.

He was re-admitted to another hospital on 26 September 1973 with a further complete left-sided pneumothorax. Intercostal drainage to underwater seal was carried out, and although satisfactory expansion was achieved, initial chest

radiographs showed pulmonary infiltration, which again spontaneously resolved.

DISCUSSION

The earliest accounts of pulmonary oedema occurring in a re-expanded lung are those of Foucart in 1875 and Ortner in 1899—both cited by Carlson *et al.* (1959)—and of Riesman (1902). The oedema followed aspiration of large volumes of pleural fluid. In 1906 Hartley reported 35 similar cases all occurring within one hour of thoracocentesis.

Carlson *et al.* (1959) first reported this complication following re-expansion of the collapsed lung due to pneumothorax, and since then 11 further cases including the present report have been described (see Table).

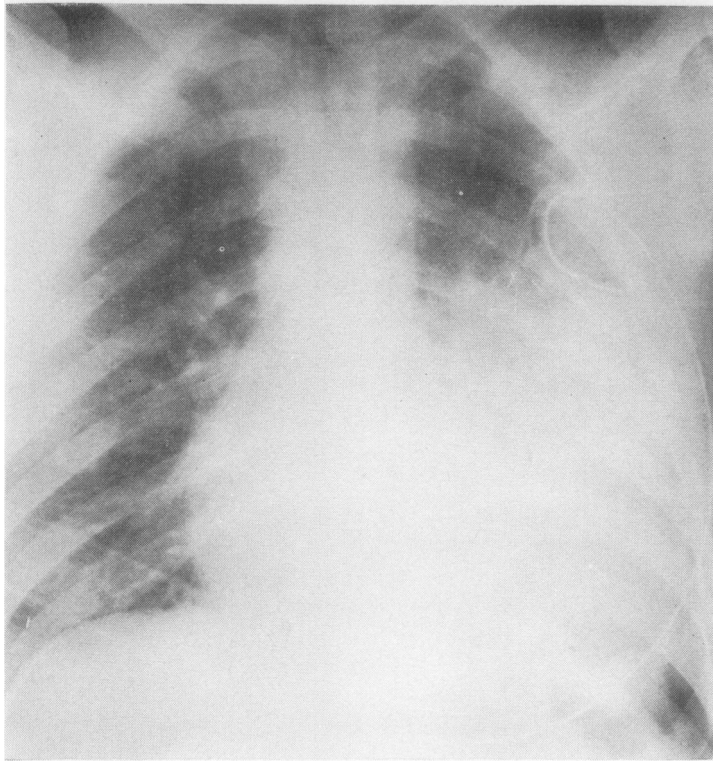


FIG. 2. Case 1. Anteroposterior chest radiograph one hour after intubation.

Early evidence of pulmonary oedema may be the occurrence of cough and chest tightness during or immediately after aspiration of air (Trapnell and Thurston, 1970), as happened in case 2, and in cases described by Childress, Moy, and Mottram (1971), Ratcliff *et al.* (1973), and Saini (1974). It is generally agreed that oedema is more likely to occur as a complication of large pneumothoraces and where collapse has been prolonged for a period of at least three days (Trapnell and Thurston, 1970; Sautter *et al.*, 1971). In the 12 cases recorded, the duration of pneumothorax (from onset of dyspnoea) averaged 18 days with a minimum of three days, apart from one patient (Humphreys and Berne, 1970) with metastatic carcinoma in whom the pneumothorax apparently complicated an attempt to place a central venous pressure catheter percutaneously, and which was re-expanded within one hour of this accident.

The fact that negative pressure was applied to

the pleural cavity in no less than five of the 12 cases reported suggests that the rapidity with which air is removed from the pleural cavity is a second predetermining factor.

Miller *et al.* (1973) emphasize both these points in their experiments on Rhesus monkeys. They found ipsilateral pulmonary oedema within two hours in all monkeys with induced 80 to 100% pneumothoraces where the pneumothorax had been maintained for three days and where rapid re-expansion was obtained by applying suction of -10 cmHg. In contrast to these, pulmonary oedema did not develop in two other groups of monkeys:

(a) where underwater drainage alone was applied after three days' collapse, and

(b) when the lung was re-expanded after one hour with the application of negative pressure to the intrapleural cavity.

There have been several theories as to the pathogenesis of the oedema; all are conjectural,

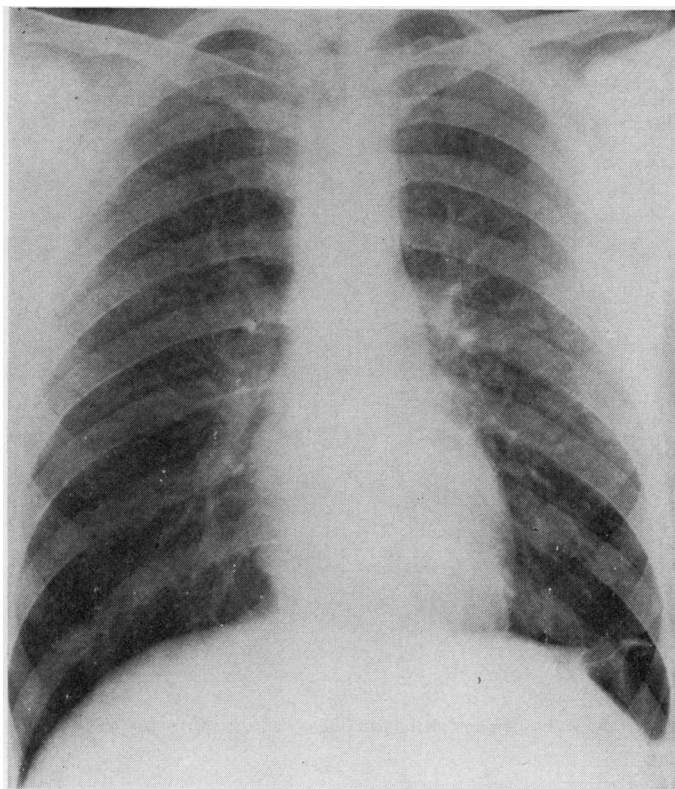


FIG. 3. Case 1. Posteroanterior chest radiograph. Post-extubation film.

and it is probable that all are, to some extent, involved. It is possible, as suggested by Carlson *et al.* (1959) and Humphreys and Berne (1970), that anoxic damage to the pulmonary capillary endothelial cells during collapse is followed by increased permeability of these capillaries to fluid after expansion of the lung and restoration of the pulmonary circulation. There is certainly evidence that capillaries deprived of oxygen for three minutes show an increased permeability to protein (Barach, Martin, and Eckman, 1938).

A second explanation, possibly acting in concert with anoxic capillary damage, is the effect on these capillaries of a sudden and large increase in negative intrapleural pressure which occurs with rapid pulmonary expansion, especially with the aid of suction applied to the pleural cavity. Warren, Peterson, and Drinker (1942) demonstrated in dogs that a large increase in negative intrathoracic pressure drew fluid from pulmonary

capillaries into parenchyma, and, under excessive conditions, not only plasma but red cells left the capillaries. Robin, Cross, and Zelis (1973), in their comprehensive review of pulmonary oedema, also drew attention to this factor.

Finally there is the inevitable consideration of the effect of alteration of surface tension. Several authors (Trapnell and Thurston, 1970; Sautter *et al.*, 1971) suggest that decrease of surfactant in the chronically collapsed lung, with a consequent rise in alveolar surface tension, may be a contributory factor. However, it has been shown that pulmonary oedema is not usually associated with abnormally high alveolar surface tension forces, and that oedema can develop in a degassed lobe without an air-liquid interface (Robin *et al.*, 1973).

With respect to technique, we originally were concerned that the use of the Heimlich valve (Bernstein, Waqaruddin, and Shah, 1973) may

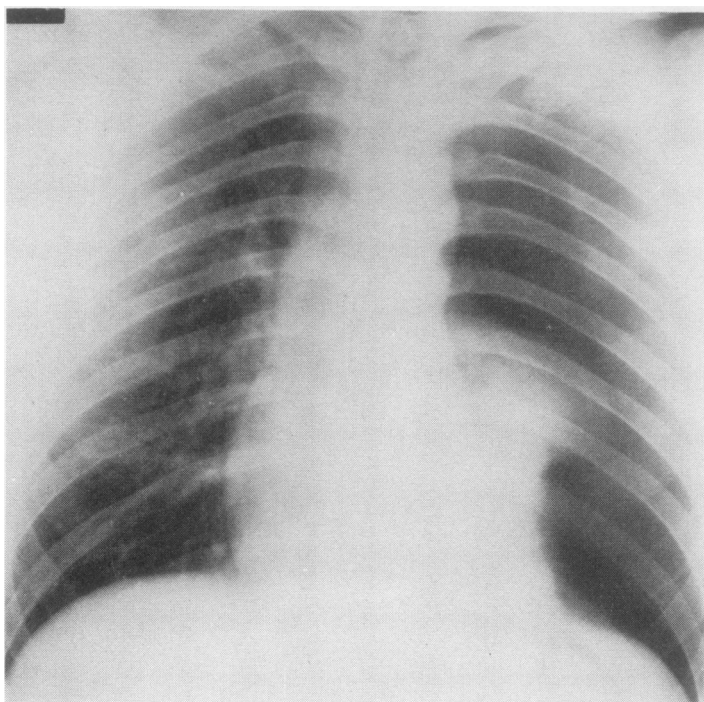


FIG. 4. Case 2. Anteroposterior chest radiograph prior to intubation.

have been a causative factor in the production of oedema because of the rate of egress of air using this method. This fear appears to be obviated by the recurrence of ipsilateral oedema in case 2 during his second admission when the pneumothorax was drained to an underwater seal. There is the possibility that, for some reason, this patient may have been prone to develop pulmonary oedema. The other lung, however, showed no radiological abnormality; plasma proteins were normal, and examination of the heart and electrocardiogram were also normal. Further lung function tests were not performed.

Whatever the mechanisms involved, it seems that the development of pulmonary oedema is a relatively benign complication, although two fatalities and one near fatality have been recorded. The case of Trapnell and Thurston (1970) was an 18-year-old boy with impaired intelligence who exhibited a number of congenital abnormalities, including webbing of the toes and pigeon chest. Following a three-day history of chest pain and dyspnoea he was found to have a left-sided pneumothorax with complete collapse of the

lung. Underwater drainage failed to produce expansion, and suction was applied with a Roberts pump. Severe pulmonary oedema developed in the left lung within four hours. In spite of intensive therapy he died about seven hours after thoracocentesis.

Sautter *et al.* (1971) gave details of a 69-year-old man with a large right-sided pneumothorax of 21 days' duration. He had a past history of hypertension and aortic incompetence with many episodes of left ventricular failure. The lung expanded satisfactorily following drainage, but within one hour he was found to be severely distressed and cyanosed. Unilateral pulmonary oedema was demonstrated radiologically, and death occurred 24 hours later despite intensive resuscitative measures.

The patient described by Ratcliff *et al.* (1973) survived only with the help of intensive therapy, including mechanical ventilation with positive end-expired pressure.

Pulmonary oedema occurs more commonly than the dearth of reports would appear to indicate. The three episodes described occurred over

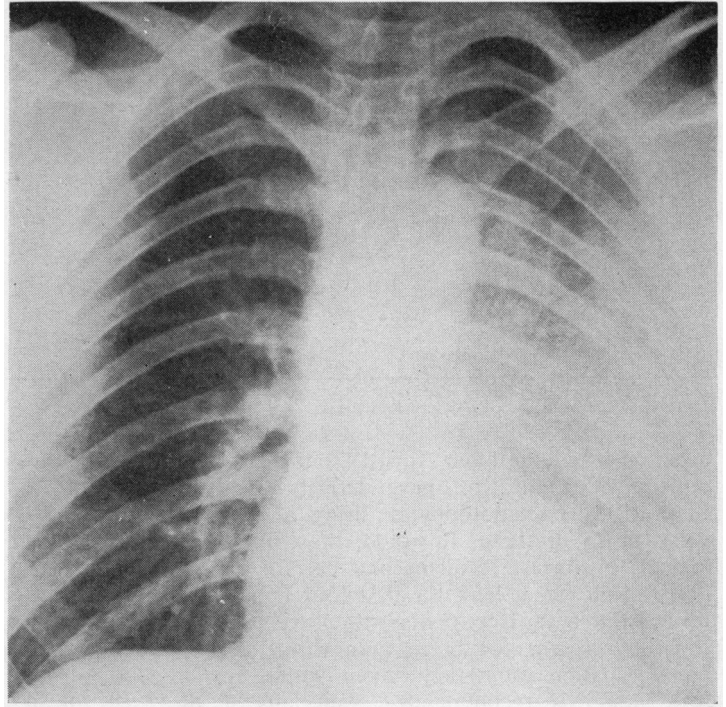


FIG. 5. Case 2. Anteroposterior chest radiograph three hours after intubation.

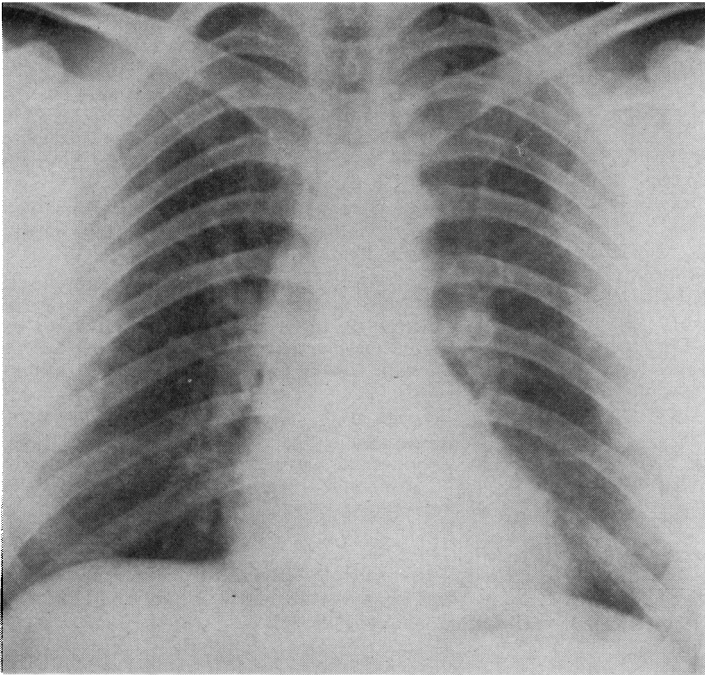


FIG. 6. Case 2. Anteroposterior chest radiograph. Post-extubation film.

TABLE

Author/Year	No. of Patients	Duration ¹	Suction	Outcome
Carlson <i>et al.</i> (1959)	1 ²	5 weeks	+	Recovered
Ziskind <i>et al.</i> (1965)	1	3 days	+	Recovered
Humphreys and Berne (1970)	2	2 weeks	—	Recovered
Trapnell and Thurston (1970)	2	1 hour	—	Recovered
		8 days	—	Recovered
Childress <i>et al.</i> (1971)	1	3 days	+	Died
		6 days	+	Recovered
Sautter <i>et al.</i> (1971)	1	81 days	—	Died
Ratcliff <i>et al.</i> (1973)	1	3 days	+	Recovered
Saini (1974)	1	7 days	—	Recovered
Waqaruddin and Bernstein (present report)	2	5 weeks	—	Recovered
		3 days	—	Recovered

¹Duration of symptoms prior to intubation.

²Five cases mentioned, only one described in detail.

a period extending from April 1971 to May 1974, during which time we have actively treated a total of 34 pneumothoraces, using a Heimlich valve in 25 of these. It would, therefore, seem logical to suggest frequent and careful clinical observation for at least the first four hours after intubation in those patients with large pneumothoraces present for more than three days. A post-intubation radiograph taken within two to four hours is recommended, especially if the application of suction is considered necessary.

It may well be worth while controlling the removal of air by means of a gate clamp applied proximally to the underwater bottle or, if a Heimlich valve is used, attached to a tube connected to the distal end of the valve.

REFERENCES

- Barach, A. L., Martin, J., and Eckman, H. (1938). Positive pressure respiration and its application to the treatment of acute pulmonary edema. *Annals of Internal Medicine*, **12**, 754.
- Bernstein, A., Waqaruddin, M., and Shah, M. (1973). Management of spontaneous pneumothorax using a Heimlich flutter valve. *Thorax*, **28**, 386.
- Carlson, R. I., Klassen, K. L., Gollan, F., Gobbel, W. G. Jr., Sherman, D. E., and Christensen, R. O. (1959). Pulmonary oedema following the rapid re-expansion of a totally collapsed lung due to a pneumothorax: a clinical and experimental study. *Surgical Forum*, **9**, 367.
- Childress, M. E., Moy, G., and Mottram, M. (1971). Unilateral pulmonary edema resulting from treatment of spontaneous pneumothorax. *American Review of Respiratory Disease*, **104**, 119.
- Hartley, P. H-S. (1906). Albuminous expectoration following paracentesis of the chest. *St. Bartholomew's Hospital Reports*, **41**, 77.
- Humphreys, R. L. and Berne, A. S. (1970). Rapid re-expansion of pneumothorax. *Radiology*, **96**, 509.
- Miller, W. C., Toon, R., Palat, H., and Lacroix, J. (1973). Experimental pulmonary edema following re-expansion of pneumothorax. *American Review of Respiratory Disease*, **108**, 654.
- Ratcliff, J. L., Chavez, C. M., Jamchuk, A., Forestner, J. E., and Conn, J. H. (1973). Re-expansion pulmonary edema. *Chest*, **64**, 654.
- Riesman, D. (1902). Albuminous expectoration following thoracentesis. *American Journal of Medical Science*, **123**, 620.
- Robin, E. D., Cross, C. E., and Zelis, R. (1973). Pulmonary edema. *The New England Journal of Medicine*, **288**, 239 and 292.
- Saini, G. S. (1974). Unilateral pulmonary oedema after drainage of spontaneous pneumothorax. *British Medical Journal*, **1**, 615.
- Sautter, R. D., Dreher, W. H., MacIndoe, J. H., Myers, W. O., and Magnin, G. E. (1971). Fatal pulmonary edema and pneumonitis after re-expansion of chronic pneumothorax. *Chest*, **60**, 399.
- Trapnell, D. H. and Thurston, J. G. B. (1970). Unilateral pulmonary oedema after pleural aspiration. *Lancet*, **1**, 1367.
- Warren, M. F., Peterson, D. K., and Drinker, C. K. (1942). The effects of heightened negative pressure in the chest, together with further experiments upon anoxia in increasing the flow of lung lymph. *American Journal of Physiology*, **137**, 641.
- Ziskind, M. M., Weill, H., and George, R. A. (1965). Acute pulmonary edema following the treatment of spontaneous pneumothorax with excessive negative intrapleural pressure. *American Review of Respiratory Diseases*, **92**, 632.

Requests for reprints to: Dr. A. Bernstein, Department of Thoracic Medicine, Hope and Ladywell Hospitals, Salford M6 8HD.