

## Pleural effusion in sarcoidosis: a report of six cases

OM P. SHARMA and JAY GORDONSON

*Pulmonary Disease Service, Department of Medicine and the Department of Radiology, University of Southern California School of Medicine and the Los Angeles County-University of Southern California Medical Center, Los Angeles, California 90033, USA*

**Sharma, O. P. and Gordonson, J. (1975).** *Thorax*, 30, 95–101. **Pleural effusion in sarcoidosis: a report of six cases.** Six (4%) of 150 patients with sarcoidosis had a pleural effusion. A review of the literature revealed seven more patients with pleural sarcoidosis. Analysis of the 13 patients reported so far did not reveal any clinical, radiological, or laboratory feature which may be of diagnostic significance. The diagnosis of pleural sarcoidosis was based on clinical or radiographic grounds and histological evidence of noncaseating granulomata. In three of the patients pleural fluid resolved spontaneously; the other three were treated with corticosteroids. It is suggested that pleural involvement in sarcoidosis, especially in Negroes, may be more frequent than is generally realized and the effusion may occur either at the time of initial presentation or later in the course of the disease.

Although the lung is affected in more than 90% of patients with sarcoidosis, pleural involvement is universally considered to be a rare manifestation of the disease. An analysis of 150 patients with sarcoidosis revealed six in whom pleural effusion was either the presenting feature or developed during the course of the disease. Pleural involvement in sarcoidosis may be more frequent than is generally recognized.

### CLINICAL MATERIAL

One-hundred and fifty patients attending the Sarcoidosis Clinic at the Los Angeles County-University of Southern California Medical Center, Los Angeles showed clinical, radiological or both features of sarcoidosis supported by histological evidence of noncaseating granulomata. Patients with clinical and radiological features have not been included if there was no histological confirmation. Women outnumbered the men by two to one. Negroes constituted 82% of the group, a predominance similar to that recorded in other American series. At the time of presentation two of every three patients were under 40 years of age.

Routine physical examination included chest radiography, slit-lamp examination of the eyes, and x-ray examination of the hands and feet if indicated. Tuberculin (intermediate and second

strengths), coccidioidin, and histoplasmin skin tests were performed on all patients. Estimation of serum calcium, alkaline phosphatase, serum albumin-globulin levels and protein electrophoresis, and serum immunoglobulins were carried out on every patient. Histological evidence of sarcoid tissue has been obtained from various sources by biopsy. All biopsied tissue specimens were stained and cultured to exclude tuberculosis and fungal infections.

In six out of 150 patients, pleural effusion occurred either at the time of initial presentation or during the course of the disease. Of two patients who presented with pleural effusion at the time of the initial visit, one had no other abnormality of the chest radiograph; the other patient demonstrated bilateral hilar adenopathy and a pulmonary infiltrate. In the four patients who developed pleural effusion during the course of the disease, the interval between the initial diagnosis of sarcoidosis and the appearance of effusion varied from four months to six years.

### CASE REPORTS

**CASE 1** A 50-year-old Negro woman was first admitted to hospital in June 1961 with a one-month history of weakness of the right hand and numbness of the left hand. She had been hypertensive since 1946.

*Physical examination* BP 200/130 mmHg. Fundi revealed narrowing of arterioles. Blood: Haemoglobin 10.1 g/100 ml; white count 4,800/mm<sup>3</sup> with normal differential. Albumin : globulin ratio was reversed with increase of alpha-2 and gamma fractions. Bone marrow aspiration disclosed an increase in plasma cells and eosinophils with erythroid hyperplasia. Tuberculin (second strength), histoplasmin, and coccidioidin skin tests were negative. Electromyographic studies were compatible with peripheral neuropathy; a muscle biopsy of the left biceps revealed moderate atrophy. The chest radiograph showed right hilar enlargement and a pulmonary infiltrate in the right lower zone (Fig. 1). She was treated with antihyper-

tein content of 6.5 g/100 ml with 90% lymphocytes. Smears and cultures for acid-fast bacilli and fungi were negative. A thoracotomy was performed which revealed whitish-grey miliary nodules on the visceral pleura (Fig. 3). Biopsy specimens of the lung and pleura showed noncaseating granulomata (Fig. 4). She was given prednisone, 20 mg daily, which was tapered to 5.0 mg daily. The pleural fluid disappeared, and the skin and eye lesions improved with corticosteroid therapy.

The patient, now 63 years old, is asymptomatic. A recent chest radiograph shows diffuse bilateral parenchymal disease and hilar enlargement but no pleural fluid.

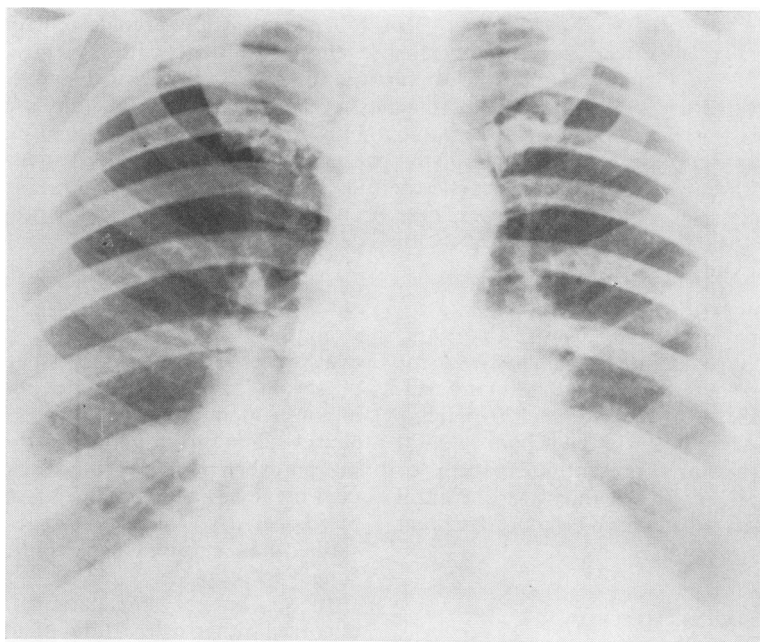


FIG. 1. A postero-anterior chest radiograph showing right hilar adenopathy and pulmonary infiltration.

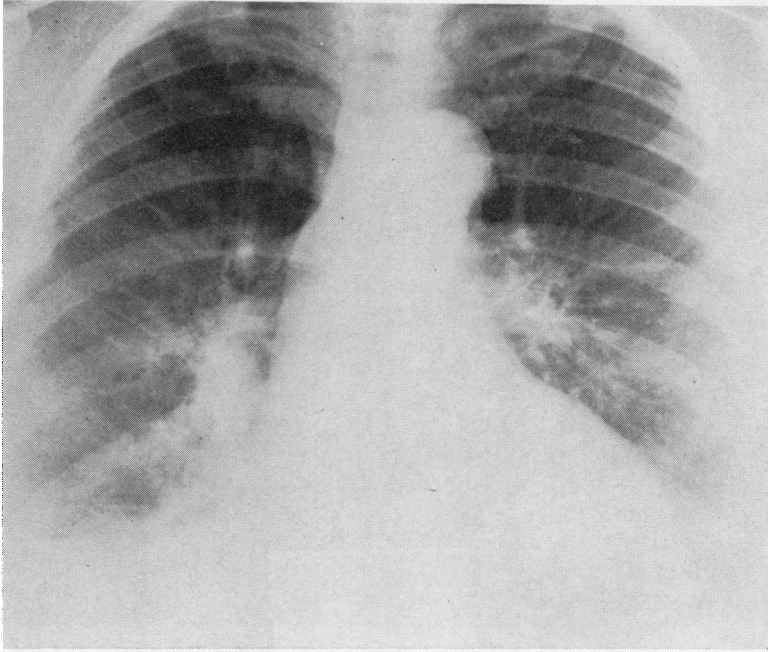
tensive drugs. Subsequent follow-up of the patient was uneventful.

In February 1964, the patient developed an infiltrated, purplish-red papule on the right side of the nose; a biopsy demonstrated noncaseating granulomata. The skin lesion markedly regressed with local injection of corticosteroids. Chest radiographs from 1961 to 1967 remained unchanged.


In February 1967, the hilar enlargement and the pulmonary infiltrate had increased, and a small pleural effusion had developed on the right side (Fig. 2). The patient also noticed an increase in the nasal lesion. Small, mobile supraclavicular nodes were also palpable. Pleural aspiration yielded 130 ml of cloudy yellow fluid with a specific gravity of 1.020 and pro-

**CASE 2** This 26-year-old previously healthy Negro man developed cough and right-sided pleuritic chest pain. He denied fever, night sweats, anorexia, or weight loss. A chest radiograph showed bilateral paratracheal adenopathy and a small pleural effusion on the right side. About 50 ml of straw-coloured fluid was obtained by pleural aspiration. A pleural biopsy specimen revealed nonspecific inflammatory changes. Cultures of the pleural fluid, pleural biopsy specimens, gastric washings, and the urine were negative for acid-fast bacilli and fungi.

A biopsy of the cervical node showed noncaseating granulomata consistent with the diagnosis of sarcoidosis. Special stains, and cultures of the biopsy specimen, did not demonstrate any acid-fast organism



**FIG. 2.** *A PA chest radiograph showing bilateral hilar disease and pulmonary infiltration with right-sided pleural effusion.*



**FIG. 3.** *Whitish-grey miliary nodules on the visceral pleura and the lung.*

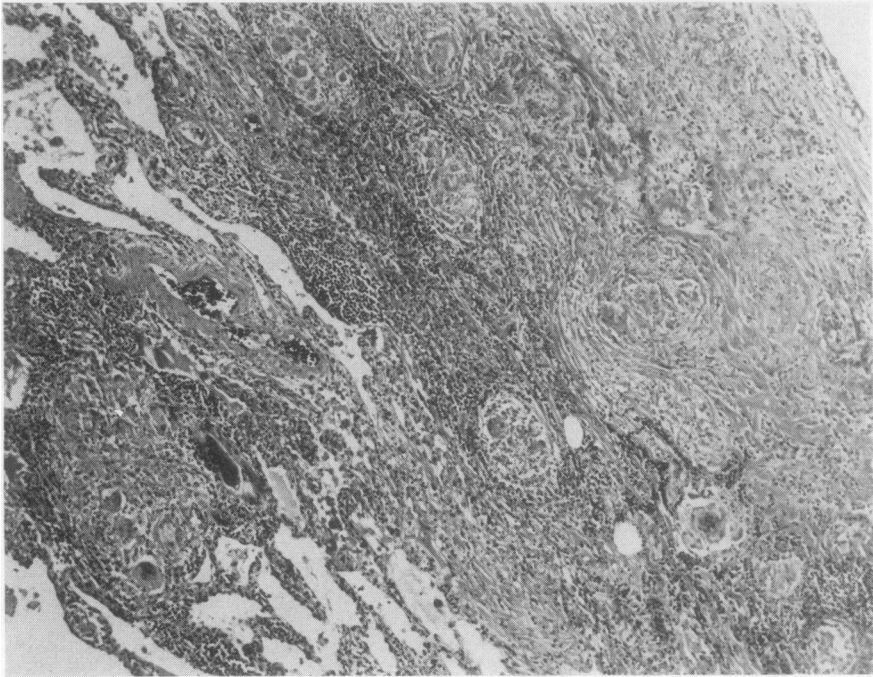


FIG. 4. Microscopic section showing noncaseating granulomata involving the pleura and the lung (H and E  $\times 75$ ).

or fungi. No treatment was given. The lymphadenopathy remained but the pleural effusion resolved spontaneously within eight weeks. Eighteen months later the patient was asymptomatic.

**CASE 3** A 58-year-old Negro seamstress, previously in good health, was admitted for evaluation of right pleural effusion. She denied any previous history of tuberculosis, pulmonary infarction, or heart failure.

**Laboratory studies** Haemoglobin 13.6 g/100 ml; WBC 4500/mm<sup>3</sup>; calcium 10.1 mg; albumin 3.8g/100 ml; globulin 4.9 g/100 ml; tuberculin (intermediate and second strength), coccidioidin, and histoplasmin skin tests negative. A pleural tap yielded 38 ml of straw-coloured fluid. A pleural biopsy showed nonspecific inflammatory fibrosis. Special stains and cultures of pleural fluid and tissue revealed no growth. The patient was not given any treatment.

Six months later a follow-up chest radiograph showed bilateral hilar and right paratracheal node enlargement, and a small amount of pleural fluid bilaterally. A liver biopsy showed noncaseating granulomata. The patient remained asymptomatic.

The most recent chest radiograph shows a decrease in size of the hilar and paratracheal nodes; the pleural fluid has resolved but there is now bilateral diffuse pulmonary disease with linear and reticular shadows.

**CASE 4** A 20-year-old Negro man was admitted with cough, chest pain, dyspnoea, night sweats, and recent weight loss. He denied haemoptysis. Physical examination revealed a temperature of 99.6°F (37.5°C), supraclavicular lymphadenopathy, and hepatomegaly. A chest radiograph showed bilateral hilar and right paratracheal adenopathy and numerous rounded pulmonary densities of varying size. Tuberculin, histoplasmin, and coccidioidin skin tests were negative, a Kveim test was positive. An open lung biopsy revealed noncaseating granulomata. Cultures of the biopsy specimens failed to grow acid-fast bacilli or fungi. Four months later a follow-up chest radiograph demonstrated bilateral pleural effusions and minimal decrease of pulmonary densities. One-hundred and seventy millilitres of serous fluid were obtained from the right side of the thorax. A needle biopsy of the pleura showed nonspecific fibrosis. Pleural fluid was a serous exudate (protein 5.7 g/100 ml) with a specific gravity of 1.017. Pleural tissue and fluid cultures were negative for acid-fast bacilli and fungi. The patient was given prednisone, 40 mg daily. The pleural effusion gradually subsided but the parenchymal disease has remained unchanged.

**CASE 5** A 43-year-old Negro woman was admitted with dyspnoea, cough, and expectoration. Physical

examination was normal. Tuberculin, histoplasmin, and coccidioidin cutaneous reactions were negative. A chest radiograph showed bilateral linear and reticular infiltrates. A liver biopsy showed noncaseating granulomata, and cultures were negative for acid-fast bacilli and fungi. The patient was given prednisone, 50 mg per day, with marked improvement in symptoms; the dose was gradually reduced to 5 mg daily.

Eleven months after the initial admission the patient experienced right-sided chest pain which increased on deep inspiration. A chest radiograph revealed, in addition to diffuse linear and reticulonodular pulmonary infiltrate, a pleural effusion on the right side. Pleural tap yielded a turbid fluid with a protein content of 4.6 g, specific gravity 1.014, and a predominance of lymphocytes. Pleural fluid cultures were negative for acid-fast bacilli. Tuberculin and coccidioidin tests remained negative. Prednisone was increased to 20 mg daily. Six months later the pleural fluid and pulmonary disease cleared and the patient became asymptomatic.

**CASE 6** A 61-year-old Negro woman presented with worsening dyspnoea over a six- to eight-year period. A chest radiograph revealed bilateral hilar adenopathy associated with diffuse pulmonary reticulonodular infiltration. Intradermal tuberculin, histoplasmin, and coccidioidin skin tests were negative; a Kveim test was positive. Laboratory tests disclosed hyperglobinaemia and hypercalcaemia. About a year later the patient presented with a history of left-sided chest pain. Physical examination and a chest radiograph revealed a left pleural effusion. Pleural aspiration yielded serosanguinous fluid with a protein content of 5.6 g/100 ml and a specific gravity of 1.018. A pleural biopsy showed nonspecific inflammatory reaction: granulomas were not seen. Cultures of the pleural fluid and tissue were negative for acid-fast bacilli and fungi. No specific treatment was given. The most recent radiograph shows only hilar adenopathy and diffuse pulmonary infiltration but no pleural effusion.

#### DISCUSSION

It is universally believed that pleural effusion is rare in sarcoidosis. Mayock, Bertrand, and Morrison (1963) analysed the incidence of various manifestations of sarcoidosis in 1,254 patients with the disease; pleural effusion was noted in only seven. Berte and Pfothner (1962) reviewed the American medical literature from 1953 to 1961 and found not a single documented case of pleural effusion resulting from primary sarcoidosis. Kovnat and Donohoe (1965) collected nine cases of sarcoid pleural effusion—seven of the nine were analysed by Mayock *et al.* (1963)—only one of which was confirmed histologically. The authors added two of their own cases in whom the histological evidence of noncaseating

granuloma was firmly secured. Among 275 cases personally studied by Scadding (1967) in England, only two had radiological evidence of pleural disease. Recently, Hahn (1971) reported two more patients with pleural involvement; one had an effusion and the other showed pleural granulomata but no effusion. Nelson and Loudon (1973) described a patient with pleural effusion on whom the diagnosis was achieved by the Cope needle biopsy of pleura.

In our 150 patients with sarcoidosis attending the Los Angeles County-University of Southern California Medical Center, six demonstrated clinical and radiological evidence of pleural effusion; in two of the patients the fluid was present at the time of initial presentation, while in four it appeared during the follow-up period. The diagnosis of sarcoidosis depends on the following: (1) compatible clinical or radiographic evidence of the multisystem disease; histological identification of only noncaseating granulomata; and absence of acid-fast bacilli, fungi, and other bacteria in cultures of sputum, body fluids, and biopsied tissue. If fewer than these three criteria are met with, the diagnosis of sarcoidosis remains open to doubt. The six patients described have satisfied the diagnostic requirements, leaving little doubt regarding the certainty of the diagnosis.

Although a large number of diseases are involved in the differential diagnosis of pleural effusion, the differentiation between sarcoidosis and tuberculosis remains a challenging problem because of clinical and pathological resemblances between the two. About 20 to 30% of untreated patients with tuberculous effusion will develop pulmonary tuberculosis within five years. Thus it is clearly important to consider the diagnosis of tuberculosis which may be confirmed by positive pleural fluid cultures for tubercle bacilli and by securing evidence of caseating granulomata which are seen in about 80% of patients with tuberculous pleural effusion. The negative tuberculin test virtually excludes tuberculosis as the cause of pleural effusion. There was no immunological or bacteriological evidence to support the diagnosis of tuberculosis in any of the six patients reported here.

A review of the literature has revealed seven other cases with sarcoidosis and pleural effusion where the diagnosis of sarcoidosis was based on histological features and negative bacteriological studies for acid-fast bacilli and fungi. Thus the total number of patients with sarcoid pleural effusion is brought to 13 (Table I). Analysis of these 13 patients reveals that pleural involvement

**TABLE I**  
**PLEURAL INVOLVEMENT IN SARCOIDOSIS: A REVIEW OF SELECTED CASES INCLUDING SIX NEW PATIENTS REPORTED BY PRESENT AUTHORS**

No.	Age/Sex	Race	Chest x-ray Features	Tuberculin Skin Test	Biopsy Evidence	Cultures for Acid-fast Bacilli and Fungi	Authors
1	60 M	N	Right hilar adenopathy, right middle lobe atelectasis	Not recorded	Lung, pleura, hilar mass	Negative	Hahn (1971)
2	26 F	N	Bilateral hilar adenopathy, left-sided pleural effusion	Negative	Liver, cervical lymph node	Negative	Hahn (1971)
3	28 F	N	Bilateral hilar adenopathy, left-sided pleural effusion	Negative	Lung, pleura	Negative	Kovnat and Donohoe (1965)
4	24 M	N	Bilateral hilar adenopathy, bilateral pleural effusion	Negative	Lung, pleura, skin	Negative	Talbot <i>et al.</i> (1959)
5	31 M	W	Bilateral hilar adenopathy, pleural effusion (side not recorded)	Not recorded	Lymph node	Negative	McCort <i>et al.</i> (1947)
6	28 F	N	Bilateral hilar adenopathy, left-sided pleural effusion	Negative	Pleura, liver	Negative	Berte and Pfothenauer (1962)
7	50 F	N	Bilateral hilar adenopathy and fibrosis, bilateral effusion	Negative	Pleura, skin, cervical node	Negative	Nelson and Loudon (1973)
8	50 F	N	Right hilar adenopathy, infiltration, right-sided pleural effusion, and right paratracheal adenopathy	Negative	Lung, pleura	Negative	Present study
9	58 F	N	Bilateral hilar adenopathy, bilateral pleural effusion	Negative	Liver Kveim test	Negative	Present study
10	26 M	N	Bilateral paratracheal adenopathy, right-sided effusion	Negative	Scalene node	Negative	Present study
11	20 M	N	Bilateral hilar adenopathy, pulmonary nodules, bilateral effusion	Negative	Lung, lymph node	Negative	Present study
12	43 F	N	Bilateral pulmonary infiltration, right-sided effusion	Negative	Liver	Negative	Present study
13	61 F	N	Bilateral pulmonary infiltration, left-sided effusion	Negative	Liver Kveim test	Negative	Present study

was not recorded under 20 years of age, and only once in the over-60 age group; 85% of the patients were between 20 and 50 years at the time of presentation. Women outnumbered men by a ratio of 54 to 46%: 12 of the 13 patients were Negro, reflecting the racial preponderance of the disease in the United States.

**ONSET OF PLEURAL EFFUSION** Pleural involvement may be the initial manifestation of sarcoidosis or may appear any time during the course of the disease. The effusion may or may not be associated with either hilar adenopathy or pulmonary infiltrate. In case 2, the effusion occurred in association with bilateral hilar adenopathy, and the diagnosis was promptly achieved by a cervical node biopsy. On the other hand, in case 3, the diagnosis was delayed because the pleural effusion was the sole radiological abnormality.

**RADIOLOGICAL FEATURES** Pleural effusion was right-sided in three, left-sided in four, and four

patients had fluid on both sides; the side of the effusion was not recorded in one patient. Bilateral hilar adenopathy with or without pulmonary infiltration occurred in four patients and pulmonary infiltration or fibrosis in two patients.

**PLEURAL FLUID IN SARCOIDOSIS** (Table II) In earlier reports describing sarcoid pleural effusion, higher protein concentrations and lymphocytosis in the fluid were observed. Three of the six patients in this series demonstrated significant lymphocytosis, no cells were seen in two patients, and a cell count was not performed in one patient. Protein concentration of more than 4.0 g/100 ml occurred in four patients. Pleural fluid glucose was reduced in one patient.

**COURSE OF PLEURAL EFFUSION** In the six cases reported here, because of the small amount of fluid (Table II), pleural involvement remained a relatively unimportant manifestation of the disease.

TABLE II  
PLEURAL FLUID AND BIOPSY DATA IN SIX PATIENTS WITH SARCOIDOSIS

No.	Appearance	Fluid Aspirated (ml)	Specific Gravity	Cells	Proteins (g/100 ml)	Glucose (mg/100 ml)	Pleural Fluid Cultures for Acid-fast Bacilli and Fungi	Lung/ Pleural Biopsy
1	Cloudy yellow	130	1.020	Lymphocytes	6.5	40	Negative	Concaveating granuloma Nonspecific inflammatory response, no granuloma No granuloma Fibrosis, no granuloma Fibrosis, no granuloma Acute and chronic inflammation, no granuloma
2	Yellow	50	1.016	Lymphocytes	3.8	80	Negative	
3	Straw	38	1.016	No cells	4.0	70	Negative	
4	Serous	170	1.017	No cells	5.7	68	Negative	
5	Turbid yellow	25	1.014	Many lymphocytes	4.6	85	Negative	
6	Serosanguinous	60	1.018	Not available	5.6	80	Negative	

In cases 2, 3, and 6 the effusion subsided spontaneously in less than six months. The remaining three patients, who were given corticosteroids for symptoms unrelated to pleural effusion, also showed clearing of fluid. Pleural adhesions were not observed.

We believe that sarcoidosis should be included in the differential diagnosis of pleural effusion. The entity may be more frequent than is generally realized.

#### REFERENCES

- Berte, S. J. and Pfothner, M. A. (1962). Massive pleural effusion in sarcoidosis. *American Review of Respiratory Disease*, **86**, 261.
- Hahn, R. (1971). Unusual forms of sarcoidosis. *Southern Medical Journal*, **64**, 541.
- Kovnat, P. J. and Donohoe, R. F. (1965). Sarcoidosis involving the pleura. *Annals of Internal Medicine*, **62**, 120.
- Mayock, R. L., Bertrand, P., and Morrison, C. E. (1963). Manifestations of sarcoidosis. *American Journal of Medicine*, **35**, 67.
- McCort, J. J., Wood, R. H., Hamilton, J. B., and Ehrlick, D. E. (1947). Sarcoidosis: a clinical and roentgenologic study of 28 proved cases. *Archives of Internal Medicine*, **80**, 293.
- Nelson, D. G. and Loudon, R. G. (1973). Sarcoidosis with pleural involvement. *American Review of Respiratory Disease*, **108**, 647.
- Scadding, J. G. (1967). *Sarcoidosis*. Eyre and Spottiswoode, London.
- Talbot, F. J., Katz, S., and Matthews, M. J. (1959). Bronchopulmonary sarcoidosis. *American Journal of Medicine*, **26**, 340.

Requests for reprints to: Dr. Om P. Sharma, University of Southern California School of Medicine, 2025 Zonal Avenue, Los Angeles, California 90033, USA.