

## The pathology of the lung in byssinotics

C. EDWARDS, J. MACARTNEY, G. ROOKE,  
and F. WARD

*East Birmingham Hospital and the Pneumoconiosis Medical Panel, Manchester*

**Edwards, C., Macartney, J., Rooke, G., and Ward, F. (1975).** *Thorax*, 30, 612–623. **The pathology of the lung in byssinotics.** A report of the gross and microscopic appearances in the lungs and the weights of the cardiac ventricles in 43 subjects receiving industrial benefit for byssinosis is presented. In 27 (63%) there was no significant emphysema, in 10 (23%) there were varying amounts of centrilobular emphysema, and panacinar emphysema was found in six (14%). Other changes were of a non-specific nature, but most cases showed heavy black dust pigmentation, often associated with centrilobular dilatation of distal air spaces.

On microscopic examination the parenchyma showed no excessive fibrosis, granuloma formation or any other lesion to suggest an extrinsic alveolitis. The vasculature was in no way remarkable. Using a point-counting technique it was found that there was mucous gland hyperplasia and hypertrophy of smooth muscle in the upper and lower lobar bronchi but not to any significant degree in the segmental bronchi. These appearances suggest an irritant or pharmacological action on the larger bronchi rather than an allergic alveolitis or asthma. 'Byssinosis bodies' were found in seven cases, but the significance of these is doubtful.

Comparison of the ventricular weights with 100 unselected cases coming to necropsy at the East Birmingham Hospital did not indicate an increased incidence of systemic or pulmonary hypertension in byssinotic subjects.

Byssinosis is a chronic respiratory disease affecting a proportion of workers exposed to the dust of raw or waste cotton, soft hemp, or flax.

After several years' work in the mill the byssinotic patient complains of 'tightness' in the chest on return to work after a weekend or a holiday. The oppressive feeling may remain constant throughout the day but usually gradually increases and is worse on the way home.

A few hours later the sensation disappears and does not return until after the next weekend. Later on similar symptoms may occur on Tuesday and Wednesday, and in severely affected people may extend over the whole of the working week. Monday, however, is still the worst day.

There are very few reports of necropsies in such cases, and the findings have been non-specific. Schilling (1925) found only swollen hilar lymph nodes in a series of 300 spinners. Landis (1925) was unable to find changes comparable to those in workers exposed to inorganic dusts. Most of the changes that have been described are those of chronic bronchitis and emphysema, but their

relation to byssinosis is uncertain (Landis, 1925; Rusczewski *et al.*, 1954).

This paper deals with a study of the gross and microscopic appearances in the lungs of 43 cases of byssinosis. The incidence of left and right ventricular hypertrophy in these subjects is also reported.

### MATERIALS

All the 43 patients in this series had been receiving industrial benefit for byssinosis. Byssinosis is a prescribed disease in Britain, and the following classification is generally used (Department of Health and Social Security, 1973):

- Grade  $\frac{1}{2}$  Occasional chest tightness on the first day of the working week
- Grade 1 Chest tightness on every first day of the working week
- Grade 2 Chest tightness on the first and other days of the working week
- Grade 3 Grade 2 symptoms accompanied by evidence of permanent incapacity

from diminished effort tolerance and/or reduced ventilatory capacity.

At the time of writing, in order to qualify for compensation, a worker must fulfil the criteria laid down in grade 3. In addition he or she must have worked for at least 10 years in the card-room or blowing-room where the dusty stages of the processing of the crude product are carried out.

There were 26 women and 17 men in the series. The women were aged between 50 and 86 with a mean of 70 years (standard deviation 7.61). The ages of the men ranged between 60 and 89, with a mean of 73 years (standard deviation 8.54). Six of the women and 11 of the men were known cigarette smokers, and three of the men were pipe smokers. Seventeen of the remaining 20 women were known to be non-smokers, and in three the smoking history was not available.

The length of time spent in the cotton industry ranged between 14 and 67 years with a mean of 36.5. Forty-two of the patients had retired or left the industry, and the time since leaving employment ranged between 2 and 33 years, with a mean of 14.5. Only one of the subjects was still employed in the cotton industry within a year of death.

Postmortem examinations were carried out in the Oldham, Lancashire group of hospitals. At necropsy the lungs were distended with formalin and dispatched, together with the hearts, for examination by the Pneumoconiosis Medical Panel in Manchester. The lungs and hearts were then sent to the East Birmingham Hospital for further examination.

#### METHODS

**EXAMINATION OF THE LUNGS** The lungs were cut into slices 2 cm thick on a sagittal plane. The type and severity of emphysema was estimated using a point-counting technique similar to that described by Dunnill (1962). Each slice was immersed in a dish of water with the medial side uppermost, and a transparent plastic grid was laid over it. The grid was ruled out in 1 cm squares so as to produce points 1 cm apart. The number of points overlying normal and emphysematous lung was counted, and the percentage of lung tissue involved by emphysema was then calculated. In addition the type of emphysema at each point—centrilobular or panacinar—was noted. A significant degree of emphysema was taken to be present if more than 5% of the lungs was involved. Some of the lung specimens had become flattened and distorted during their travels around the country,

and in these only a rough estimate of the severity and type of emphysema could be made.

When point-counting was complete paper-mounted whole-lung sections were prepared in order to provide a permanent record. A modified Gough-Wentworth technique as described by Whimster (1969) was used.

**EXAMINATION OF THE BRONCHI** In 20 of the cases the proportions of the various tissues in lobar and segmental bronchi were estimated using a point-counting technique similar to that described by Dunnill (1962). Lobar and segmental bronchi from five subjects coming to necropsy at the East Birmingham Hospital were used as controls. There were two men and three women with a mean age of 62 years. They were non-smokers, had no history of chronic respiratory disease, and had lived most of their lives in the industrial areas of Birmingham. Two had died of chronic renal failure due to chronic glomerulonephritis; the other three had died of coronary artery disease, status epilepticus and carcinoma of the pancreas respectively.

In each case a cuff of tissue, approximately 0.5 cm in length, was taken from the main upper and lower lobe bronchi, and from the bronchi to the anterior, lateral, and posterior segments of the lower lobe. Each block was processed by a conventional technique, and transverse sections, 5  $\mu$ m thick, were cut and stained with haematoxylin and eosin.

Using a Gillett and Sibert projecting microscope, images of the sections were thrown on to a screen ruled out in a grid of 2 cm squares so as to produce points 2 cm apart. The number of points overlying gland, muscle and connective tissue, and cartilage were noted, and the percentage of each component was then calculated. Approximately 1000 points were counted in each section: a  $\times 5$  objective was used for the main bronchi, and a  $\times 10$  objective for the segmental bronchi.

In the first five cases the percentages of the various components in each block were estimated at three levels approximately 2 mm apart. It was found, however, that the proportions of the components did not vary significantly at different levels, and therefore in the 15 remaining cases only one level was examined.

**EXAMINATION OF THE HEARTS** The hearts were dissected by the method of Fulton, Hutchinson, and Jones (1952). By this method the valves, atria, great vessels, and pericardial fat were first of all trimmed away. The free wall of the right

ventricle was then dissected off and weighed: the left ventricle and septum were weighed together. The upper limit of normal for the right ventricular weight was taken to be 65 g, and for the left ventricle and septum 190 g.

The ventricular weights from 100 consecutive necropsies on general medical and surgical patients at the East Birmingham Hospital were used as controls.

## RESULTS

**GROSS APPEARANCE OF THE LUNGS** There was no significant emphysema in 27 (63%) of the cases. In 16 of these the lungs appeared normal, but there was often heavy carbon pigmentation (Fig. 1). In two cases there was mucous plugging of the medium-sized bronchi, and varying amounts of bronchopneumonia were seen in three. In one case an area of infarction was present, and in another there was a large embolus in the main pulmonary arteries. Two subjects had the typical lungs of mitral valve disease. There was a bronchial carcinoma in one case, and in another there were multiple congenital cysts of the lung parenchyma.

Emphysema was present in 16 cases (37%). In 10 of these the predominant type of emphysema was centrilobular, and the amount of lung substance involved varied between 6% and 40% (Fig. 2). Panacinar emphysema was found in six cases, the amount of lung substance involved varying between 12% and 'very severe'. Six of the emphysematous patients had varying degrees of bronchopneumonia, and plugging of the bronchi was seen in one. In one case an area of infarction was present, together with a small mycetoma, and in another there was a large pulmonary embolus. In seven cases there was no abnormality apart from the emphysema.

**MICROSCOPIC APPEARANCE OF THE LUNG PARENCHYMA** No specific lesions that could be attributed to inhalation of cotton dust were found in the parenchyma. There was no excessive fibrosis, granuloma formation or honeycomb change. All of the cases showed pigmentation by black dust, and this was extremely heavy in some. The dust was mainly deposited around distal bronchi and vessels. In many areas, however, the dust was found in the walls of dilated air spaces, often associated with minor degrees of fibrosis (Fig. 3).

No cotton fibres were found in any of the specimens, but the specific 'byssinosis bodies', as described by Gough (1959), were found in

seven cases (Fig. 4). These consisted of spherical nodules up to 10  $\mu$  in diameter, with a central black nidus surrounded by a clear halo up to 2  $\mu$  thick. With haematoxylin and eosin the halo was yellow, but it gave a faint positive reaction with Perls and periodic acid-Schiff stains.

The pulmonary vasculature was in no way remarkable. For the most part no lesions were found apart from age change. Hypoxic pulmonary vascular disease was seen in two cases, and the changes of mitral valvular disease were seen in a further two cases. Some cases showed embolization of distal pulmonary arteries, but these did not appear to be of significance.


**THE LOBAR AND SEGMENTAL BRONCHI** The percentages of the various components of the bronchial walls are shown graphically in Figs 5, 6, and 7. The means and standard deviations of these values are shown in Tables I and II. The results obtained in the control subjects were in close agreement with those published by Dunnill, Massarella, and Anderson (1969) and Takizawa and Thurlbeck (1971).

In the lobar bronchi (Figs 8 and 9) of the byssinotics there was a significantly higher percentage of muscle ( $P < 0.02$ ) and of gland ( $P < 0.005$ ), with a corresponding lower percentage of connective tissue and cartilage ( $P < 0.005$ ). In the segmental bronchi (Figs 10 and 11) the mean proportions of gland and muscle were somewhat higher in the byssinotics, but there was considerable overlap with the control values, and the differences did not reach a significant level. No correlation was found between the proportions of gland and muscle in the main and segmental bronchi.

Other changes seen included dilatation of gland ducts and inflammation and oedema of the submucosa. Goblet-cell metaplasia was often prominent, and mucus plugs were frequent, particularly in the smaller bronchi. Squamous metaplasia was seen in only three cases. There was no obvious narrowing or peribronchial fibrosis, and no eosinophils were seen in the bronchial walls.

**VENTRICULAR WEIGHTS** The means, ranges, and standard deviations of the ventricular weights in the byssinotics and the control group are shown in Tables III and IV respectively. There was no significant difference between the various values in the two groups.

No relevant lesions were found in the hearts of the byssinotic patients. There was no tendency



**FIG. 1.** *A lung from a byssinotic subject. There is no emphysema, but there is heavy carbon pigmentation (Gough-Wentworth  $\times 0.8$ ).*

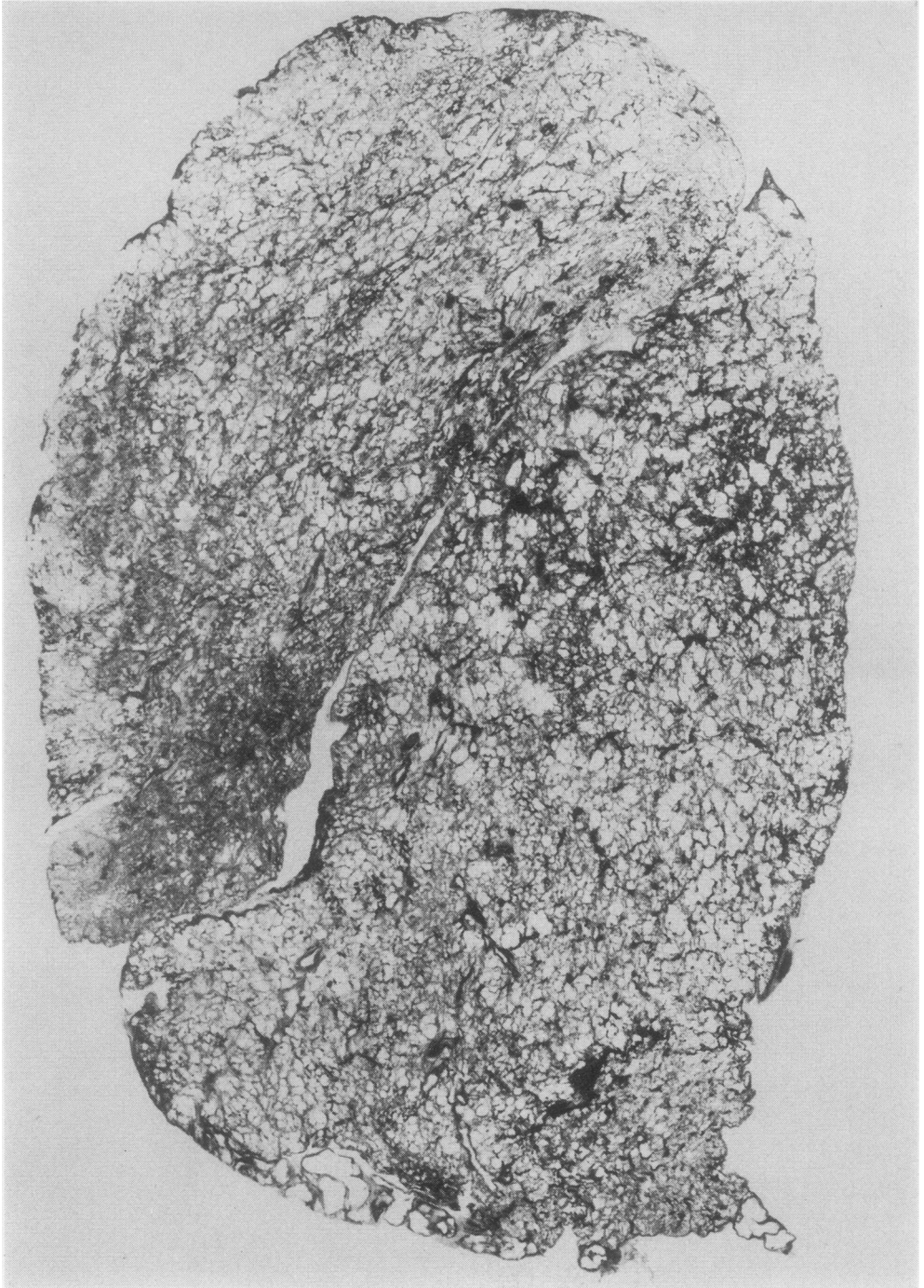


FIG. 2. *A lung from a byssinotic subject showing severe centrilobular emphysema (Gough-Wentworth  $\times 0.8$ ).*



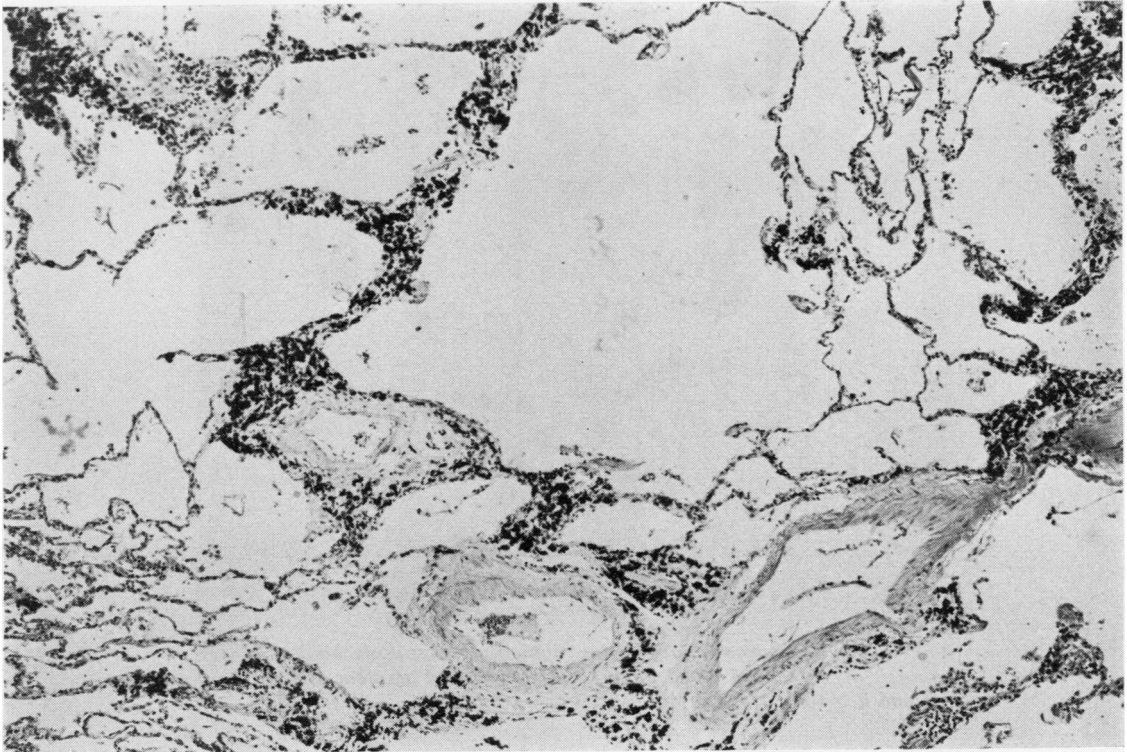


FIG. 3. Lung parenchyma showing dust pigmentation, minimal fibrosis, and dilation of distal air spaces (Haematoxylin and eosin  $\times 10$ ).

towards left or right ventricular hypertrophy, and although there were two cases of calcific aortic stenosis and two of mitral disease this was clearly fortuitous.

#### DISCUSSION

Byssinosis is unique among the dust diseases in that there are no specific physical signs or radiological appearances, and the diagnosis rests mainly on the history obtained. The standard method used to assess disability in byssinosis is the forced expiratory volume in one second (FEV<sub>1</sub>). Repeated observations have shown that inhalation of cotton dust produces a fall in ventilatory capacity since McKerrow *et al.* published their original paper in 1958. Valic *et al.* (1968) found a marked decrease in FEV<sub>1</sub> during the work shift in byssinotics. They also found that the reduction increased with the severity of the disease. El Sadik *et al.* (1972) compared the pulmonary function of byssinotics with chronic asthmatic bronchitics on the first day of the working week. The mean fall in FEV<sub>1</sub> in byssinotics was 22% for grade 1,

24% for grade 2, and 31% for grade 3 cases. By contrast, chronic bronchitic and symptom-free subjects showed a mean fall of only 3%. A response similar to that of byssinotic subjects has been found in workers exposed simultaneously to flax and hemp (Zuskin and Valic, 1973).

A fall in FEV<sub>1</sub> suggests interference with the airways at some level in these patients. We were unable to find any significant changes in the segmental bronchi in our subjects: there was no evidence of smooth muscle hypertrophy, nor of glandular hyperplasia, and the changes of an allergic type of asthma were not seen. In the major bronchi, however, there was a significant degree of muscle hypertrophy and glandular hyperplasia throughout the series. Glandular hyperplasia is, of course, consistent with chronic bronchitis, but muscular hypertrophy is not usually seen (Dunnill *et al.*, 1969) except in an apparently distinct group of patients who have 'asthmatic bronchitis' (Takizawa and Thurlbeck, 1971). Furthermore, it has been shown that in chronic bronchitics there is glandular hyperplasia in the segmental bronchi as well as in the major

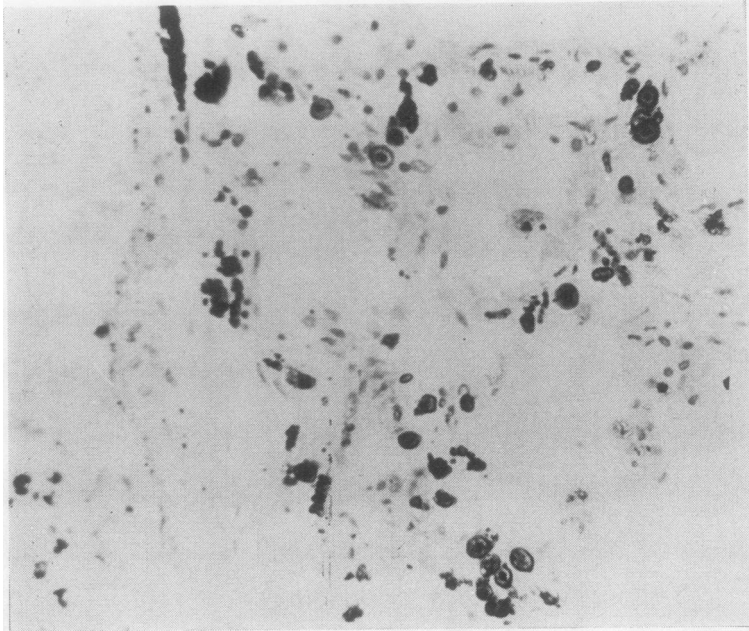


FIG. 4. Lung parenchyma showing numerous 'byssinosis bodies'. These consist of a central black nidus surrounded by a clear yellow halo (H and E  $\times 100$ ).

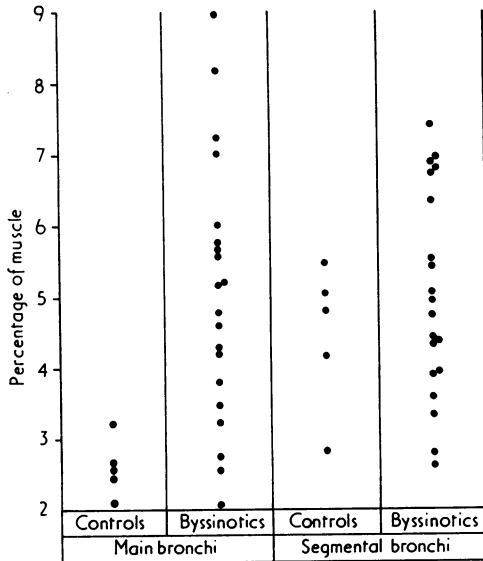


FIG. 5. Percentages of muscle in the main and segmental bronchi.

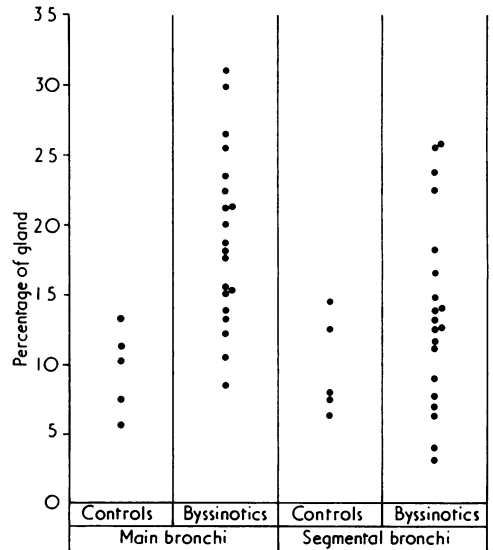


FIG. 6. Percentages of glandular tissue in the main and segmental bronchi.

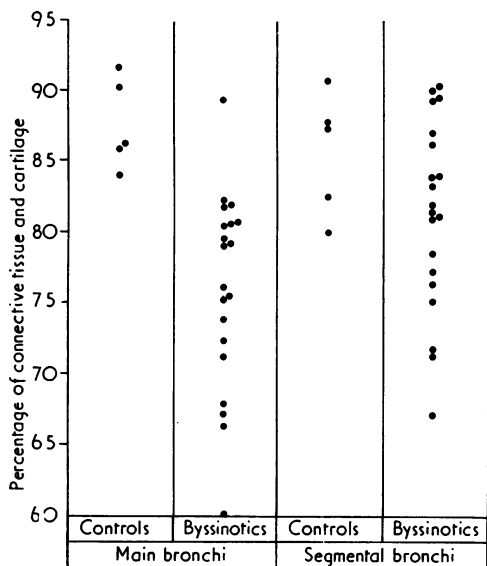


FIG. 7. Percentages of connective tissue and cartilage in the main and segmental bronchi.

TABLE I

MEANS AND STANDARD DEVIATIONS OF PERCENTAGES OF BRONCHIAL WALL COMPONENTS IN THE LOBAR BRONCHI

	Normal	Byssinotics
Muscle Mean %	2.62 (0.41)	4.96 (3.63)
Gland Mean %	9.69 (3.04)	19.04 (6.20)
Cartilage and connective tissue Mean %	87.69 (3.24)	76.00 (6.93)

Standard deviations are shown in parentheses.

TABLE II

MEANS AND STANDARD DEVIATIONS OF PERCENTAGES OF BRONCHIAL WALL COMPONENTS IN THE SEGMENTAL BRONCHI

	Normal	Byssinotics
Muscle Mean %	4.47 (1.03)	5.00 (1.48)
Gland Mean %	9.87 (3.54)	13.74 (6.77)
Cartilage and connective tissue Mean %	85.66 (4.34)	81.26 (6.67)

Standard deviations are shown in parentheses.

bronchi (Reid, 1960). It would seem that in byssinosis there is glandular hyperplasia and muscular hypertrophy in lobar bronchi but not in segmental bronchi. It may be that spasm of the

muscle of the larger bronchi is responsible for some of the symptoms.

In our series emphysema was not a constant finding. When present the predominant type was centrilobular, associated with heavy carbon pigmentation and sometimes a little fibrosis around dilated air spaces. This type of emphysema is to be expected in people exposed to a polluted industrial atmosphere, and must be regarded as a non-specific finding. It cannot be attributed to an idiosyncrasy to cotton dust, but it would be interesting to compare the lungs of cotton workers with those of the surrounding population.

In other diseases of the lung due to inhalation of organic dust it is usual to find a granulomatous reaction and interstitial inflammation in the early, acute stages. Subsequently, unless the patient is treated or removed from the source of dust, fibrosis and honeycomb change develop (Seal *et al.*, 1968). The subjects in this series were subjected to repeated exposure to cotton dust for long periods, and yet no features of an allergic type of alveolitis were found. This absence of fibrosis, other than the mild type found in the lungs of any city dweller, is a little surprising as cotton fibres are known to cause a giant-cell reaction when they lodge in small blood vessels (Kay and Wilkins, 1969).

No cotton fibres as such were seen, although the small rounded bodies described by Gough (1959) were present in seven cases. The significance of these 'byssinosis bodies' is uncertain because they are demonstrable in only a small percentage of cases, and also because similar structures are seen when there is a considerable amount of haemosiderin present, as in mitral stenosis. Electron microscopy of these bodies may be of help in resolving this problem.

Taylor and Massoud (1968) suggested that there may be interference with the pulmonary vascular bed in byssinosis. Furthermore, Vaskov (1973) found a poor pulmonary perfusion pattern on scintigrams, and postulated a narrowing or actual loss of vessels. However, our findings tend to rule out a vascular lesion; there is no significant difference between the mean right ventricular weight in the byssinotic patients and 100 consecutive cases from the East Birmingham Hospital. Furthermore, no lesions were found in pulmonary vessels apart from age change, or changes attributable to hypoxia or valvular heart disease.

Schilling, Goodman, and O'Sullivan (1952) reported that 25% of workers exposed to cotton dust in the card- and blow-rooms were hypertensive in contrast to 8% of weavers and ware-



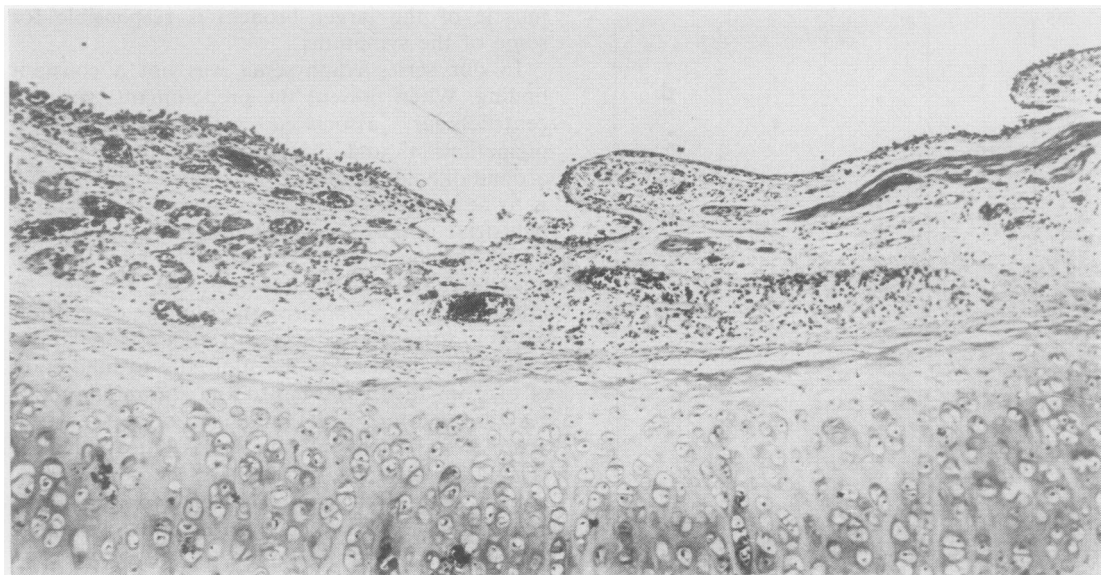


FIG. 8. A normal lobar bronchus. Note the sparse bronchial glands and smooth muscle (H and E  $\times 10$ ).

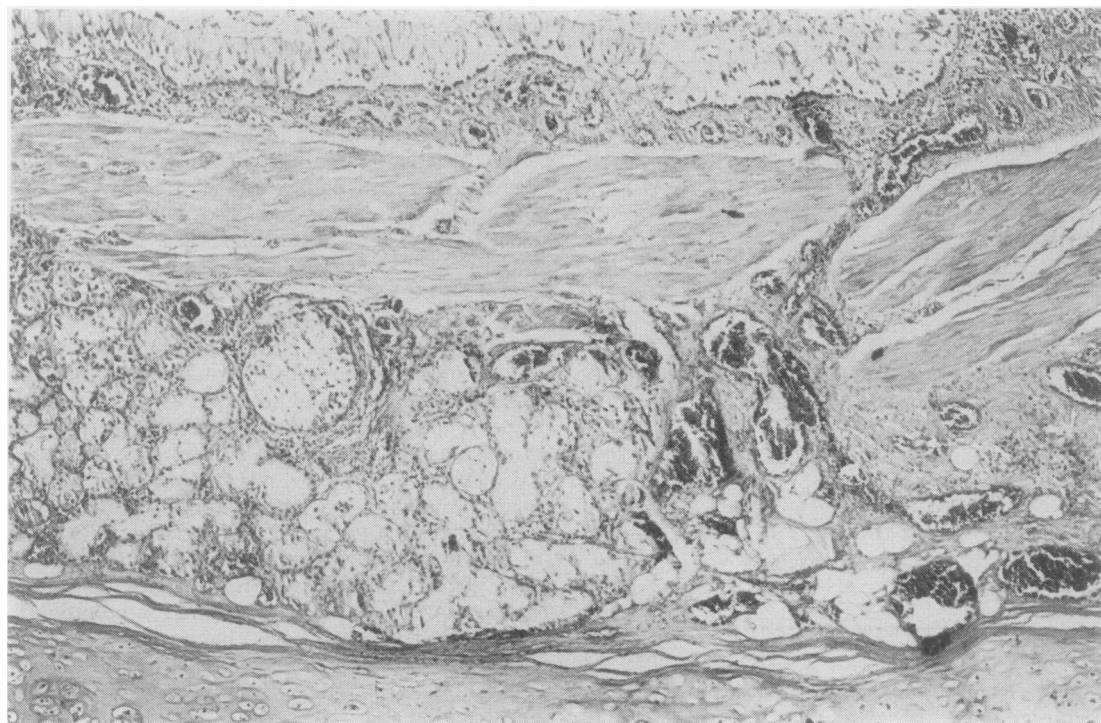

FIG. 9. A lobar bronchus from a byssinotic subject. Compared with the appearances in Fig. 8 there is thickening of the submucosa, glandular hyperplasia, and marked muscular hypertrophy (H and E  $\times 10$ ).

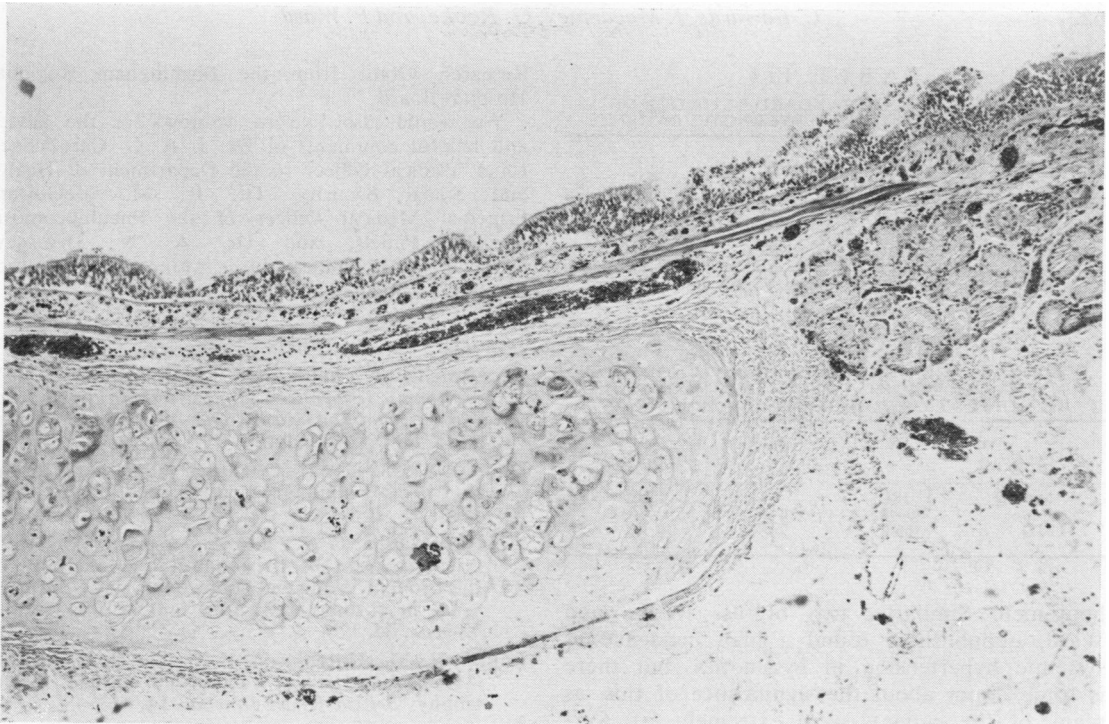


FIG. 10. *A normal segmental bronchus. Compare with Fig. 11 (H and E  $\times 10$ ).*

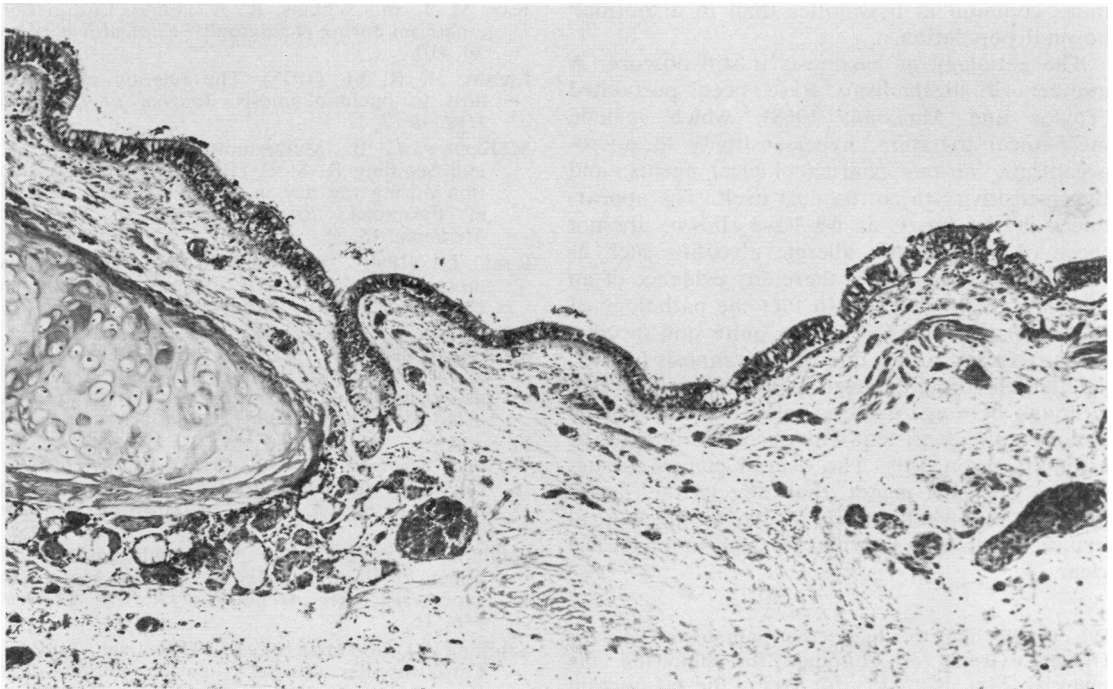


FIG. 11. *A segmental bronchus from a byssinotic subject. There is no excess of smooth muscle or gland when compared with the control bronchus in Fig. 10 (H and E  $\times 10$ ).*

TABLE III  
MEAN, RANGE, AND STANDARD DEVIATION OF  
VENTRICULAR WEIGHTS IN BYSSINOTIC PATIENTS

	LV	RV	$\frac{LV}{RV}$
Mean	171	59	3.1
Range	85-361	25-117	1.2-5.1
SD	57.5	22.6	0.892

LV = left ventricle; RV = right ventricle; weights are in grams.

TABLE IV  
MEAN, RANGE, AND STANDARD DEVIATION OF  
VENTRICULAR WEIGHTS IN 100 PATIENTS COMING TO  
NECROPSY AT THE EAST BIRMINGHAM HOSPITAL

	LV	RV	$\frac{LV}{RV}$
Mean	184	64	3.0
Range	80-425	26-180	1.6-6.4
SD	66.0	24.5	0.799

housemen. Similarly, two of us (Rooke and Ward, unpublished) found a high incidence of systemic hypertension in byssinotics, but there is some doubt about the significance of this, as many of the patients were extremely fat. Certainly the left ventricular weights in this series do not suggest that systemic hypertension is any more common in byssinotics than in a 'normal' hospital population.

The aetiology of byssinosis is still obscure. A number of mechanisms have been postulated (Taylor and Massoud, 1968), which include mechanical irritation, hypersensitivity to micro-organisms, various pharmacological agents, and hypersensitivity to cotton dust itself. The appearances in the lungs, as we have shown, are not those of an extrinsic allergic alveolitis such as farmer's lung, neither is there any evidence of an allergic type of asthma. In fact the pathology of the distal parts of the lung is quite non-specific, apart from the rather doubtful 'byssinosis bodies'. The larger bronchi appear to be severely affected, although here again the changes are non-specific and are quite consistent with chronic bronchitis or asthmatic bronchitis. The overall picture is suggestive of some agent that affects the larger bronchi, but whether this is due to mechanical irritation or some pharmacological action is not clear.

We would like to thank the pathologists of the Oldham Group of Hospitals for supplying the material, Mrs. Ruth Fry for typing the manuscript, and Mrs. Hazel Stokes and Mr. M. Chard for their technical assistance. This project was financed by a

Research Grant from the Birmingham Regional Hospital Board.

We would also like to acknowledge the advice and helpful comments of Dr. J. A. G. Carmichael, Chief Medical Officer to the Department of Health and Social Security, Dr. R. M. McGowan, Principal Medical Officer of the Pneumoconiosis Medical Panels, and Dr. A. N. Dempsey, Senior Medical Officer of the Manchester Pneumoconiosis Medical Panel.

#### REFERENCES

- Department of Health and Social Security (1973). *National Insurance (Industrial Injuries) Act 1965. Pneumoconiosis and Byssinosis*. Cmd 5443. HMSO, London.
- Dunnill, M. S. (1962). Quantitative methods in the study of pulmonary pathology. *Thorax*, **17**, 320.
- , Massarella, G. R., and Anderson, J. A. (1969). A comparison of the quantitative anatomy of the bronchi in normal subjects, in status asthmaticus, in chronic bronchitis, and in emphysema. *Thorax*, **24**, 176.
- Fulton, R. M., Hutchinson, E. C., and Jones, A. M. (1952). Ventricular weights in cardiac hypertrophy. *British Heart Journal*, **14**, 413.
- Gough, J. (1959). Occupational pulmonary disease. In: *Modern Trends in Pathology*. Butterworth, London.
- Kay, M. J. and Wilkins, R. A. (1969). Cotton fibre embolism during angiography. *Clinical Radiology*, **20**, 410.
- Landis, H. R. M. (1925). The relation of organic dust to pneumokoniosis. *Journal of Industrial Hygiene*, **7**, 1.
- McKerrow, C. B., McDermott, M., Gilson, G. C., and Schilling R. S. F. (1958). Respiratory function during the day in cotton workers: a study in byssinosis. *British Journal of Industrial Medicine*, **15**, 75.
- Reid, L. (1960). Measurement of the bronchial mucous gland layer: A diagnostic yardstick in chronic bronchitis. *Thorax*, **15**, 132.
- Ruszcwiski, Z., Zawadzki, R., Grynstajn, A., Kapuscinska, W., Ruwinski, B., Wiczorek, M., and Szozda, M. (1954). Badanie anatomiczno-patologiczne nad wpływem pyłu bawełnianego na układ oddechowy. *Polski Tygodnik Lekarski*, **8**, 1602.
- El Sadik, Y. M., Moselhi, M., El Hindady, A. R., and Mostafa, M. N. (1972). Study of lung function changes among different grades of byssinosis. *British Journal of Industrial Medicine*, **29**, 184.
- Schilling, K. (1925). Über die schädlichen Einwirkungen des Baumwollstaubes auf die Atmungsorgane. *Deutsches Archiv für klinische Medizin*, **146**, 163.
- Schilling, R., Goodman, N., and O'Sullivan, J. (1952). Cardiovascular disease in cotton workers. Part II: A clinical study with special reference to hypertension. *British Journal of Industrial Medicine*, **9**, 146.

- Seal, R. M. E., Hapke, E. J., Thomas, G. O., Meek, J. C., and Hayes, M. (1968). The pathology of the acute and chronic stages of farmer's lung. *Thorax*, **23**, 469.
- Takizawa, T. and Thurlbeck, W. M. (1971). Muscle and mucous gland size in the major bronchi of patients with chronic bronchitis, asthma, and asthmatic bronchitis. *American Review of Respiratory Disease*, **104**, 331.
- Taylor, G. and Massoud, A. (1968). Byssinosis. In: *Recent Advances in Clinical Pathology, Series V*, edited by S. C. Dyke, J. and A. Churchill, London.
- Valic, F., Zuskin, E., Walford, J., Kersie, W., and Paukovic, R. (1968). Byssinosis, chronic bronchitis and ventilatory capacities in workers exposed to soft hemp dust. *British Journal of Industrial Medicine*, **25**, 176.
- Vaskov, L. S. (1973). Use of radioisotopes in the study of textile workers with byssinosis and chronic lung damage. *British Journal of Industrial Medicine*, **30**, 37.
- Whimster, W. F. (1969). Rapid giant paper sections of lungs. *Thorax*, **24**, 737.
- Zuskin, E. and Valic, F. (1973). Respiratory response in simultaneous exposure to flax and hemp dust. *British Journal of Industrial Medicine*, **30**, 375.

Requests for reprints to: Dr. C. Edwards, Department of Pathology, East Birmingham Hospital, Bordesley Green East, Birmingham B9 5ST.