

Sarcoidosis of the upper respiratory tract and its association with lupus pernio

E. NEVILLE, R. G. S. MILLS¹, D. K. JASH,
D. M. MacKINNON, L. S. CARSTAIRS,
and D. GERAINT JAMES

Departments of Medicine and ENT Surgery, Royal Northern Hospital, London N7

Neville, E., Mills, R. G. S., Jash, D. K., MacKinnon, D. M., Carstairs, L. S., and James, D. G. (1976). *Thorax*, 31, 660–664. **Sarcoidosis of the upper respiratory tract and its association with lupus pernio.** In a series of 34 patients with sarcoidosis affecting the upper respiratory tract and nose, 26 had lupus pernio (LP) and 17 had sarcoidosis of the upper respiratory tract (SURT). In nine patients these features coexisted. A patient presenting with SURT carried a 50% risk of developing LP although one feature could be present without the other. Both were disorders of women of the child-bearing years of life. SURT, like LP, was an indicator of chronic fibrotic sarcoidosis, developing insidiously and progressing indolently over the years. It was complicated by ulceration, septal perforation, and LP. Three patients had nasal septal perforations, in two instances following submucous resection. This operation is contraindicated in patients with active sarcoidosis, particularly when granulomas are found on nasal biopsy. The Kveim-Siltzbach skin test was positive in all patients with SURT, making it invaluable in the differential diagnosis of granuloma of the nasal cavity.

Lupus pernio (LP) is a chronic, persistent, violaceous skin lesion with a predilection for nose, cheeks, and ears. Since this is a cosmetic disaster, its early recognition and possible prevention are important. Lupus pernio is a manifestation of chronic multisystem sarcoidosis (James, 1959). Sarcoidosis may also affect the mucosa of the upper respiratory tract including the nasopharynx (Boeck, 1905; Schaumann, 1936) and the larynx (Ulrich, 1918) as well as the nasal bone (Curtis, 1964). Lupus pernio is known to be associated with sarcoidosis of the mucosa of the nasal cavity (Kreibich and Kraus, 1908), but the nature of this association has hitherto been unclear. Our study is designed to clarify this relationship.

MATERIAL AND METHODS

We report a series of 34 patients with clinical and histological evidence of sarcoidosis in whom at some time in the course of the disease there was LP in 26 and sarcoidosis of the upper respiratory tract (SURT) in 17; in nine patients these features coexisted. In all 17 patients with mucosal

involvement the nasal mucosa was involved, the pharynx and larynx being affected less often.

Thirty-two of these patients were discovered in the course of a survey of patients attending our special clinic at the Royal Northern Hospital.

In order to assess the frequency of involvement of the upper respiratory tract, exhaustive examination of the upper respiratory tract was carried out by the same ear, nose, and throat surgeon on 100 successive patients attending the clinic. When necessary this clinical examination was supplemented by special radiographs, fibroscopy, audiometry, and also examination and biopsy under general anaesthesia.

Other investigations included chest radiograph, radiography of the hands, feet, and nasal bone, Kveim-Siltzbach skin test, tuberculin test, and serum and urine calcium levels. Normal serum calcium values were up to 10.5 mg/dl (2.6 mmol/l) and 24-hour urine calcium up to 300 mg (7.5 mmol).

Follow-up has been from three to 43 years with a mean of 11 years. The patients with SURT alone have a mean period of follow-up of five years.

¹Present address: Royal Free Hospital, London NW3

RESULTS

SEX, AGE AND RACE Twenty-nine of the 34 (85%) patients were female. Patients with mucosal disease presented predominantly in the third decade whereas LP presented most often in the fourth and fifth (Figure). Twenty-five (74%) of the patients were Caucasian, eight (23%) Negro, and one was a Kenyan Asian (Table I).

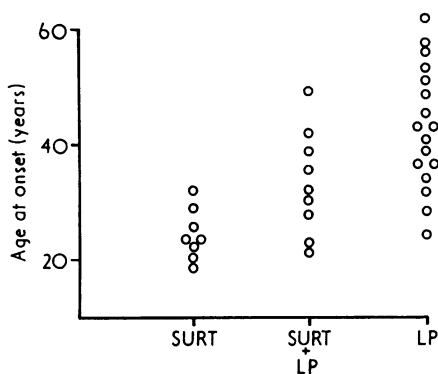


FIGURE Age of onset of patients with sarcoidosis of the upper respiratory tract (SURT), lupus pernio (LP), and both of these features.

TABLE I

CLINICAL FEATURES OF 34 PATIENTS WITH SARCOIDOSIS OF THE NOSE DISTINGUISHING LUPUS PERNIO (LP) ALONE, LP ACCOMPANIED BY SARCOIDOSIS OF THE UPPER RESPIRATORY TRACT (SURT), AND SURT ALONE

Features	LP		LP and SURT		SURT		Overall	
	No. (17)	% (100)	No. (9)	% (100)	No. (8)	% (100)	No. (34)	% (100)
Female	15	88	8	89	6	75	29	85
Age 11-30	2	12	5	56	7	88	14	41
31-40	5	30	2	22	1	12	8	24
over 40	10	58	2	22	—	—	12	35
White	14	82	6	67	5	63	25	74
Negro	3	18	3	33	2	25	8	23
Indian	—	—	—	—	1	12	1	3
Other lesions								
Intrathoracic	13	76	7	78	8	100	28	82
Skin (other than LP)	11	66	6	67	3	38	20	59
Bone	6	35	3	33	2	24	11	32
Lymphadenopathy	4	23	—	—	4	50	8	23
Ocular	6	35	1	11	—	—	7	20

LUPUS PERNIO In all 26 patients, the skin of the nose was affected, the degree of affliction ranging from small button-like lesions or a few nodules

mainly on the tip of the nose to an exuberant reaction involving all the skin of the nose and spreading across both cheeks. There were often outlying nodules or plaques on the cheeks, an eyelid was involved twice, and the pinnae of both ears twice. One patient with undoubted LP of the ear was omitted from this series since there was no involvement of the skin of the nose during our period of observation.

SARCOIDOSIS OF THE UPPER RESPIRATORY TRACT

Nasal mucosa The nasal mucosa was affected in all 17 patients with SURT. This produced obstruction, crusting, and discharge in varying degree. The septum and inferior turbinates were most commonly involved though sometimes the lesions were more widespread. The mucosa was usually erythematous and granular, and polypoid hypertrophy caused nasal obstruction; this was aggravated when stagnation and crusting led to supuration, discharge, and rarely epistaxis.

Six of the 100 sarcoidosis patients studied consecutively had SURT, in three instances accompanying LP.

Laryngeal and pharyngeal mucosa Sarcoidosis of the larynx was observed in five patients, all of whom had both nasal cavity involvement and LP, and all of whom complained of hoarseness. The laryngeal lesions consisted of either supra- or sub-glottic granulomas. No cordal lesions were seen. One patient had LP and a nasal discharge; examination revealed the combination of atrophic rhinitis, pharyngitis, and laryngitis. Another had nasal mucosal involvement but not LP at the time of appearance of the laryngeal lesion; progression to LP occurred two years later. In addition to hoarseness, this patient had marked laryngeal obstruction with stridor. Florid supra- and sub-glottic granulomas were present. The obstruction was relieved by 80 mg oral prednisolone daily, making tracheostomy unnecessary.

SURT ASSOCIATED WITH LP Of the 17 patients with mucosal sarcoidosis involving the nasal cavity, 12 (70%) presented with nasal symptoms. Within two years, six (50%) patients developed disfiguring LP. Only one patient presented with LP and two years later, when nasal mucosal biopsy was performed, was found to have SURT. Two patients simultaneously developed SURT and LP.

SURT AND SEPTAL PERFORATION Nasal septal perforation was observed in three patients; two had undergone submucous resection to alleviate obstruction at a time when nasal sarcoidosis remained unrecognized. Septal perforation complicated surgery in both, and one also developed palatal perforation. Both also progressed to LP. In these two, nasal obstruction was the only presenting symptom of the systemic disorder. No other patient had a submucous resection.

NASAL BONE SARCOIDOSIS Osteolytic nasal bone lesions were found in three of nine patients with LP and in one of four patients with SURT alone. The appearance was that of osteoporosis with punched-out lesions, as previously described (Curtis, 1964).

MULTISYSTEM INVOLVEMENT WITH SARCOIDOSIS Other manifestations of sarcoidosis in the 34 patients included involvement of lung, skin, bone, lymph nodes, and eye (Table I). Sarcoidosis had an equally insidious onset and chronic protracted course in all systems.

Intrathoracic sarcoidosis Intrathoracic involvement occurred in 28 (82%) patients (Table II). Bilateral hilar lymphadenopathy (BHL) was invariable when SURT occurred independently of LP; and chest resolution was evident in but two of eight (25%) patients. In patients with LP and pulmonary sarcoidosis, likewise, only five of 20 (25%) had eventual resolution of their chest radiographs. One of the eight patients presenting with BHL and SURT also developed pulmonary infiltration, and three of 20 patients with intrathoracic sarcoidosis and LP had progressively worsening chest radiographs.

TABLE II

CHEST RADIOGRAPHIC CHANGES IN 34 PATIENTS WITH LUPUS PERNIO (LP) AND SARCOIDOSIS OF THE UPPER RESPIRATORY TRACT (SURT)

Radiographic Stage	LP		LP and SURT		SURT		Overall	
	No.	%	No.	%	No.	%	No.	%
0	4	23	2	22	—	—	6	18
1	6	35	2	22	8	100	16	47
2	5	30	4	44	—	—	9	26
3	2	12	1	11	—	—	3	9
Total	13	77	7	78	8	100	28	82

0 = normal.

1 = bilateral hilar lymphadenopathy (BHL).

2 = BHL + pulmonary infiltration.

3 = pulmonary infiltration alone.

Other skin lesions Skin sarcoidosis other than LP was also evident in three-fifths of all patients (Table I), comprising plaques, subcutaneous nodules, and two patients each with a single purple-red toe. There were no patients with erythema nodosum.

Bone sarcoidosis Bone cysts of hands and feet were noted in 11 (32%) patients, predominantly in the group with LP; they caused pain, stiffness, and swelling which necessitated oral steroids and chloroquine.

Ocular involvement Chronic relapsing anterior uveitis was noted in seven (20%) patients, once accompanied by glaucoma and twice progressing to secondary cataract formation.

Miscellaneous tissue involvement Peripheral lymphadenopathy was noted in eight (23%) patients. Hepatomegaly was found in four patients with LP, but splenomegaly was not observed. Unilateral facial palsy of lower motor neurone type occurred in three patients with LP, but there were no other central nervous system signs. Two patients with SURT had lacrimal gland enlargement, one of whom developed LP, but parotid swelling was not seen.

INVESTIGATIONS

Kveim-Siltzbach skin test The Kveim-Siltzbach skin test was positive in all 14 patients in the series with mucosal involvement (with and without LP) but negative in six of 10 patients with LP lacking mucosal involvement (Table III).

Tuberculin test The tuberculin test was negative in 12 of 14 (86%) patients with SURT, and in four of seven (57%) patients with LP alone.

Calcium metabolism Hypercalcaemia was noted in two of 23 (7%) patients, and hypercalciuria in four of 14 (28%) patients; there was no obvious

TABLE III

SKIN TESTS IN 34 PATIENTS WITH LUPUS PERNIO (LP) AND SARCOIDOSIS OF THE UPPER RESPIRATORY TRACT (SURT)

Skin Test	LP		LP and SURT		SURT		Overall	
	No.	%	No.	%	No.	%	No.	%
Positive Kveim-Siltzbach	4/10	40	6/6	100	8/8	100	18/24	75
Negative tuberculin	4/7	57	6/7	86	6/7	86	16/21	76

relationship between LP, SURT, and abnormal calcium metabolism.

DISCUSSION

A patient presenting with sarcoidosis of the upper respiratory tract (SURT) has a 50% risk of developing lupus pernio (LP), although one feature may be present without the other. SURT occurred in 6% of patients with generalized sarcoidosis; it has previously been reported (Cowdell, 1954; James, 1956; Israel and Sones, 1958) in from 0.6% to 10% of such patients. Whereas sarcoidosis has no special sex predilection (Siltzbach *et al.*, 1974), SURT and LP are nearly six times commoner in women. The age of onset and race of the patients were, however, no different from those of sarcoidosis patients the world over, though SURT presented in a younger age group than LP.

SURT, like LP, is an indicator of chronic fibrotic sarcoidosis. It developed insidiously and progressed indolently over the years. This confirmed a previous report in which only three of 14 patients with SURT achieved resolution (McKelvie *et al.*, 1968). It is complicated by ulceration, septal perforation, and LP. It is associated with other chronic lesions—intrathoracic, skin, bone and peripheral lymphadenopathy. Intrathoracic involvement shows little tendency to resolution, only 25% of patients achieving a normal chest radiograph compared to 51% in a large worldwide series (Siltzbach *et al.*, 1974). The skin lesions consist of chronic plaques and subcutaneous nodules while bone lesions are well recognized as a long-standing complication of sarcoidosis (Sharma *et al.*, 1971).

SURT may be complicated by nasal septal or palatal perforations so submucous resection is not recommended if the original biopsy reveals sarcoid tissue. We confirm septal or palatal perforation noted in three earlier reports (Allison and Mikell, 1932; Barmwater, 1936; Lindsay and Perlman, 1951). In two of these three patients, submucous resection was also an aetiological factor.

The differential diagnosis of a sarcoid granuloma discovered on biopsy of the upper respiratory tract includes sarcoidosis, tuberculosis, Wegener's granulomatosis, and leprosy (Black, 1966). It is clearly important to make a precise diagnosis as early as possible for the course, prognosis, and treatment vary with each disease. In this respect the Kveim-Siltzbach skin test is most useful.

It is of interest that the Kveim-Siltzbach skin test was positive in all cases of SURT but in less than half of those with LP alone. It has previously been reported that the Kveim-Siltzbach skin test is less likely to be positive in patients who have had sarcoidosis for more than two years (James, Sharma, and Bradstreet, 1967). Our Kveim-Siltzbach test results underline the observation that those patients with LP alone had a later stage of sarcoidosis and had had it longer than those with SURT alone.

The Clinical Research Unit of the former North-West Metropolitan Regional Hospital Board gave generous financial support. We are grateful to the Camden and Islington Area Health Authority for continuing this support. We would like to thank all those who have referred patients to the Sarcoidosis Clinic at the Royal Northern Hospital.

REFERENCES

- Allison, J. R. and Mikell, P. V. (1932). Sarcoid associated with tuberculosis of the larynx. *Archives of Dermatology and Syphilology*, **25**, 334.
- Barmwater, K. (1936). Über Boecks Sarkoid auf den Schleimhäuten. *Hals-Nasen-und Ohrenartz, I Teil*, **27**, 259.
- Black, J. M. (1966). Sarcoidosis of the nose. *Journal of Laryngology and Otolaryngology*, **80**, 1065.
- Boeck, C. (1905). Fortgesetzte Untersuchungen über das multiple benigne Sarkoid. *Archiv für Dermatologie und Syphilis*, **73**, 301.
- Cowdell, R. H. (1954). Sarcoidosis with special reference to diagnosis and prognosis. *Quarterly Journal of Medicine*, **23**, 29.
- Curtis, G. T. (1964). Sarcoidosis of the nasal bones. *British Journal of Radiology*, **37**, 68.
- Israel, H. L. and Sones, M. (1958). Sarcoidosis: clinical observations in one hundred and sixty cases. *Archives of Internal Medicine*, **102**, 766.
- James, D. G. (1956). Diagnosis and treatment of sarcoidosis. *British Medical Journal*, **2**, 900.
- James, D. G. (1959). Dermatological aspects of sarcoidosis. *Quarterly Journal of Medicine*, **28**, 109.
- James, D. G., Sharma, O. P., and Bradstreet, P. (1967). The Kveim-Siltzbach test. *Lancet*, **2**, 1274.
- Kreibich, C. and Kraus, A. (1908). Beiträge zur Kenntniss des Boeckschen benignen Miliarlupoid. *Archiv für Dermatologie und Syphilis*, **92**, 173.
- Lindsay, J. R. and Perlman, H. B. (1951). Sarcoidosis of the upper respiratory tract. *Annals of Otolaryngology, Rhinology and Laryngology*, **60**, 549.

- McKelvie, P., Gresson, C., Pokhrel, R. P., and Jackson, P. (1968). Sarcoidosis of the upper air passages. *British Journal of Diseases of the Chest*, **62**, 200.
- Schaumann, J. (1936). Lymphogranulomatosis benigna in the light of prolonged clinical observations and autopsy findings. *British Journal of Dermatology*, **48**, 399.
- Sharma, D. P., Bailey, A. R., Carstairs, L. S., and James, D. G. (1971). Bone involvement in sarcoidosis. In *Proceedings of the Vth International Conference on Sarcoidosis*, edited by L. Levinsky and F. Machoida, p. 594. University Karlova, Prague.
- Siltzbach, L. E., James, D. G., Neville, E., Turiaf, J., Battesti, J. P., Sharma, O. P., Hosoda, Y., Mikami, R., and Odaka, M. (1974). Course and prognosis of sarcoidosis around the world. *American Journal of Medicine*, **57**, 847.
- Ulrich, K. (1918). Die Schleimhautveränderungen der oberen Luftwege beim Boeck'schen Sarkoid und ihre Stellung zum Lupus pernio. *Archiv für Laryngologie und Rhinologie*, **31**, 506.

Requests for reprints to: Dr. D. Geraint James, Royal Northern Hospital, London N7.