

Haemothorax after subclavian vein cannulation

S. HOLT, N. KIRKHAM, AND E. MYERSCOUGH

From Liverpool Regional Cardiac Centre, Liverpool L15 2HE

Holt, S., Kirkham, N., and Myerscough, E. (1977). *Thorax*, 32, 101–103. Haemothorax after subclavian vein cannulation. A patient in whom pulmonary arterial bleeding occurred during percutaneous supraclavicular puncture of the subclavian vein is described. A retrospective survey of over 600 subclavian venepunctures disclosed seven patients in whom serious traumatic complications occurred, six of them in the hands of inexperienced operators.

Opinion has differed about the safety of central venous cannulation via the subclavian vein. Yoffa (1965), using a left supraclavicular approach to the subclavian vein, indicated that this is safer, simpler, and speedier than the infraclavicular route. It has now become clear that the supraclavicular approach is not without hazard and many complications have been described. These have included pneumothorax, hydrothorax, haemothorax, massive subcutaneous emphysema, arteriovenous fistula, brachial plexus injury, and air embolism (Latimer, 1971). Because of severe and sometimes fatal complications (Schapira and Stern, 1967) abandonment of this route for central venous pressure monitoring has been advocated.

We have recently encountered a patient who developed haemothorax due to accidental pulmonary artery puncture during subclavian vein cannulation. This severe complication has not previously been described.

Case report

A 36-year-old housewife was admitted to hospital with subacute bacterial endocarditis. She had undergone aortic valve replacement with a Starr Edwards prosthesis five years previously and had been on anticoagulant therapy since that operation. Subclavian vein cannulation was performed by a percutaneous supraclavicular approach for the administration of prolonged parenteral antibiotic therapy. A central venous line was established via the right subclavian vein, but because this had blocked, the left subclavian vein had to be used. The cannulation was performed using a technique similar to that described in detail by Macaulay and Wright (1970) for the insertion of temporary transvenous pacing electrodes.

After left subclavian venepuncture with a No.

18 Seldinger needle a spring guide wire was directed through the cannula under radiographic control. Resistance to the passage of the wire was experienced and the cannula and guide wire were removed immediately. X-ray screening and clinical examination of the chest were normal and the procedure was repeated with ease, a central venous line was established, and a slow infusion of 5% dextrose was begun.

Ten minutes after the procedure the patient complained of pain in the left infrascapular region. A chest radiograph revealed patchy opacification in the left mid and lower zones of the lung fields (Fig. 1) but clinical examination of the chest was normal. She maintained satisfactory progress until seven hours after the procedure when she collapsed with tachypnoea, tachycardia, hypotension, and signs of a large left pleural effusion. A chest radiograph confirmed a pleural effusion on the side of the cannulation (Fig. 2). Intrathoracic bleeding was diagnosed and after rapid blood transfusion emergency thoracotomy was performed.

At operation 4 litres of blood were evacuated from the left hemithorax. A puncture site was noted in the left subclavian vein, and at the corresponding position on the apex of the left lung a branch of the pulmonary artery was bleeding profusely. A few fibrous pleural adhesions were present on the apical pleura and the indwelling catheter was found to be in the lumen of the left subclavian vein. Haemostasis was secured and the patient made good postoperative progress.

Discussion

Haemothorax resulting from subclavian vein damage and direct infusion of blood into the pleural space has been described after percu-

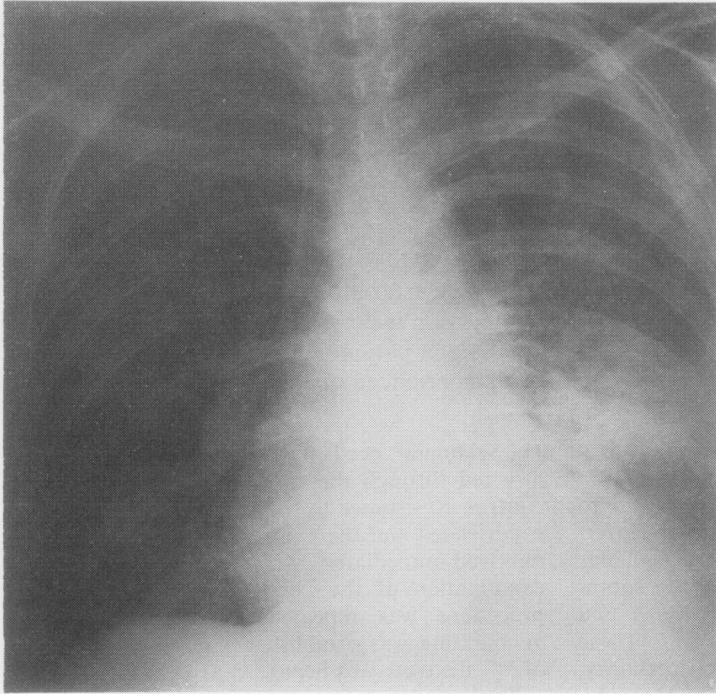


Fig. 1. *Patchy opacification left mid lower zones.*

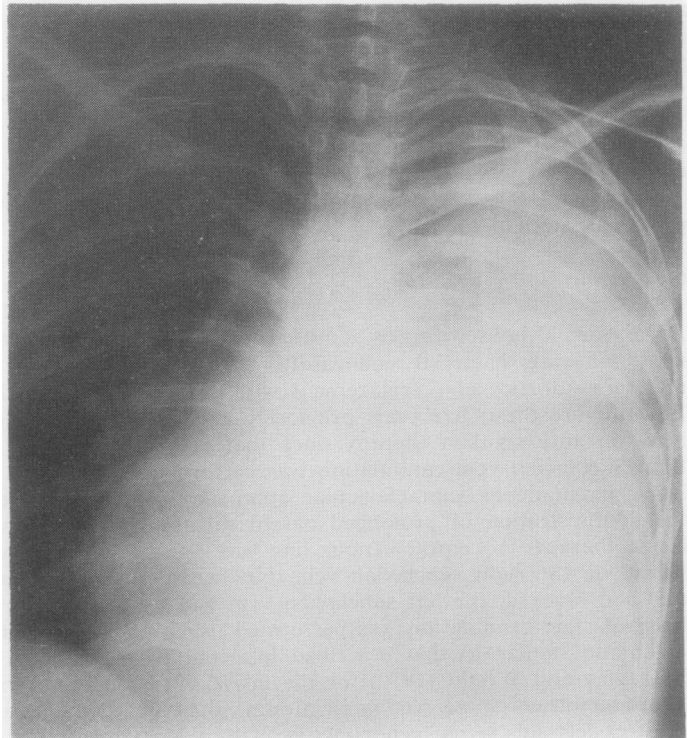


Fig. 2 *Large left pleural effusion.*

taneous subclavian vein cannulation (Smith *et al.*, 1965). Accidental puncture of the subclavian or innominate artery may occur in 2–3% of subclavian venepunctures, but it is said to be easily recognised and without sequelae (Defalque, 1968). Macaulay and Wright (1970) mentioned accidental subclavian artery puncture in one patient who was receiving anticoagulants without ill effect.

In our patient, it appears that a branch of the pulmonary artery was damaged during the introduction of the Seldinger needle or the guide wire. The factors predisposing to this were tethering of the apex of the left lung by adhesions, anticoagulation, and the presence of dilated branches of the pulmonary artery as a result of pulmonary arterial hypertension.

The supraclavicular Seldinger technique of subclavian venepuncture has been used in this department for the insertion of pacing electrodes (Macaulay and Wright, 1970), transeptal puncture of the left atrium (Epstein and Coulshed, 1971), and venoclysis. An earlier report from this unit indicated the advantages and safety of this procedure for transvenous pacing (Macaulay and Wright, 1970). In over 600 supraclavicular subclavian venepunctures performed in this unit, seven serious traumatic complications have been encountered. Pneumothorax has occurred on four occasions but in two of these patients the subclavian venepuncture had been carried out as an emergency during cardiac arrest. Hydrothorax and pneumothorax occurred together in one patient and phrenic nerve paralysis in two patients (Epstein *et al.*, 1976).

In this series, no mortality has been directly attributable to subclavian vein cannulation, but it is significant that six out of seven of these complications, as in this present case, occurred with inexperienced operators (ie, staff who have performed less than 12 supervised cannulations).

Of the subclavian cannulations reviewed in this study, it is estimated that at least 25% were done by inexperienced staff with supervision provided by senior colleagues who have skill in this procedure. The potential hazards of this useful procedure when performed by inexperienced staff should be emphasised if the incidence of serious complications is to be reduced.

We are grateful to Dr. E. J. Epstein (consultant physician) for permission to report this case.

References

- Defalque, R. J. (1968). Subclavian venepuncture: a review. *Anaesthesia and Analgesia*, **47**, 677–682.
- Epstein, E. J. and Coulshed, N. C. (1971). Transeptal catheterisation via right subclavian vein. *British Heart Journal*, **33**, 658–663.
- Epstein, E. J., Quereshi, M. S. A., and Wright, J. S. (1976). Diaphragmatic paralysis after supraclavicular puncture of subclavian vein. *British Medical Journal*, **1**, 693–694.
- Latimer, R. D. (1971). Central venous catheterisation. *British Journal of Hospital Medicine*, **5**, 369–376.
- Macaulay, M. B. and Wright, J. S. (1970). Transvenous cardiac pacing. Experience of a percutaneous supraclavicular approach. *British Medical Journal*, **4**, 207–209.
- Schapira, M. and Stern, W. Z. (1967). Hazards of subclavian vein cannulation for central venous pressure monitoring. *Journal of the American Medical Association*, **201**, 327–329.
- Smith, B. E., Modell, J. H., Gaub, M. L., and Moya, F. (1965). Complications of subclavian vein catheterization. *Archives of Surgery*, **90**, 228–229.
- Yoffa, D. (1965). Supraclavicular subclavian venepuncture and catheterisation. *Lancet*, **2**, 614–617.

Requests for reprints to: Dr. S. Holt, University Department of Therapeutics, The Royal Infirmary, Edinburgh EH3 9YW.