

Surgery of pulmonary hydatid cyst— the Barrett technique

IVAN LICHTER

Department of Surgery, University of Otago Medical School, Dunedin, New Zealand

A number of methods have been described for the surgical removal of hydatid cysts of the lung. Personal experience of the Barrett technique (Barrett and Thomas, 1952) over a number of years has made it abundantly clear that the method is widely applicable, involves the loss of no appreciable pulmonary tissue or function, and is eminently safe and free of risk of contamination of the pleural space. The technique is ideal for enucleation of all uncomplicated pulmonary hydatid cysts, even of the largest size, and after obliteration of the remaining cavity the inflated lobe looks normal. The method was therefore used wherever applicable in the present series, comprising patients treated between 1961 and 1968. The results have been compared with those of a group of patients treated in the same unit between 1952 and 1960. It is recommended that lobectomy be reserved for complicated cysts where infection has produced a chronic lung abscess or bronchiectasis, and rarely for the very largest uncomplicated cysts. All simple cysts should be enucleated by the Barrett technique.

A classic article on pulmonary hydatid disease was published by Barrett and Thomas in 1952, and the descriptions of pathology and operative technique which follow draw heavily on this source. The life cycle of the hydatid and the natural history of the growth and effects of the parasite have an important bearing on the treatment of pulmonary hydatid cysts.

THE LIFE CYCLE OF THE PARASITE

The parasite is a small tapeworm, *Taenia echinococcus*, and dogs are the usual source of infestation. The normal life cycle of the parasite is between the dog and the sheep. The dog harbours the tapeworm in its alimentary canal and its ova are excreted in the faeces. Sheep feeding in areas so infected ingest the ova, which develop into hydatid cysts in the viscera. The life cycle is completed when entrails from infected sheep are fed to dogs (Fig. 1).

Man becomes involved in this cycle when he is associated with infected dogs. The ova on his hands are ingested when eating, and in the stomach the embryos burrow through the gastric mucosa, enter radicals of the portal vein, and so reach the liver. Here they may develop into hydatid cysts, but some pass through to reach the lungs. In the lung, the embryo finally forms a hydatid cyst, where it may grow relatively quickly to produce compression

effects or suffer some complication which endangers the health or life of the host.

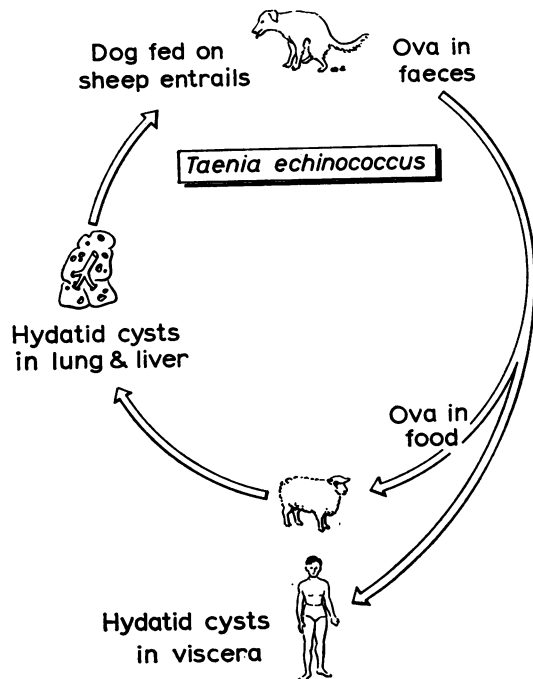


FIG. 1. Life cycle of the hydatid parasite.

Initially, the cyst may lie deeply in the substance of the lung, but as it grows, any advance towards the hilum is resisted by the unyielding broncho-vascular structures. There is, therefore, a tendency for the cysts to enlarge peripherally so that all cysts of any size finally abut upon a pleural surface, an important factor in the surgical approach to the cyst. The cyst lies within the lung substance in a cavity that grows with the enlarging parasite. There is, however, no direct fusion between the cyst and the pulmonary parenchyma so that the uncomplicated cyst can always be separated from the lung.

The bulk of the cyst consists of its contained fluid, secreted by the germinal layer of the parasite. This fluid contains brood capsules and scolices, and, if any is spilled at operation, dangerous anaphylaxis may occur or new cysts may later develop in the contaminated tissues.

The germinal layer also secretes outside it a white laminated membrane formed by the successive deposition of a number of hyalin layers, the oldest being on the outside and more stretched and brittle than those inside it. When a hydatid ruptures, therefore, the membranes immediately turn inside out, evacuating the infective contents. The laminated membrane tears very readily when perforated by a needle or grasped with forceps or when its shape is severely distorted, and once started the tear enlarges rapidly, spilling the contents of the cyst.

The 'capsule' or adventitia of the cyst is part of the host and consists of a compressed atelectatic layer of lung which may become fibrous in very large or long-standing cysts. Even when fibrous, the adventitia is quite thin, and unless infection has occurred it is sharply demarcated from the normal lung and can be readily dissected out. After the removal of a hydatid cyst the adventitial scar disappears within a short period of time.

The growing cyst usually does little damage to the lung and may enlarge to 10 cm in diameter in two years. It displaces bronchi but, even when large, usually produces only small lateral fistulous communications between the bronchi and the cyst space. As the cyst enlarges it reaches the pleural surface, sometimes in one of the fissures or on the diaphragmatic surface of the lung. Here it shows at first as a prominence, grey at its apex where the atelectatic adventitia presents, but later bluish or pearly white when the adventitia thins out, exposing the laminated membrane. The cyst produces no pleural reaction unless there has been surrounding pneumonitis. Permanent inflammatory changes in the lung are common.

The characteristics described in this outline indicate the feasibility of total enucleation of the intact cyst.

THE BEHAVIOUR OF THE HYDATID CYST

The lesion usually remains silent until some complication overtakes the parasite. Many cases present to the surgeon with a circumscribed opacity found on radiological examination. However, the presence of a hydatid cyst is a constant threat to the patient, for rupture of the cyst may occur at any time, followed not infrequently by death from anaphylaxis or suffocation. If death does not ensue, there will be inevitable formation of a chronic lung abscess due to the retention of cyst membranes within the lung cavity. It is, therefore, mandatory to remove hydatid cysts on diagnosis. Because even large uncomplicated cysts produce little permanent pulmonary damage, resection of lung is seldom necessary and the surgeon is able to remove the parasite without the sacrifice of any host tissue.

Barrett (1949) first described an operation which allows of the removal of the parasite intact and therefore avoids contamination by spillage of infected fluid. Operations involving puncture of the cyst and aspiration even with a fine needle may result in leakage and contamination. It is true that, even with known spillage, no secondary hydatid disease follows in 90% of cases, and this may account for the acceptance of methods that do not guarantee against contamination of tissues. The Barrett technique avoids the disastrous results of disseminated disease that may occur in the other 10% of patients. With slight modification this is the method described by Barrett and Thomas (1952):

Under general anaesthesia a cuffed endotracheal tube is inserted. The head of the table is lowered so that if the cyst accidentally ruptures into the bronchus the fluid will drain from the lungs by gravity. Hydrocortisone is kept at hand for immediate intravenous injection as deaths from anaphylaxis have been reported from accidental intrapulmonary rupture. The hemithorax is widely opened by an incision placed at about the level of the middle of the cyst. If pleural adhesions are present they are divided so that the lobe containing the cyst is free. The operative field is protected by means of a plastic sheet laid under and about the lobe. The adventitia of the cyst will usually be seen on the surface of the lung as a patch of white membrane. If the hydatid has not grown quite to the surface, the lung over the cyst is incised along one of the intersegmental planes and down to the adventitia.

The adventitia is partially incised by a straight incision, the length of which should be about the same as the diameter of the cyst, and placed towards the bottom of the cyst as the patient lies on the table. The incision must be made cautiously, because the adventitia of the cyst is usually very thin. The object is to form a crack in the adventitia and not to expose the laminated membrane throughout the length of the incision. When the laminated membrane is exposed at any point it will be recognized by its pale blue colour. When the laminated membrane has been exposed in one spot, the adventitia is lifted off the cyst and the opening is quickly enlarged by cutting the adventitia in several directions with blunt pointed scissors. This must be done promptly so that the cyst does not extrude through too small an opening with consequent compression and rupture. The cyst will now begin to herniate out of the lung and nothing must be touched until it has been completely extruded. Grasping or even touching the laminated membrane or the adventitia may lead

to rupture of the cyst. The anaesthetist inflates the lungs and the hydatid is gradually extruded from the lung intact as the slender tissues over the cyst are stretched and torn, exposing an increasing area of the dome of the cyst; air escapes from tiny bronchi in the adventitia and propels the cyst from its capsule. As the cyst is about to be expelled from the lung, the table is tilted to allow it to roll gently into a dish. The steps of the operation are illustrated in Figs. 2 a-g.

When there has been a small partial rupture of the cyst with infection within its capsule, dissection can be carried out in the plane between the adventitia and the surrounding normal lung, so that the parasite is taken out together with the capsule formed by the atelectatic lung and fibrous tissue which surrounds it. This is possible because the capsule is sharply demarcated from the surrounding lung, and an avascular plane of cleavage can be found.

After enucleation of the cyst one or more lateral bronchial fistulae are usually present, opening into

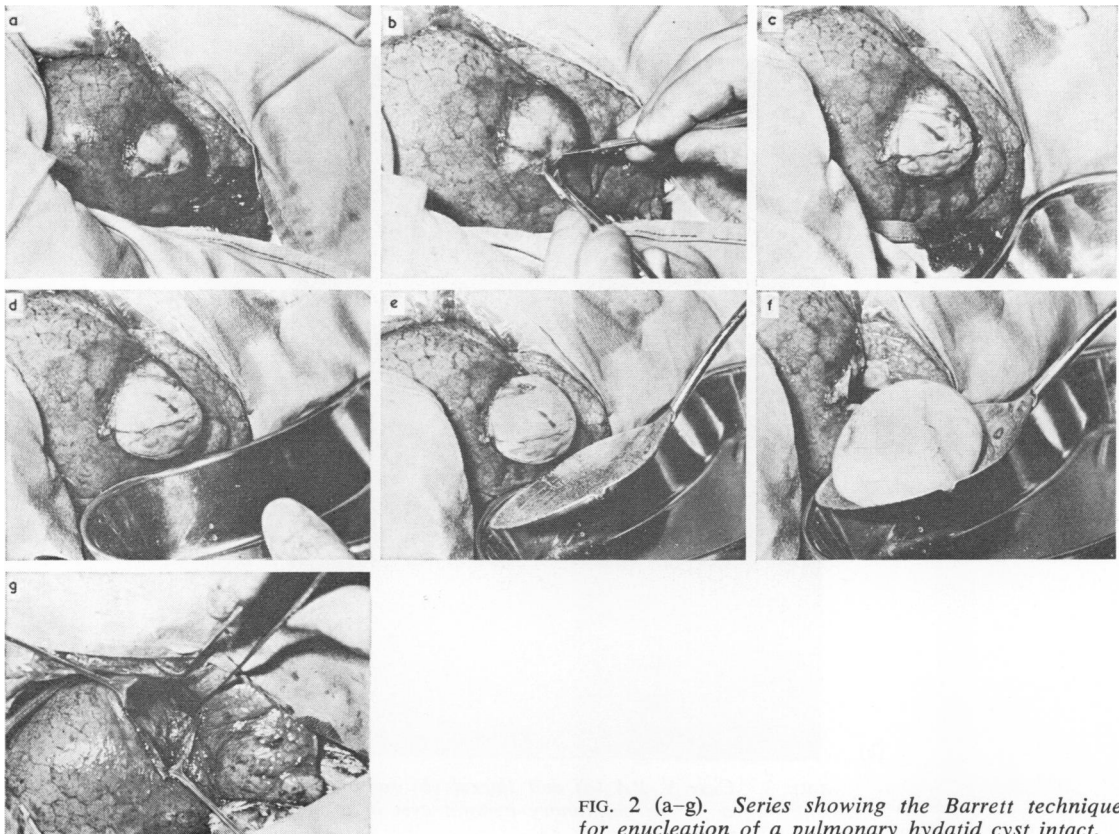


FIG. 2 (a-g). Series showing the Barrett technique for enucleation of a pulmonary hydatid cyst intact.

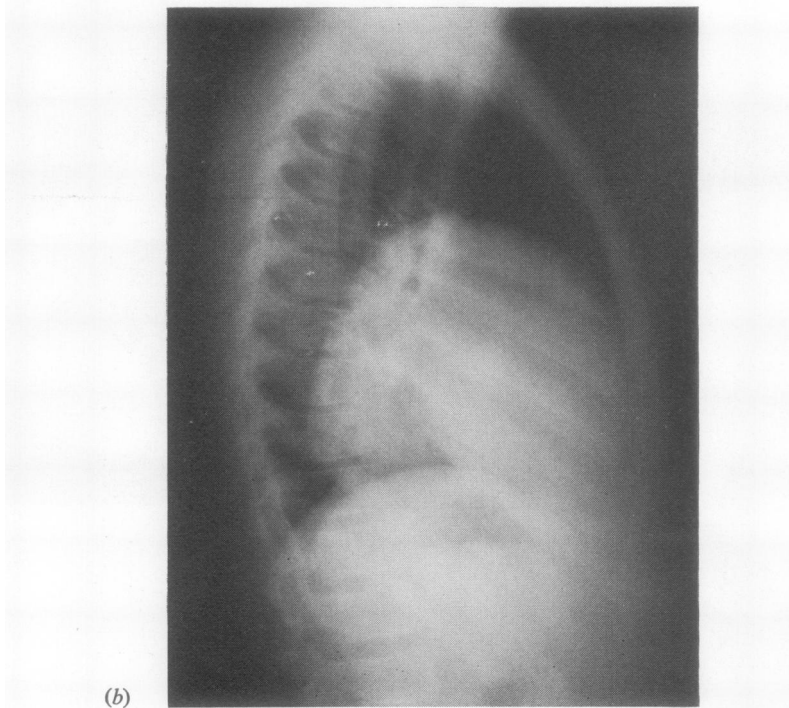
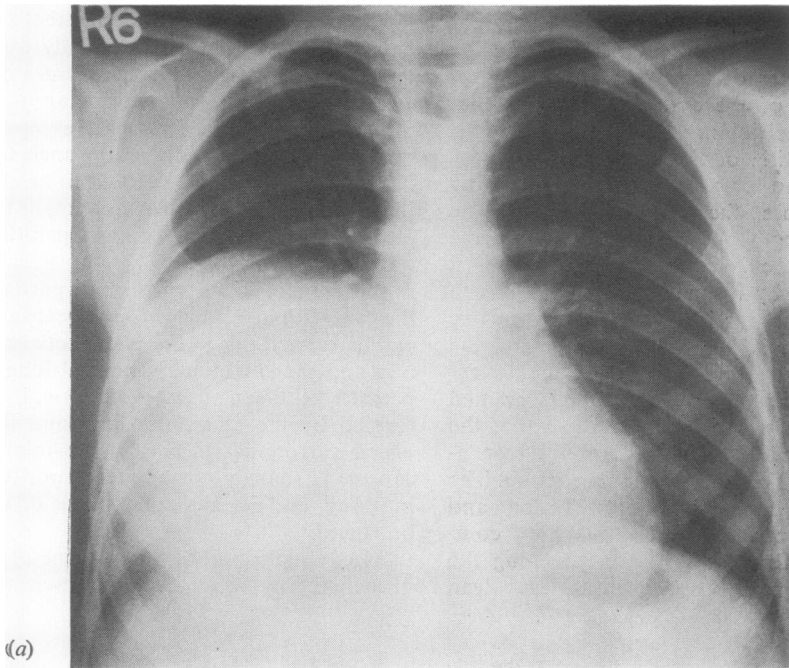


FIG. 3. *Case 1. PA (a) and lateral (b) radiographs showing a 12 cm pulmonary hydatid cyst in a child aged 7 years.*

the walls of the space. These are closed to prevent the development of tension pneumothorax and possibly an empyema. The residual space is then obliterated by a series of purse-string sutures, starting at the base of the space, so as to avoid the later development of a cavity filled with blood or exudate or the formation of a tension cyst. In small cysts the wall of the cavity consists of compressed atelectatic lung tissue, but in larger cysts it is fibrous. In the latter case Barrett recommends excision of the adventitia and closure of the main segmental bronchus after enucleation of the cyst. This has not proved necessary in the present series even with the larger cysts. True bronchiectasis due to bronchial obstruction by the hydatid may be present at the time of operation. In this rare event lobectomy should be considered.

ILLUSTRATIVE CASES

CASE 1 A child aged 7 years had been in failing health for over a year. He was admitted with a pulmonary shadow which was increasing in size (Fig. 3a, b), a pleural effusion, and a raised temperature. A 12 cm hydatid cyst was removed intact from the right middle

lobe by the Barrett technique. There was no infection within the capsule. He has enjoyed excellent health since.

CASE 2 A child aged 5 years presented with a chest wall deformity that had been noted two months earlier. For a long time previously she had become dyspnoeic on moderate exertion and there had been episodes of wheezing, especially on exercise. A chest radiograph showed a large mass filling the left hemithorax (Fig. 4), displacing the mediastinum to the right, indenting the lower trachea and narrowing the left stem bronchus. At operation the cyst was adherent to the parietes and mediastinum from which it was freed. The cyst, 16 cm in diameter and occupying almost the whole of the hemithorax, was removed intact by the Barrett technique. After enucleation of the cyst, the left upper lobe was seen to be fibrosed, atelectatic, and functionless and was therefore resected.

RESULTS

The experience in our unit comprises 44 intrapulmonary hydatid cysts in patients treated between 1952 and 1960, and 14 treated between 1961 and 1967. Twenty-seven of the first series were treated by aspiration and evacuation of the cyst, one by

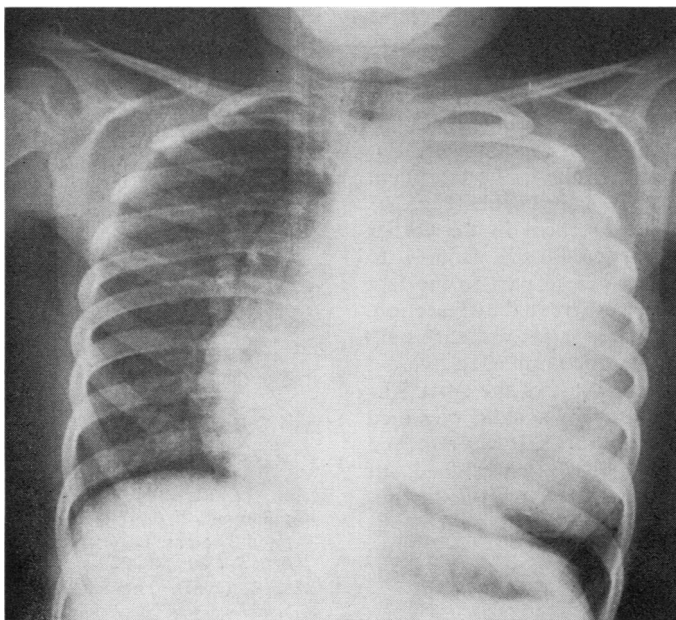


FIG. 4. Case 2. Radiograph showing 16 cm pulmonary hydatid cyst in a child aged 5. The mass fills the left hemithorax, displacing the mediastinum and indenting the lower trachea and narrowing the left stem bronchus.

TABLE
TREATMENT OF 14 HYDATID CYSTS

<i>Simple cysts (9)</i>					
Barrett technique	6
Barrett technique and resection	1
Evacuation of cyst	1
No treatment	1
<i>Complicated cysts (5)</i>					
Acute rupture into pleural cavity					
Lobectomy	2
Intrapulmonary rupture					
Evacuation of cyst	1
Segmental resection	1
Partial rupture with infection					
Barrett technique	1

excision of the cyst with its adventitia, 13 by resection, and three were not treated surgically. Between 1961 and 1967 we dealt with 14 cysts in 13 patients (Table). Two of these cysts had ruptured into the pleural space and were treated by lobectomy. There has been intrapleural recurrence in one requiring further operation. One complicated cyst, old, collapsed, and calcified, was treated by segmental resection, and two in one patient by evacuation of the cyst (by another surgeon). The remainder were treated by the Barrett technique. One of these was in fact infected, but after extrusion of the cyst the cavity was cleared of infected material and obliterated by suture. The cysts varied in size from 5 to 16 cm in diameter, eight being 10 cm and over. Of the eight cysts removed by the Barrett technique, five were 10 cm in diameter and over, the largest being 16 cm in diameter. The remainder were 3, 5, and 7 cm in diameter. For simple cysts the Barrett technique is the treatment of choice and is almost always applicable (Fig. 2).

While there were no recurrences in the earlier series where the cysts ranged in size from 1 to 10 cm, this may have been due in part to the fact that one-third of the cases were treated by resection. A notable feature of the later series was that only one resection was done for uncomplicated hydatid cyst despite the large size of some of the cysts. The cyst that required lobectomy in a child occupied almost the whole of the hemithorax. It was removed intact but the remaining lobe was so thinned out as to be functionless (case 2). No cysts were ruptured during removal and there is thus no possibility of recurrence. In the two series there has been no residual cavity formation nor bronchiectasis after the conservative type of operation.

DISCUSSION

Nicks (1967) reported 112 patients with thoracic hydatid cysts. Fifty-eight were simple cysts, 24 had ruptured into a bronchus (15 acute and 9 subacute), and there were 10 intrapleural ruptures.

Within five years of treatment there were 11 recurrences, seven having occurred in the period before 1955 when the recurrence rate had been 20%. The reduction in the recurrence rate to about 5% in the more recent series was ascribed to 'more stringent precautions against spillage and implantation, together with careful bronchial suture and capsular obliteration'. As only about 10% of spillages lead to recurrences, a 5% recurrence rate indicates contamination in 50% of cases. The figures given do not indicate what proportion of recurrences occurred in patients who had complicated cysts, or how many followed spillage from a simple cyst.

No simple cyst removed by the Barrett technique can recur as a result of spillage except in the event of accidental rupture, an accident that should be very infrequent. Nicks advocates the use of the Barrett technique only for small cysts. Larger cysts are punctured and emptied using a gallbladder trochar and cannula.

Barrett states that his method is suited to the treatment of hydatid cysts that are not too large and that, in his experience, the chances of getting out a cyst the size of a grapefruit in this way are not good. The two cases described lead one to believe that there is perhaps no limit to the size of the cyst that can be removed intact by this method, and its use for any size of cyst is recommended. In case 2 lobectomy could not have been accomplished without rupture of the cyst, and its preliminary removal avoided contamination and allowed an accurate assessment of damage to the lobe. In most cases such assessment makes it clear that lobectomy is not necessary.

REFERENCES

- Barrett, N. R., (1949) Removal of simple univesicular pulmonary hydatid cyst. *Lancet*, 2, 234.
 —, and Thomas, D. (1952). Pulmonary hydatid disease. *Brit. J. Surg.*, 40, 222.
 Nicks, R. (1967). Thoracic hydatid cysts. *Med. J. Aust.*, 1, 999.