

Inappropriate antidiuretic hormone secretion in oat-cell carcinoma of bronchus

Aggravation of hyponatraemia by intravenous cyclophosphamide

A. H. G. MUNRO and G. K. CROMPTON¹

*Respiratory Diseases Unit, Northern General Hospital, Edinburgh and
Department of Respiratory Diseases, University of Edinburgh*

A patient with hyponatraemia associated with an oat-cell carcinoma of the bronchus is described. Treatment with intermittent large doses of cyclophosphamide intensified the hyponatraemia. An explanation of this previously undescribed phenomenon is suggested.

Hyponatraemia associated with bronchial carcinoma was first described by Winkler and Crankshaw (1938). Schwartz, Bennett, Curelop, and Bartter (1957) suggested that the hyponatraemia was due to 'inappropriate' secretion of anti-diuretic hormone (ADH) by the tumour itself. Confirmation of this was provided by Lee, Jones, and Barraclough (1964) when a substance with an action resembling that of ADH was isolated from tumour tissue. The syndrome appears to be associated exclusively with the oat-cell type of carcinoma, but Azzopardi, Freeman, and Poole (1970) described a case which may have been due to a squamous carcinoma. Because oat-cell carcinoma tends to disseminate early, by either blood or lymphatic spread, most patients with inappropriate secretion of ADH are first seen at a stage when surgical resection of the tumour or curative treatment with deep x rays is impossible. Linton and Hutton (1965) reported a case in which treatment with nitrogen mustard was followed by reversal of the electrolyte disturbances and suggested that cytotoxic drug therapy might be a useful form of palliative treatment in this condition. In the case reported here, hyponatraemia was intensified by treatment with cyclophosphamide given in intermittent high doses.

CASE REPORT

A 37-year-old labourer was admitted to hospital complaining of increasing dyspnoea, cough, and haemoptysis of two months' duration. He had lost a stone (6.4 kg) in weight and had latterly experienced dysphagia.

On examination stridor was audible at rest. The veins of the upper limbs and neck were distended. There was dullness to percussion and diminished air entry over the right lower lobe. A small firm lymph node was palpable in the right supraclavicular fossa. The chest x-ray showed cardiomegaly, elevation of the right hemidiaphragm, and collapse of the right lower lobe with a small pleural effusion. At screening the right hemidiaphragm moved paradoxically on sniffing and no cardiac pulsation was visible. Barium swallow showed compression and displacement of the oesophagus by enlarged mediastinal lymph nodes over a distance of 15 cm. The oesophageal lumen was almost totally occluded immediately below the level of the tracheal bifurcation. Bronchoscopy revealed widening of the main carina and narrowing of the right main bronchus. A biopsy taken from within the stenosed bronchus had the histological features of oat-cell carcinoma.

Treatment with a single intravenous 3-g dose of cyclophosphamide relieved the superior vena caval obstruction and dysphagia within 48 hours. Rapid radiographic improvement occurred, normal heart size and pulsation were restored, the oesophageal compression was substantially improved, and the pleural effusion resolved. Fifteen days after admission the patient was discharged home free from symptoms.

Four further doses of cyclophosphamide, each 2 g, were given at approximately four-week intervals. Each treatment necessitated admission to hospital for 48 hours. The patient remained entirely well for five months but was then readmitted, having apparently inhaled vomit during a fit. He died shortly after admission.

Necropsy confirmed the presence of an oat-cell carcinoma of the right lower lobe bronchus extending into the lung and mediastinum, with invasion of the left atrium and partial occlusion of the superior vena cava. There was, however, no evidence of metastatic spread to the brain. The left lung and the

¹ Requests for reprints should be sent to Dr. G. K. Crompton

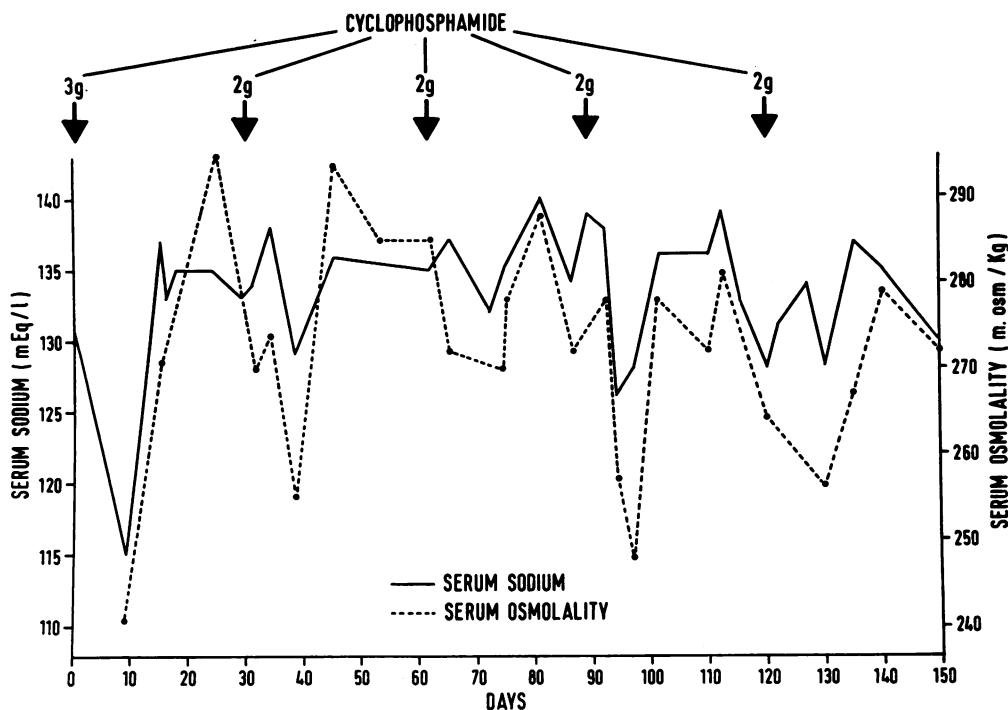


FIGURE. Effect of cyclophosphamide on serum sodium and serum osmolality.

portion of the right lung not invaded by tumour were grossly oedematous.

Before treatment was started the serum sodium was slightly subnormal at 131 mEq/l. (normal range for our laboratory 135–145 mEq/l.) The first injection of cyclophosphamide was followed by progressive hyponatraemia maximal after 10 days when the serum sodium was 113 mEq/l. (Figure) A rapid return to normal levels ensued and at no time were symptoms of hyponatraemia experienced by the patient. Similar, though less dramatic, changes occurred after subsequent doses of cyclophosphamide and there were corresponding fluctuations in serum osmolality (normal range 280–288 m. osm/kg). Latterly, the serum sodium and osmolality were more consistently depressed and altered little following the last dose of cyclophosphamide.

On each occasion the serum sodium was estimated the other electrolytes and urea were measured. At no stage were the serum potassium, bicarbonate or urea abnormal but the chloride was 93 mEq/l. initially and fell to 83 mEq/l. on the tenth day after the first injection of cyclophosphamide (normal range for serum chloride for our laboratory 95–105 mEq/l.) When the second treatment was given the serum chloride had returned to within the normal range and thereafter only occasional slightly low values were recorded at times when the serum sodium was abnormal. (Tabulated

data are available on application to the author.) Morning and evening basal plasma cortisol levels were normal, as was the increase in plasma cortisol following the administration of ACTH. A sample of tumour tissue obtained at necropsy contained 100 $\mu\mu$ of ADH activity/mg of dry tumour. This value is 15 to 20 times greater than normal.

DISCUSSION

We have established that our patient had hyponatraemia associated with an oat-cell carcinoma of the bronchus, which contained a substance with ADH activity. It seems unlikely that the electrolyte disturbance was due to drug therapy alone, and this is supported by our experience of other patients treated with large intravenous doses of cyclophosphamide. The treatment did not cause vomiting and this can be excluded as a cause of sodium loss in this patient.

Electrolyte details before and after 3 g cyclophosphamide are available for seven other cases (5 bronchial, 1 breast, and 1 kidney carcinoma). No significant changes occurred in any patient. The mean values for the group before treatment were: sodium 137 mEq/l., potassium 4x4 mEq/l. chloride 100 mEq/l., bicarbonate 26 mEq/l.,

and urea 36 mg%. After therapy, the mean values were: sodium 136 mEq/l., potassium 4 mEq/l., chloride 98 mEq/l., bicarbonate 26 mEq/l., and urea 37 mg%.

We suggest that the profound but transient hyponatraemia which followed cytotoxic chemotherapy was due to a massive release of ADH-like polypeptides from damaged tumour cells. This phenomenon has not been reported previously but it must now be recognized as a potential hazard when patients with an ADH syndrome are treated with cytotoxic drugs. A similar effect might be anticipated after radiotherapy if the hypothesis we have put forward is valid. It is interesting to speculate that an analogous response might be evoked by treatment with cytotoxic drugs or deep x rays of bronchial carcinoma associated with other non-metastatic endocrine syndromes.

In the case reported here the increase in hyponatraemia which followed each dose of cyclophosphamide was taken to indicate that the drug was producing tumour cell destruction or damage. If this is so, serial estimations of serum sodium or osmolality could perhaps be used to monitor a response to cytotoxic drugs or deep x rays of ADH-secreting tumours. This case report also raises the question whether an isolated normal serum sodium estimation necessarily excludes ADH activity in a bronchial carcinoma. The serum sodium before the first dose of cyclo-

phosphamide was only slightly below the normal range but subsequent treatments with this drug were followed by reductions in serum sodium and osmolality from normal to significantly subnormal values. This observation suggests that electrolyte studies after the administration of a large dose of a cytotoxic drug to patients with oat-cell tumours might show that the production of ADH by these tumours is a less rare phenomenon than is at present believed.

We are grateful to Professor J. Lee, Charing Cross Medical School, for performing the tumour assay, to Dr. J. M. Drennan and Dr. J. N. Webb for the necropsy and biopsy reports, and to Miss I. A. McCall for secretarial assistance.

REFERENCES

- Azzopardi, J. G., Freeman, E., and Poole, G. (1970). Endocrine and metabolic disorders in bronchial carcinoma. *Brit. med. J.*, **4**, 528.
- Lee, J., Jones, J. J., and Barraclough, M. A. (1964). Inappropriate secretion of vasopressin. *Lancet*, **2**, 792.
- Linton, A. L., and Hutton, I. (1965). Hyponatraemia and bronchial carcinoma; therapy with nitrogen mustard. *Brit. med. J.*, **2**, 277.
- Schwartz, W. B., Bennett, W., Curelop, S., and Bartter, F. C. (1957). A syndrome of renal sodium loss and hyponatraemia probably resulting from inappropriate secretion of antidiuretic hormone. *Amer. J. Med.*, **23**, 529.
- Winkler, A. W., and Crankshaw, O. F. (1938). Chloride depletion in conditions other than Addison's disease. *J. clin. Invest.*, **17**, 1.