

Postoperative lobar torsion and gangrene

MICHAEL V. KELLY II, E. ROSS KYGER, AND WARREN C. MILLER

From the Departments of Surgery and Medicine, University of Texas Medical School at Houston, Houston, Texas 77030, USA

Kelly, M. V., Kyger, E. R., and Miller, W. C. (1977). *Thorax*, 32, 501-504. Postoperative lobar torsion and gangrene. Following left upper lobectomy for a pulmonary nodule, complete 180-degree torsion of the left lower lobe with haemorrhagic infarction occurred. Despite re-exploration within 24 hours of the initial procedure the patient died. Postoperative torsion requires early diagnosis and resection of the gangrenous tissue.

Torsion of the lung, or one of its lobes, with the development of gangrene is fortunately a rare event. It has occurred spontaneously in an accessory lobe and after chest trauma, hiatal herniorrhaphy, and resection of pulmonary segments or lobes (Schuler, 1973). We have recently observed such a complication after a left upper lobectomy in a patient with impressively rapid clinical deterioration.

Case report

A 65-year-old woman with essential hypertension was admitted to hospital because of syncopal episodes associated with antihypertensive therapy. Adjustment of her drug regime eliminated the presenting complaint. However, a routine chest radiograph showed a small density in the left upper lobe (Fig. 1). No previous chest radiographs were available for comparison. Tomography confirmed the presence of a non-calcified nodule and revealed a smaller adjacent nodule. There was slight fibronodular streaking in the lung and scattered hilar calcification suggestive of previous granulomatous disease. Skin reactivity to intermediate strength PPD was negative. Fibreoptic bronchoscopy showed no abnormality. Pulmonary function studies indicated adequate reserve for lobectomy. There were no malignant cells in the sputum, but the lack of calcification and indistinct margins of the mass were suspicious of malignancy. During thoracotomy two well-delineated masses were readily palpable deep within the pulmonary parenchyma, precluding wedge resection. Left upper lobectomy was accomplished without difficulty. Histological examination showed multiple granulomata. No organisms were seen.

The initial postoperative course was uneventful. A chest radiograph showed good expansion of the left lower lobe (Fig. 2). Vital signs were stable. On 40% inspired oxygen, arterial blood gases were PaO_2 187 mmHg (24.9 kPa) and Paco_2 38.5 mmHg (5.1 kPa). The next morning moderate hypotension and tachycardia developed but responded favourably to fluid therapy. A radiograph showed complete opacification of the left chest (Fig. 3). Breath sounds were diminished on the left. The chest tubes were functioning, and there was no air leak or blood loss. A diagnostic thoracentesis failed to obtain fluid. Bronchoscopy revealed the left upper lobe suture line to be intact. The orifice to the left lower lobe was oedematous, distorted, and narrowed. No evidence of aspiration of gastric contents was seen. Despite these marked changes, arterial blood gases on 40% inspired oxygen were PaO_2 163 mmHg (21.7 kPa) and Paco_2 36.8 mmHg (4.9 kPa). Her clinical condition progressively deteriorated, and so vasopressor drugs were administered. Because of the suspicion of lobar torsion, she underwent a second exploratory thoracotomy within 24 hours of the first procedure and within 12 hours of the appearance of tachycardia. A foul odour was apparent as the incision was re-opened. Complete 180-degree torsion of the left lower lobe was present with occlusion of the bronchovascular bundle at the hilum. The lung tissue was heavy and boggy with a blue-black haemorrhagic appearance (Fig. 4). The lobe was rapidly removed. As the chest was being closed, cardiac arrest occurred. Despite open-chest cardiac massage and drug therapy she could not be resuscitated and was pronounced dead in the operating room.

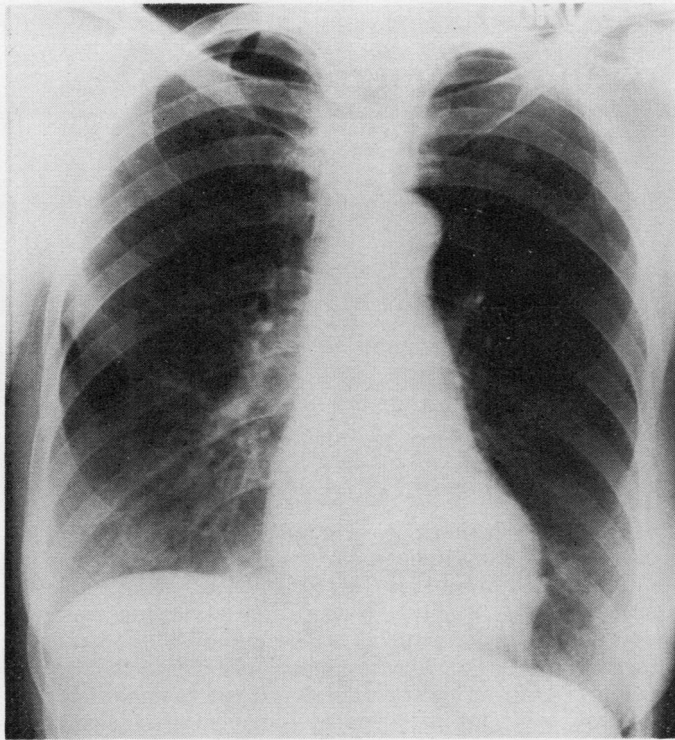


Fig. 1 *Preoperative chest radiograph showing a left upper lobe nodule.*

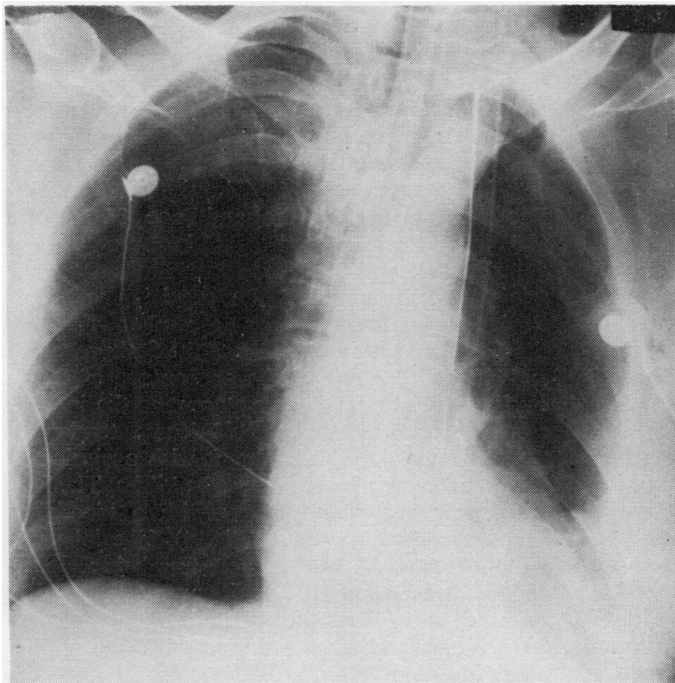


Fig. 2 *Immediate postoperative chest radiograph showing good expansion of the left lower lobe.*

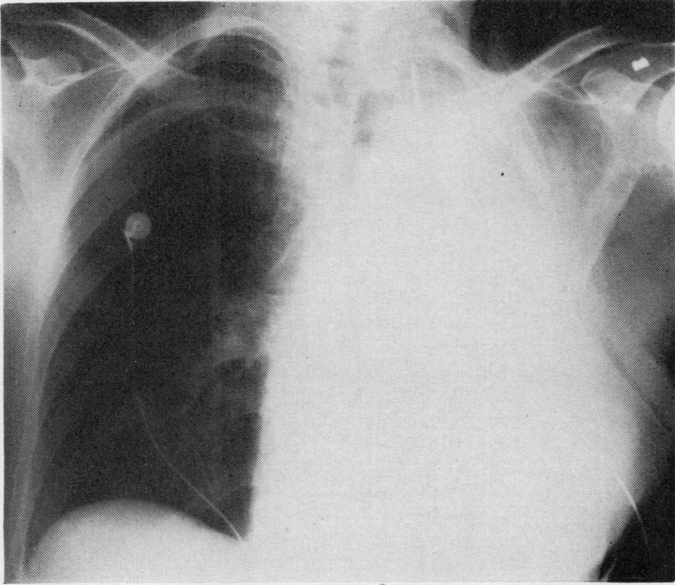


Fig. 3 Chest radiograph taken approximately 12 hours after operation showing complete opacification of the left chest.

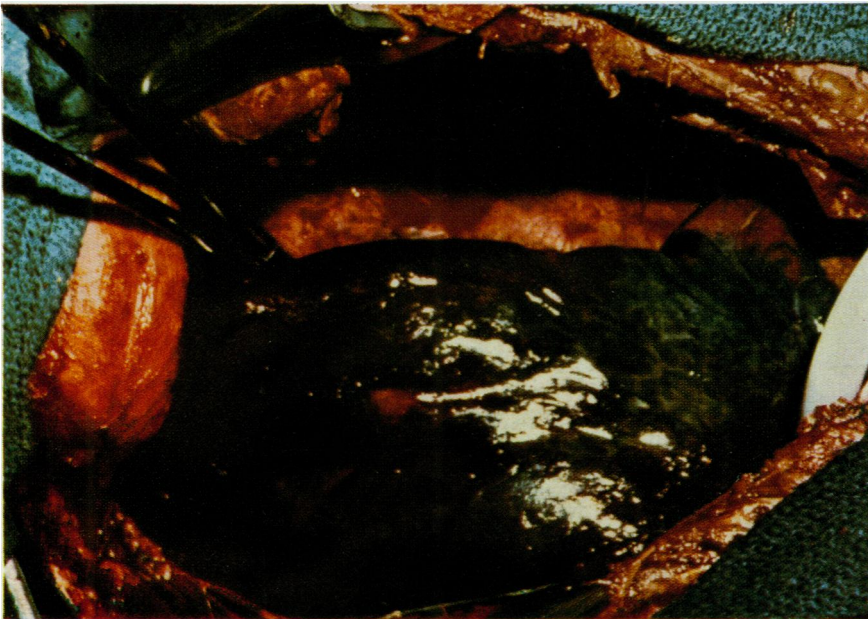

Fig. 4 Intraoperative illustration of the infarcted gangrenous lobe as a result of torsion.

Discussion

Torsion of the lung results in haemorrhagic infarction and eventually gangrene. Most experimental studies have shown that interruption of both the bronchial and pulmonary circulations is

required to produce infarction. Ligation of the pulmonary artery alone, or the artery and vein, does not cause pulmonary infarction (Liebow *et al.*, 1950). Blood flow is restored through bronchial collateral circulation to the pulmonary artery. In his description of two-stage pneumonectomy,

Rienhoff (1938) reported that, in his clinical experience, ligation of the pulmonary artery and veins resulted in wet gangrene only if the bronchial circulation was inadvertently interrupted.

Torsion of the lung produces striking deterioration of the patient, air leak and sepsis frequently compounding the problem (Mullin *et al.*, 1972). Most reported cases demonstrate a slower downhill course than ours. Because of its rarity, delay in diagnosis may occur. The process may be progressive as retrograde thrombosis and spillage of contaminated sputum affect adjacent lobes and the opposite lung.

Diagnosis is aided by chest radiography, which shows sudden complete opacification of the rotated lobe. Arterial blood gases were deceptive in the case presented. This may be explained by the absence of any blood flow to the infarcted lobe with perfusion shunted to uninvolved areas. Despite what appeared to be adequate oxygenation, the patient's condition deteriorated remarkably. Bronchoscopy may not be diagnostic although it is helpful in ruling out other disorders, such as aspiration pneumonia.

Prevention of a fatal outcome requires early diagnosis and resection of the infarcted area. Vigorous endotracheal suction is hampered by the possibility of damage to the bronchial stump. However, all attempts should be made to aspirate

the contaminated sputum from the bronchial tree before reoperation in order to protect the remaining uninvolved segments. Antibiotics, fluids, and supplemental oxygen may be of temporary benefit. Treatment is speedy resection of the gangrenous lobe.

References

- Liebow, A. A., Hales, M. R., Bloomer, W. E., Harrison, W., and Lindskog, G. E. (1950). Studies on the lung after ligation of the pulmonary artery: 2. Anatomical changes. *American Journal of Pathology*, **26**, 177-185.
- Mullin, M. J., Zumbro, G. L., Jr., Fishback, M. E., and Nelson, T. G. (1972). Pulmonary lobar gangrene complicating lobectomy. *Annals of Surgery*, **175**, 62-66.
- Rienhoff, W. F., Jr. (1938). A two-stage operation for total pneumonectomy in the treatment of carcinoma of the lung, demonstrating a new technique for closure of the bronchus. *Journal of Thoracic Surgery*, **8**, 254-271.
- Schuler, J. G. (1973). Intraoperative lobar torsion producing pulmonary infarction. *Journal of Thoracic and Cardiovascular Surgery*, **65**, 951-955.

Requests for reprints to: Dr. W. C. Miller, Director, Pulmonary Division, Department of Internal Medicine, John H. Freeman Building, Texas Medical Center, 6400 West Cullen Street, Houston, Texas, 77025, USA.