

# Total bypass of the oesophagus for benign strictures using a reversed gastric tube

P. YANNOPOULOS AND A. MARSELOS

*From the Department of Surgery, University of Athens, Greece*

**Yannopoulos, P., and Marselos, A. (1977). Thorax, 32, 729-733. Total bypass of the oesophagus for benign strictures using a reversed gastric tube.** Four cases of benign stricture of the oesophagus treated by reversed gastric tube oesophagoplasty are presented. The technique used is described in detail, and the advantages of this method over other ways of bypassing the oesophagus are discussed. The most important advantage is the restoration of normal deglutition with only one extrathoracic anastomosis.

Benign fixed strictures of the oesophagus secondary to oesophagitis, when they are long or situated high in the chest, are a serious, if fortunately not too common, complication of gastric reflux. Some cases can be either treated medically or improved by dilatation but fixed strictures are difficult to dilate and carry the risk of perforation if frequent dilatation is necessary.

Many operative techniques are used for the relief of this condition and the fact that there are many denotes that none is ideal for every case.

Excision of a short stricture and end-to-end anastomosis may be followed by anastomotic leak or recurrence of the stricture (Storey, 1962). Oesophago-gastric anastomosis within the chest has an appreciable incidence of anastomotic leakage. There is also the risk of oesophagitis above the anastomosis, sometimes with stricture formation (Ellis and Hood, 1954). Fundoplication within the chest in an effort to prevent reflux is not without complications. The use of a small bowel segment to bypass the lower oesophagus again necessitates an anastomosis in the chest with a risk of mediastinitis due to leaks.

For total bypass the colon is the best lower digestive tract organ that can be used, and at one time we supported the view that the left colon was safer because of its more adequate and constant blood supply, its even better venous drainage, and its easier mobilisation (Tountas *et al.*, 1968). Many reports have, however, appeared recently concerning ulceration, bleeding, and perforation of the segment of bowel anastomosed to the stomach (Gregorie and Hughes, 1963; Menguy, 1965; Holland, 1967; Heimlich, 1970).

In our opinion, the reversed gastric tube operation described in Europe by Gavrilu and Georgescu (1951) and in the USA by Heimlich (1955) is an effective operation not only for carcinoma of the oesophagus but also for benign stricture. We describe here our experience in four cases.

## Operation

A pedicled tube, 30 to 35 cm in length and about 2 cm in diameter, is constructed from the greater curvature of the stomach. To form the tube an incision is made parallel to the greater curve, starting from the antrum about 4 cm proximal to the pylorus. The incision runs across the antrum for approximately 3 cm and then parallel to the greater curvature until it reaches the fundus of the stomach. Suture of the two cut edges will reform a new greater curvature and also form a tube long enough to bypass or replace the whole oesophagus (Fig. 1).

To increase the blood supply and the mobility of the tube, the spleen is excised, care being taken to ligate the splenic vessels in the hilum and to preserve the left gastroepiploic artery. Mobilisation of the tail of the pancreas from its bed will further increase the mobility of the gastric tube and allow it to reach the pharynx. However, the reversed gastric tube oesophagoplasty can be done without splenectomy and this is important for younger children in order to prevent infectious complications (Anderson and Randolph, 1973).

The tube thus formed is reversed in direction, and its antral end is brought up into the neck while its fundal end remains attached to the stomach. The

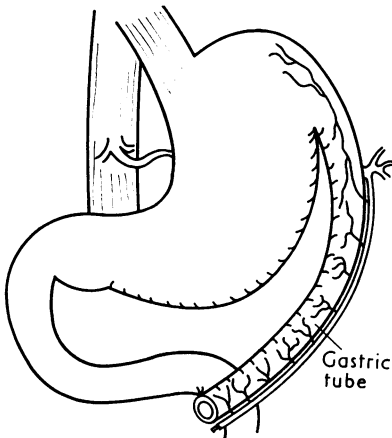


Fig. 1 Diagram of method for constructing the reversed gastric tube.

route can be intrathoracic, retrosternal, or subcutaneous. In our cases, in which the procedure was used to bypass the oesophagus for a benign stricture, we preferred the retrosternal position. A temporary gastrostomy was performed for decompression of the stomach and feeding.

### Case reports

#### CASE 1

A 25-year-old man was admitted to hospital complaining of severe dysphagia. Radiographic investigation revealed a tight stenosis of the lower third of the oesophagus and gross reflux (Fig. 2). At oesophagoscopy advanced oesophagitis and a fixed stricture were noted. Dilatations were unsuccessful and a reversed gastric tube oesophagoplasty was performed. The gastric tube was placed retrosternally and was anastomosed end-to-end to the cervical oesophagus while the distal oesophageal segment was closed and left in situ.

The postoperative course was uneventful and the patient left hospital after 20 days eating a normal diet. Six months later he was readmitted because of a recurrence of the dysphagia. This proved to be due to a stricture of the oesophago-gastric anastomosis. Dilatation was unsuccessful and a revision of the anastomosis was performed through a small incision in the neck (Fig. 3). The patient has been eating normally for the last three years.

#### CASE 2

A 9-year-old girl was admitted complaining of dysphagia for five years. Dilatations had been performed every two or three months but had given only temporary relief. On admission the girl had not been

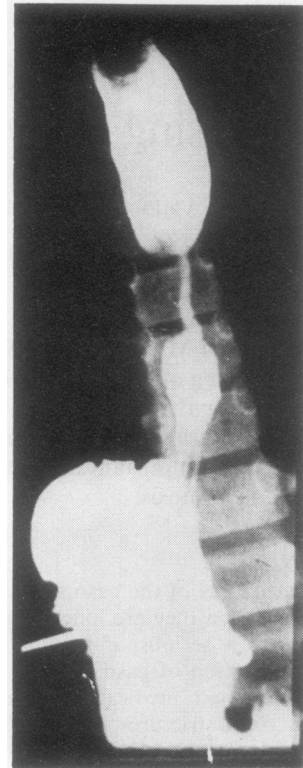


Fig. 2 Preoperative oesophagogram showing a long stricture of the lower oesophagus.

able to swallow anything for two days in spite of a recent dilatation. Radiographic investigation and oesophagoscopy revealed a long fixed benign stricture of the lower oesophagus due to reflux oesophagitis.

A reversed gastric tube was placed substernally and anastomosed end-to-end with the cervical oesophagus. The diseased oesophagus was not excised. The postoperative course was uneventful and the patient left hospital after 15 days eating a normal diet. She has been doing so for over a year.

#### CASE 3

A 10-year-old boy was admitted to hospital complaining of inability to take anything by mouth for three days. He had been suffering from dysphagia since birth and a stricture had been dilated many times. Two years before this admission he had been operated upon elsewhere. A stricture was excised and end-to-end anastomosis of the oesophagus was performed. This relieved his symptoms for three months but dysphagia recurred and got steadily worse. Radiographic investigation showed a short oesophagus and a tight benign stricture.

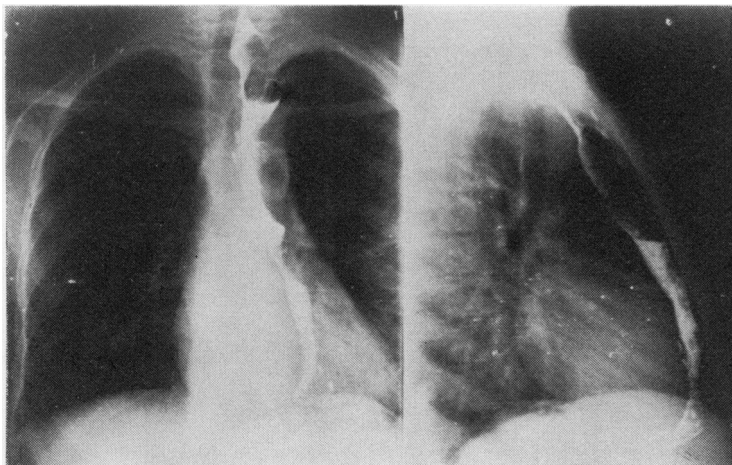


Fig. 3 Postoperative barium swallow through the new oesophagus. The reversed gastric tube lies posterior to the sternum.

A reversed gastric tube oesophagoplasty was performed using the retrosternal route and end-to-end anastomosis to the cervical oesophagus. The diseased oesophagus was not removed. The postoperative course was uneventful and the boy left hospital after 17 days eating a normal diet.

#### CASE 4

A 13-year-old girl was admitted to hospital because of dysphagia which had first appeared seven years previously. Dilatations had been performed every three months but recently her condition had become worse, and on admission she could swallow only liquids in spite of a dilatation one month previously. Radiographic investigation and oesophagoscopy showed severe reflux, active oesophagitis, and a long benign stricture of the oesophagus just below the aortic arch, while gastric mucosal folds could be seen in the thorax below the stricture (Fig. 4).

A reversed gastric tube oesophagoplasty was performed. The tube was placed retrosternally and its antral end anastomosed end-to-end with the cervical oesophagus (Fig. 5). The distal cervical oesophagus was inverted, closed, and left in situ. The postoperative course was satisfactory. A small cervical salivary fistula appeared but closed spontaneously in five days. The patient left hospital eating a normal diet.

#### Discussion

The reversed gastric tube operation has many advantages when compared to oesophageal reconstructions using colon or small intestine.

(1) The blood supply to the gastric tube is very rich and the vessels involved, being placed along the edge of the tube and parallel to it, are not liable to kinking,

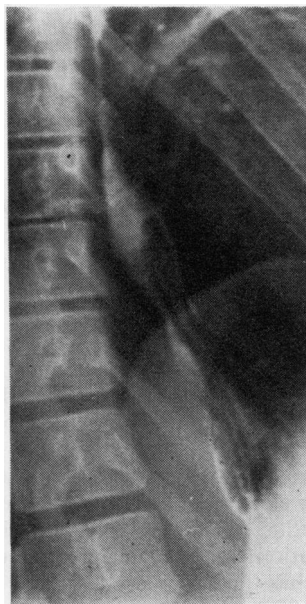


Fig. 4 Preoperative oesophagogram showing a long stricture below the aortic arch and mucosal folds in the thorax below the stricture.

torsion, or obstruction from tension as may sometimes occur with pedicled grafts of small intestine or colon.

It has been suggested that communications between right and left gastroepiploic arteries might be congenitally absent and then the blood supply to the antral end might be inadequate and necrosis of the tube might occur (Alivisatos and Avlami, 1964). This has not been observed by Heimlich (1972) in a series of 53 patients nor by Gavriliu (1975) in a series of 530

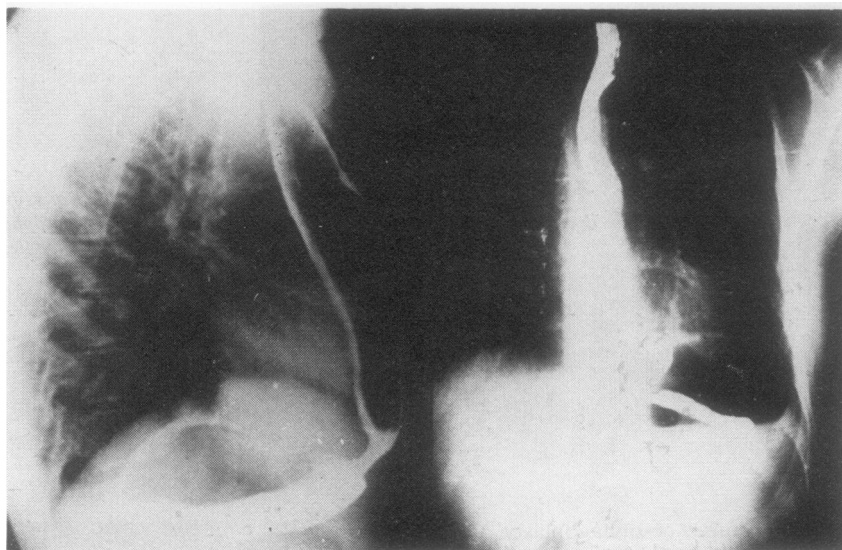


Fig. 5 Postoperative barium swallow through the new oesophagus. The reversed gastric tube lies posterior to the sternum.

cases nor did we have any problem of blood supply in our cases (Yannopoulos *et al.*, 1975, 1976).

(2) Only one anastomosis is needed and this is in the neck where a leak will have no disastrous consequences. Revision of the anastomosis in case of stricture is easy.

(3) The gastric tube is by nature well adapted to the influence of acid reflux from the stomach itself while that part which is anastomosed to the cervical oesophagus is of antral origin and therefore does not secrete acid.

It has been suggested that the antral segment uninfluenced by acid might secrete excessive quantities of gastrin, thus leading to hyperchlorhydria and peptic ulceration in the stomach or duodenum or both. This has been reported in one case only (Heimlich, 1970). A reversed gastric tube, unlike jejunal or colonic implants, is not subject to chemical inflammation, ulceration, haemorrhage or perforation due to reflux of gastric contents.

(4) The operative procedure is relatively simple and mortality from it acceptable (Gavriliu 3%, Heimlich 5.7%) even in cases of benign lesions. Morbidity is also low. The most common complications are stenosis of the anastomosis and salivary fistulae. Usually such complications do not present serious problems. Salivary fistulae close by themselves while dilatation will usually deal satisfactorily with stenosis. Even if a revision is needed this is easily performed through a small incision in the neck.

(5) Thoracotomy and intrathoracic dissection are

unnecessary as the diseased oesophagus is not excised. This, of course, carries the theoretical danger of development of carcinoma in an oesophagus which has been subjected for a long time to chronic irritation and inflammation. However, we believe that resection of the oesophagus is not justified as a prophylactic against a dubious cancer risk.

Our observations concern the application of this procedure in the treatment of benign strictures in four patients. Their ages ranged from 9 to 25 years. All had had dilatations or a previous unsuccessful operation. The results of the reversed gastric tube oesophagoplasty were excellent in all. One patient required revision of the cervical anastomosis six months later because of the development of a stricture. Another patient developed a cervical salivary fistula which closed spontaneously in a few days.

All patients have been eating a regular diet for periods of three months to 3½ years. We feel that the reversed gastric tube oesophagoplasty fulfils most of the requirements for the ideal treatment for a fixed benign stricture, namely, low mortality and morbidity, minimal side effects due to reflux, and no dangerous intrathoracic anastomosis.

#### References

- Alivisatos, C., and Avlamis, G. (1964). Sur l'établissement d'un néo-oesophage par plastie gastrique. *Lyon Chirurgical*, **60**, 699-705.
- Anderson, K. D., and Randolph, J. G. (1973). The gastric

- tube for esophageal replacement in children. *Journal of Thoracic and Cardiovascular Surgery*, **66**, 333–342.
- Gavriliu, D. (1975). Aspects of esophageal surgery. *Current Problems in Surgery*, **12**, No. 10.
- Gavriliu, D., and Georgescu, L. (1951). Esofagoplastic Cu Material Gastric. *Revista Stiintelor Medicale*, **3**, 33–36.
- Gregoric, H. B., Jr., and Hughes, J. C. (1963). Unusual complications related to colonic substitution for the esophagus. *Journal of the South Carolina Medical Association*, **59**, 418–422.
- Ellis, F. H., Jr., and Hood, R. T., Jr. (1954). Experimental esophagogastratomy: relation of type of resection to development of esophagitis. *Surgery, Gynecology and Obstetrics*, **98**, 449–455.
- Heimlich, H. J. (1955). The use of gastric tube to replace or by-pass the esophagus. *Surgery*, **37**, 549–559.
- Heimlich, H. J. (1970). Esophagitis: complications treated by total bypass without esophageal resection. *Annals of Thoracic Surgery*, **10**, 203–212.
- Heimlich, H. J. (1972). Esophagoplasty with reversed gastric tube. *American Journal of Surgery*, **123**, 80–92.
- Holland, R. H. (1967). Peptic ulceration and perforation of a left colon bypass for esophageal carcinoma. *Journal of Thoracic and Cardiovascular Surgery*, **53**, 733–734.
- Menguy, R. (1965). Intrathoracic perforation of the colon: an unusual complication of colonic interposition for esophageal stricture. *American Surgeon*, **31**, 329–332.
- Storey, C. F. (1962). Congenital esophageal atresia: complications of therapy and their management. *Western Journal of Surgery*, **70**, 215–224.
- Tountas, C., Marselos, A., Kyriakou, K., and Blantzas, G. (1965). The use of the left colon in upper digestive tract replacement. *Proceedings of the Congressus Chirurgicus, Bratislava*.
- Yannopoulos, P., Heimlich, H., and Tountas, C. (1975). Reversed gastric tube esophagoplasty. *IX Panhellenic Congress of Surgery*, Vol. 2, 928–000.
- Yannopoulos, P., Paraskevas, G., and Kanas, D. (1976). Reversed gastric tube esophagoplasty after esophagolaryngectomy. *XX Biennial World Congress of the International College of Surgeons, Athens*.

Requests for reprints to: Dr. P. Yannopoulos, Assistant Professor of Surgery, University of Athens, Pasteur 4, Athens 602, Greece.