

# Aetiology of unresolved pneumonia

S. R. BULMER, D. LAMB, R. J. M. McCORMACK<sup>1</sup>, AND P. R. WALBAUM<sup>1</sup>

*From the Department of Pathology, University of Edinburgh, Medical School, Teviot Place, Edinburgh EH8 9AG and the Department of Thoracic Surgery<sup>1</sup>, City Hospital, Greenbank Drive, Edinburgh EH10 5SB*

**Bulmer, S. R., Lamb, D., McCormack, R. J. M., and Walbaum, P. R. (1978). Thorax, 33, 307-314. Aetiology of unresolved pneumonia.** Preoperative histological or cytological confirmation of a diagnosis of bronchogenic carcinoma is not always possible, so occasionally non-neoplastic lesions are resected. Of these lesions a significant number are described by pathologists as 'unresolved pneumonia'. We studied the case notes and histopathology of 30 patients from whom lung had been resected and which had been classified as pneumonia. Other non-neoplastic lesions, such as pulmonary infarction, bronchiectasis, and tuberculosis, were excluded. All had a preoperative diagnosis of probable bronchial carcinoma. On review very few appeared to be the consequence of an infective, pneumonic episode. In 11, foreign material was identified, including one typical example of a paraffinoma. Aspiration of foreign material may lead to a localised lesion which simulates carcinoma of the bronchus both clinically and radiographically.

Carcinoma of the bronchus is a common disease today and resection of this neoplasm is the most frequent thoracic operation. It is not always possible to obtain histological diagnosis before thoracotomy and resection so inevitably some non-neoplastic lesions are removed. In this group a significant number show areas of organisation within the lung and are reported by pathologists as 'unresolved pneumonia'.

Aspiration of lipid material, especially liquid paraffin, into the bronchial tree has long been recognised to cause an inflammatory response with fibrosis. This localised area of fibrosis may simulate a bronchial carcinoma at presentation and by its radiographic appearances. There are several reports of resections of such lesions in the belief that they were carcinoma (Siddon, 1958; Salm and Hughes, 1970; Borrie and Gwynne, (1973). Volk *et al.* (1951) found a prevalence of 14.6% of lipid pneumonias in a series of chronically ill patients. More recently, aspiration of other foreign material, especially the leguminous contents of a hospital diet, has been found to cause local fibrosis and in some a granulomatous response (Gill and Ritchie, 1974). These lesions have been found at necropsy, especially in certain groups of patients who have difficulty in swallowing. Knoblich (1969) found a prevalence of 2.7%

in a consecutive series of necropsies.

The possibility that some of the 'unresolved pneumonias' resected by thoracic surgeons might be the end result of aspiration of foreign material led us to examine our files for such cases.

## Methods

From the files of the Edinburgh University Pathology Department over the 10-year period 1967 to 1976, 29 cases classified as 'pneumonia' with or without mention of foreign material were identified and the slides were reviewed. Other non-tumour lesions, for example, infarct, bronchiectasis, and tuberculosis, were checked and excluded from this survey. The majority of resections were lobectomies but two pneumonectomies were present. One case in which only a biopsy of a lung lesion was taken, as the abnormalities appeared to be unresectable, has been included, because on clinical and radiological grounds it was thought to be metastatic tumour. A case in which right upper lobectomy was performed was sent to one of us (DL) for review and has been included.

The number of slides of the lesions per case varied from one to 14 with an average of 5.8. Routine haematoxylin and eosin sections were available in all cases, and, in some, special stains,

for example, for reticulin and elastin, were present or were prepared. All sections were checked for the presence of refractile material by the use of crossed Nicol prisms.

The case notes of each patient were traced and examined.

The size and site of the lesion and presence or absence of pleural adhesions were taken from the operation notes and the contemporary pathology report. The following clinical features were also recorded: age, sex, smoking history, presenting symptoms, alcohol intake, presence of finger clubbing, and presence of any upper gastrointestinal symptoms. In none was there any history of aspiration.

## Results

On review the 30 cases could be divided into four groups (Table 1). None showed any evidence of malignancy.

Table 1

| Group |                                   | No. of cases |
|-------|-----------------------------------|--------------|
| A     | Aspiration pneumonia              |              |
|       | Particulate foreign material      | 10           |
|       | Extrinsic lipid                   | 1            |
| B     | Probable aspiration pneumonia     | 6            |
| C     | Organising intra-alveolar exudate | 4            |
| D     | Miscellaneous                     | 9            |

### GROUP A ASPIRATION PNEUMONIA

The criterion for allocation into this group was the unequivocal presence of foreign material. In 10 particulate material was identified, and in only one was all the foreign material found to be extrinsic lipid, ie, the features of a paraffinoma (*vide infra*).

The other 10 cases all showed histological features in common. There was an organising intra-alveolar exudate extending to involve the alveolar ducts and respiratory and terminal bronchioles (Fig. 1). This consisted of fibrous tissue in which occasional lymphocytes and plasma cells were present. The alveolar walls were thickened with some dilatation of the capillaries. The alveolar lining cells were more prominent than usual but there was no proliferation or desquamation. There was a moderate to severe chronic inflammatory cell infiltrate involving the alveolar walls and, to a lesser extent, areas of scarring. In some areas the lymphocytes showed focal aggregation with occasional germinal centre formation.

The small airways within the lesion were damaged to a greater or lesser degree both by the inflammatory infiltrate and by the organising

exudate (Fig. 2). In some, organisation of exudate extended into medium-sized airways. This caused obstruction of the lumen and was associated with accumulation of foamy macrophages distally in the alveoli.

Within the lesions 'foreign body' multinucleated giant cells were present (Fig. 3). These showed a focal distribution and were usually in close association with small airways. Such giant cells were present in all lesions and in moderate to large numbers in the majority of cases.

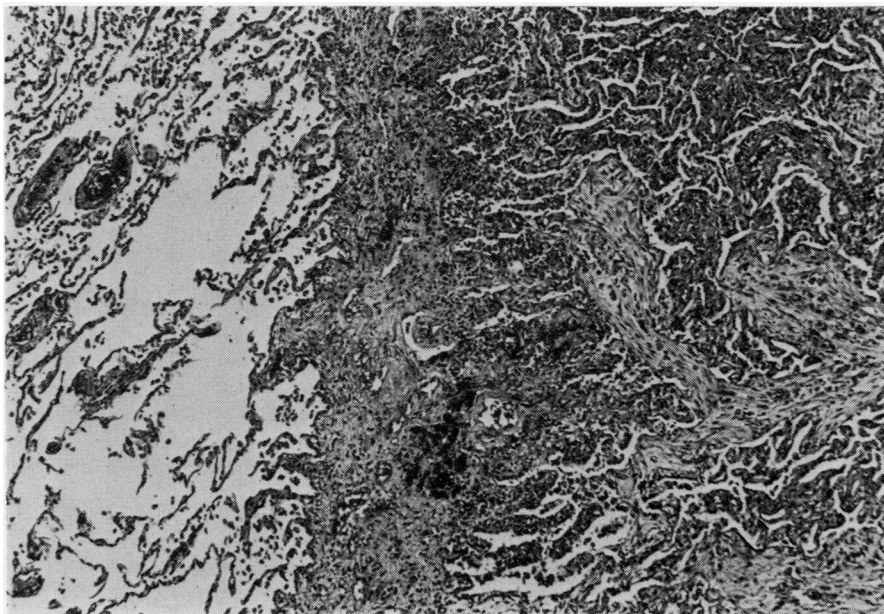
Foreign material was present, often in intimate association with these giant cells, in all the cases (Fig. 4). Moderate amounts were found in two. The foreign material was particulate and did not polarise when examined with crossed Nicol prisms. Only in the case sent for review were identifiable cross sections of legumes seen (Fig. 5), and these had not elicited a granulomatous response. The foreign material seen in the other cases was possibly of vegetable origin but specific identifiable features were not seen.

In two cases clear circular spaces, surrounded by flattened macrophages and giant cells, were present (Fig. 6). These were considered to represent extrinsic lipid; no unprocessed material was available for verification. Single intracytoplasmic lipid vacuoles were not alone considered as providing proof of the presence of extrinsic material.

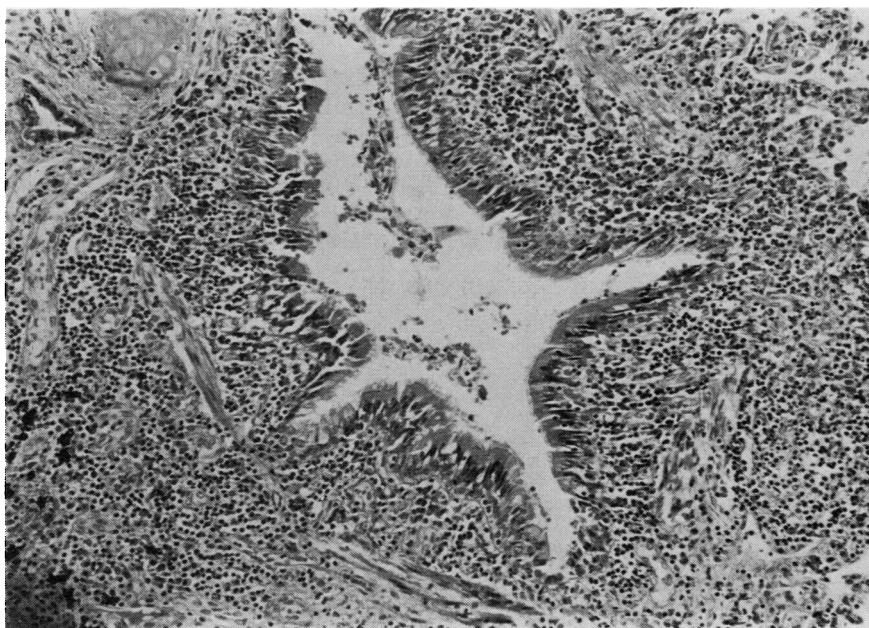
These areas of intense inflammatory reaction were relatively compact and often stopped abruptly at pulmonary septa (Fig. 1). Adjacent to the lesion the lung showed little histopathological abnormality.

The degree of inflammation was reflected by vessels, many of which showed old thrombosis with recanalisation, and by the presence of pleural thickening and dense pleural adhesions. In five cases the degree of adhesion to the chest wall necessitated extrapleural resection. In one case the neurovascular bundles from the intercostal spaces were present.

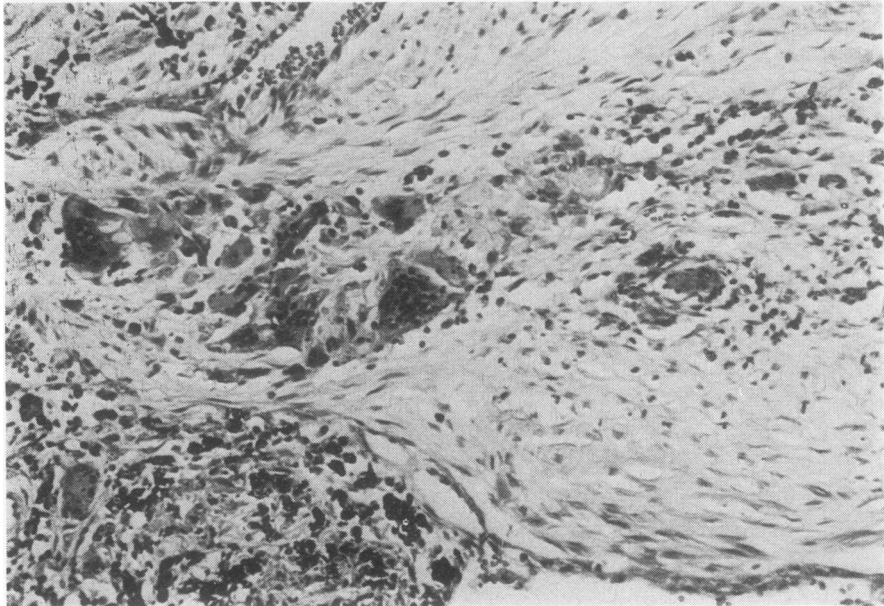
There was one case with the well-defined picture of a paraffinoma or chronic lipid pneumonitis. A localised lesion, 5 cm in diameter, was present in the basal segments of the left lower lobe. Microscopic examination showed the presence of multiple, clear, rounded spaces associated with multinucleated giant cells. Similar smaller clear spaces were seen within the cytoplasm of some giant cells and macrophages. In association with them was an extensive fibrotic reaction such that the original lung architecture could no longer be identified. Similar rounded spaces with associated giant cells were present in the hilar lymph nodes.



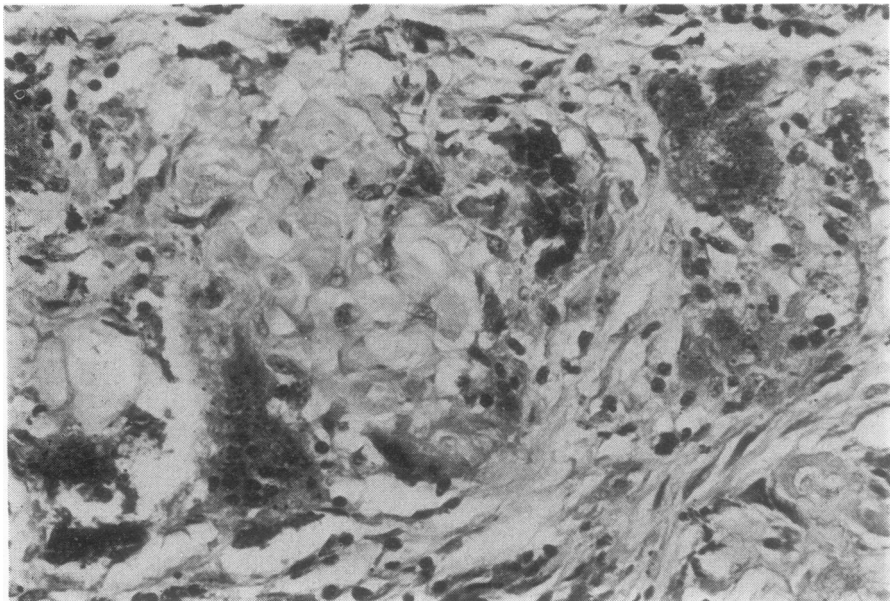
**Fig. 1** Lobectomy specimen showing the lesion delineated by pulmonary septa. Organising exudate is present in respiratory bronchioles and alveolar ducts but there is sparing of the alveoli themselves. Haematoxylin and eosin  $\times 60$ .



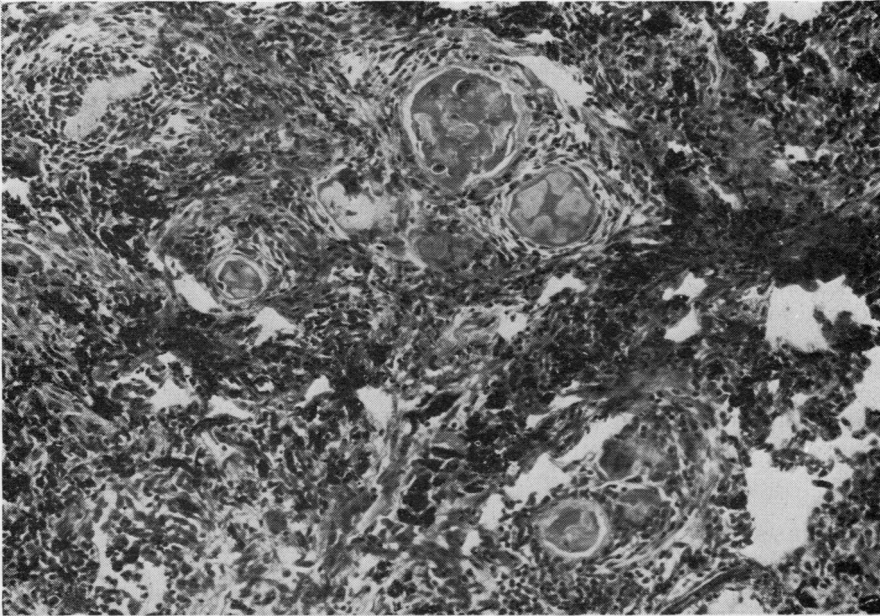
**Fig. 2** An airway showing an intense chronic inflammatory infiltrate in its wall. Inflammatory cells are also present within the epithelium. H and E  $\times 16$ .



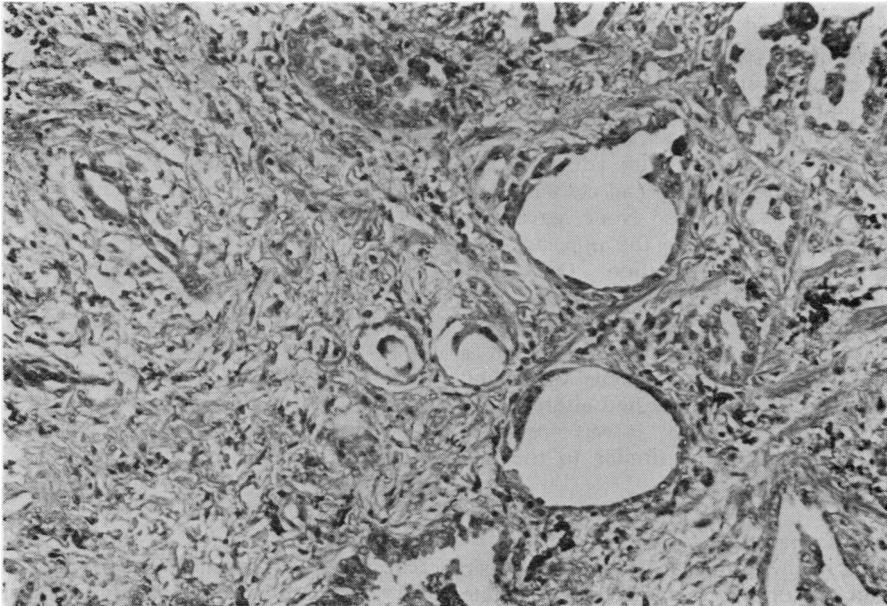
**Fig. 3** *Within this airway there is organising fibrous tissue in which multinucleated 'foreign body' giant cells associated with foreign material are present. H and E  $\times 180$ .*



**Fig. 4** *A high-power view of the foreign material taken from the same case as in Fig. 3. H and E  $\times 350$ .*



*Fig. 5 Several transections of vegetable particles are present within alveolar ducts. They have provoked a marked fibrous tissue response with associated chronic inflammatory cells. H and E  $\times 40$ .*



*Fig. 6 Two large clear spaces surrounded by flattened macrophages are present and indicate the presence of extrinsic lipid material. H and E  $\times 100$ .*

Frozen sections of this lesion, stained with Sudan IV, confirmed the presence of lipid in the clear spaces seen in the paraffin section, including those from the hilar nodes.

#### *Clinical data*

Seven of the cases were upper lobe lesions, five on the right side and two on the left. The lesion in the other two cases was in the apical segment of the right lower lobe and the biopsy was taken from the middle lobe. All were men and all had a positive smoking history, although one had stopped three years before surgery. Two had finger clubbing; two gave a history of drinking alcohol to excess. On routine questioning none gave any history suggestive of an episode of aspiration or of any abnormality of upper gastrointestinal function.

#### GROUP B PROBABLE ASPIRATION PNEUMONIA

The histological features of these cases were the same as those in group A but no particulate foreign material was found. In all, foreign body giant cells were present, and in two, parietal pleura was present with the resected specimen. In one case there were extrinsic lipid spaces but, in the absence of particulate foreign material and of confirmation of the lipid, it was not thought to be sufficient evidence for inclusion within group A.

#### *Clinical data*

The case notes of two patients could not be found, and in one the notes were incomplete. Four of the lesions were upper lobe, the others being the middle lobe. There were five men and one woman in this group. In three cases with adequate histories, all were smokers and one had clubbing and also drank alcohol to excess. None gave any history of symptoms related to the upper gastrointestinal tract or of aspiration. One man originally presented with a relatively well-defined lesion in the apical segment of the left upper lobe and this was resected. Two years later, on a follow-up radiograph, a similar opacity was found in the right upper zone and this had altered little in appearance over 18 months. It was presumed that this second opacity was similar to the one resected.

#### GROUP C ORGANISING INTRA-ALVEOLAR EXUDATE

The four cases in this group all showed the basic pattern of an organising intra-alveolar exudate which was bounded by pulmonary septa. Only in two cases were occasional 'foreign body' giant cells present. One lesion had dense adhesions to

the chest wall. None showed unequivocal foreign material.

#### *Clinical data*

In this group there were three men and one woman but the case notes of only two patients were found. One man gave a history of drinking an excess of alcohol. One lesion was in the upper lobe involving the apical and part of the posterior segments and the other three were in the lower lobes, one in the apical segment and one within the basal segments. The precise site of the other was not recorded.

#### GROUP D MISCELLANEOUS

The nine cases in this group had little or no histological features in common with the above three groups. They are detailed in Table 2. Some

Table 2 *Group D Miscellaneous*

|   |   |
|---|---|
| 5 | ? Post-infective<br>Lung abscess in patient on steroids<br>Bronchopneumonic pattern of consolidation<br>Fibrin-rich consolidation with organisation<br>Collapse and consolidation<br>Abnormal proximal airways with distal damage |
| 1 | ? Sarcoid   |
| 1 | Lymphomatoid granulomatosis   |
| 1 | Severe chronic airway inflammation—uncertain aetiology  |
| 1 | Asthmatic with eosinophilic infiltrate<br>? allergic aspergillosis  |

of them may be the end result of an infective pneumonic process. These cases have not been described in any detail.

#### *Radiological features*

The chest radiographs of 15 of the 20 cases from Edinburgh in groups A, B, and C were available for review. The abnormalities varied from relatively localised lesions to more diffuse opacities. The localised lesions were approximately spherical and were up to 3.5 cm in maximum dimension. The more diffuse lesions covered a larger area and abutted on to the boundaries of the lung fields. It would appear that the abnormalities seen were the lesions thought to be carcinoma.

#### **Discussion**

The cases in groups A, B, and C had many features in common. Many of these lesions were very localised and compact, varying in size from 2.5 cm to 5 cm in maximum dimension. Others were more diffuse. In only one case did the lesion appear to be too widespread for resection. The

majority had single lesions but there were two cases with bilateral abnormalities. One of these was the paraffinoma where radiographic changes were present at the time of resection of the large lesion in the left lower lobe. In the other, a second lesion appeared two years later on follow-up and was presumed to be of similar aetiology.

Most lesions were in the upper lobe with the majority on the right side. Those in the lower lobes were mainly in the apical segment. These sites were compatible with the suggested aetiology. Some were characteristic, for example, posterior segment of upper lobe and apical segment of lower lobe (Brock *et al.*, 1942) but others were less typical and might possibly have been related to excess alcohol consumption.

Foreign material was present in all cases in group A. This included the single case of paraffinoma where all the foreign material was extrinsic lipid. Particulate material was found in the others but in only two was it present with any frequency. In the remaining cases careful searching of several sections was necessary before foreign material could be found. The aspirated material may have been in fluid form, for example, a mixture of alcohol and gastric secretions, so that no particulate evidence would be seen.

There was a severe localised inflammatory response, as shown by the airway damage, the thrombosis and recanalisation of the vessels, and the overlying pleural thickening. In eight of the 20 cases, parietal pleura, sometimes with skeletal muscle, was resected. This degree of adhesion may reinforce the presumptive diagnosis of carcinoma.

Aspiration of foreign material and gastric contents is a well-recognised risk in various circumstances, including loss of consciousness from any cause, any lesions which result in disturbance of the mechanism of swallowing, and any lesions which affect the cough reflex (Culver *et al.*, 1951; Cameron and Zuidema, 1972). Aspiration may also occur during sleep (Quinn and Meyer, 1929), especially in those with malfunction at the gastro-oesophageal junction. Aspiration of gastric contents in those with gastro-oesophageal reflux is thought to account for the increased incidence of pulmonary fibrosis found in such cases (Mays and Dubois, 1976). In 143 consecutive patients with hiatus hernia, Pearson and Wilson (1971) found four per cent with pulmonary fibrosis.

If aspiration of small, possibly repeated, quantities of gastric contents can lead to pulmonary fibrosis as seen on the chest radiograph and in histological biopsies, it is possible that similar episodes could lead to the development of a localised lesion simulating carcinoma of the

bronchus. Ackerman *et al.* (1954) described a series of 15 cases of localised organising pneumonia and emphasised their resemblance to bronchial carcinoma. Their description of the lesions bears some similarity to the cases in this review but only occasional giant cells were found. No evidence of extrinsic lipid or of particulate foreign material was reported. The majority of their cases were upper lobe abnormalities but two hilar lesions were included.

In our study, routine questioning of patients had failed to reveal any symptoms suggestive of gastro-oesophageal reflux, and two patients who were specifically asked postoperatively denied any episode of aspiration. Four of the 21 patients admitted, on routine questioning, to drinking in excess of half a bottle of spirits a day. One man's occupation was given as barman but his alcohol intake was not recorded.

It is of interest that in only one of the cases were leguminous particles identified. Such particles were commonly found in similar lesions in lungs at necropsy (Knoblich, 1969). In our experience, such particles and/or extrinsic lipid material are present in at least 1% of necropsies each year. This may be related to the amount of legume in the hospital diet.

The nine miscellaneous cases placed in group D have different histological patterns from the first three groups. Only five are possibly the consequence of an infective, pneumonic episode. The lesions resulting from aspiration are distinct from those described by Liebow (1968) as interstitial pneumonitis or pulmonary angiitis (Liebow, 1973). All except two of the aspiration lesions were single radiographic opacities whereas the lesions described by Liebow are usually multiple, and the commonest diagnosis before histological examination is multiple metastatic tumours. The majority of aspiration lesions are in upper lobes, whereas interstitial pneumonia affects more commonly the lower lobes. In addition, the inflammatory response initiated by aspiration of foreign material is reflected by pleural adhesions which are rare in interstitial pneumonia.

From this survey of lesions called 'unresolved pneumonia' by pathologists, very few appear to be the simple consequence of an infective pneumonic episode. In the group of 30 cases, 11 show definitive evidence of aspiration of foreign material. In only one case was all the foreign material extrinsic lipid. The six cases which were placed in group B have some histological features in common with group A and, in addition, their clinical features and radiographic appearances are very similar to those with definitive evidence

of the presence of foreign material. Hence it is suggested that these cases may also be the result of aspiration of foreign material. The same arguments can be applied to the four cases in group C as they also show some of the characteristics of group A.

We thank Dr J. Chahlaoui for discussing the radiographs with us.

The National Coal Board provided financial support for this work.

## References

- Ackerman, L. V., Elliott, G. V., and Alanis, M. (1954). Localised organising pneumonia: its resemblance to carcinoma. A review of its clinical, roentgenographic and pathologic features. *American Journal of Roentgenology*, **71**, 988-996.
- Borrie, J., and Gwynne, J. F. (1973). Paraffinoma of lung: lipoid pneumonia. *Thorax*, **28**, 214-221.
- Brock, R. C., Hodgkiss, F., and Jones, H. O. (1942). Bronchial embolism and posture in relation to lung abscess. *Guy's Hospital Report*, **91**, 131-139.
- Cameron, J. L., and Zuidema, G. D. (1972). Aspiration pneumonia: magnitude and frequency of the problem. *Journal of the American Medical Association*, **219**, 1194-1196.
- Culver, G. A., Makel, H. P., and Beecher, H. K. (1951). Frequency of aspiration of gastric contents by the lungs during anaesthesia and surgery. *Annals of Surgery*, **133**, 289-292.
- Gill, D. G., and Ritchie, G. J. (1974). Lentil pulmonary granulomatosis. *Medical Journal of Australia*, **1**, 836-838.
- Knoblich, R. (1969). Pulmonary granulomatosis caused by vegetable particles. *American Review of Respiratory Diseases*, **99**, 380-389.
- Liebow, A. A. (1968). Interstitial pneumonias. In *The Lung*, edited by A. A. Liebow and D. E. Smith, pp. 336-351. Williams and Wilkins, Baltimore.
- Liebow, A. A. (1973). The J. Burns Amberson Lecture—pulmonary angitis and granulomatosis. *American Review of Respiratory Diseases*, **108**, 1-18.
- Mays, E. E., and Dubois, J. J. (1976). Pulmonary fibrosis associated with tracheobronchial aspiration. *Chest*, **69**, 512-515.
- Pearson, J. E. G., and Wilson, R. S. E. (1971). Diffuse pulmonary fibrosis and hiatus hernia. *Thorax*, **26**, 300-305.
- Quinn, L. H., and Meyer, O. O. (1929). The relationship of sinusitis and bronchiectasis. *Archives of Otolaryngology*, **10**, 152-165.
- Salm, R., and Hughes, E. W. (1970). A case of chronic paraffin pneumonitis. *Thorax*, **25**, 762-768.
- Siddon, A. H. M. (1958). Oil granuloma of the lung. Report of 3 cases. *British Medical Journal*, **1**, 305-307.
- Volk, B. W., Nathanson, L., Losner, S., Slade, W. R., and Jacobi, M. (1951). Incidence of lipoid pneumonia in a survey of 389 chronically ill patients. *American Medical Journal*, **10**, 316-324.

Requests for reprints to: Dr D. Lamb, Department of Pathology, University of Edinburgh, Medical School, Teviot Place, Edinburgh EH8 9AG.