

Late presentation of primary pulmonary lymphangiectasis

SJ SC WAGENAAR,^{1,3} J SWIERENGA,^{2,4} AND C A WAGENVOORT³

From the Departments of Pathology¹ and Lung Diseases,² St Antonius Ziekenhuis, Utrecht, and the Department of Pathology,³ Wilhelmina Gasthuis, University of Amsterdam, Amsterdam, the Netherlands

Wagenaar, Sj Sc, Swierenga, J, and Wagenvoort, C. A (1978). Thorax, 33, 791-795. Late presentation of primary pulmonary lymphangiectasis. Pulmonary lymphangiectasis can occur either as a primary change or secondary to chronic congestion. Primary lymphangiectasis is generally considered to occur exclusively in young children. This report describes three male patients, aged 13, 16, and 19 years, in whom the changes are limited to one lobe or to two lobes and the mediastinum. So far as could be ascertained these patients are the oldest reported. Lymphangiectasis should be considered in the clinical differential diagnosis of "pulmonary cysts" in children and young adults.

Dilatation of lymph vessels is regularly found in combination with chronic congestion in the pulmonary circulation. In infants and children lymphangiectasis may occur either as a secondary complication of congenital cardiovascular anomalies associated with congestion or as a primary change.

The primary or congenital form appears more often than the secondary type (Noonan *et al*, 1970; Felman *et al*, 1972). Congenital lymphangiectasis usually occurs as a diffuse change throughout the lungs, sometimes as part of a more generalised process not limited to the lungs. So far, congenital lymphangiectasis of either of these types has been reported only in young children.

We shall describe three patients in whom primary lymphangiectasis of the lung showed itself at the ages of 13, 16, and 19 years respectively. So far as we could discover these patients are the oldest reported.

Clinical history

CASE 1

Ten days before the admission of this previously healthy 13-year-old youth, a well-circumscribed shadow with wavy outlines at the level of the right hilum and a slight enlargement of the mediastinum were seen on a routine radiograph (fig 1).

Physical and laboratory investigations of the patient showed no abnormalities. Bronchoscopic biopsies were taken from the right lower lobe bronchi. Histological examination showed lymphangiectasis in the mucosa. A right thoracotomy was performed. The right lower and middle lobes showed multiple cystic changes and were resected. Cystic changes were also found in the posterior mediastinum. Chemical analyses suggested the fluid content of these cysts to be lymph. The postoperative period was uncomplicated. Twenty-one years later the patient was free of symptoms, and his radiograph was normal.

CASE 2

A routine chest radiograph of this 16-year-old youth showed widespread areas of radiodensity and translucency in the left hilar region and upper zone. Tomography indicated cystic lesions. Results of physical and laboratory investigations were normal. Bronchoscopy showed a thickened mucosa in the left upper lobe bronchi, but the bronchial biopsies showed no changes. At thoracotomy the left upper lobe, which was of firmer consistency than the other lobe, was resected (fig 2). The pulmonary vein from the upper lobe had an abnormal course and drained into the vein from the lower lobe. There was no stenosis of either of these veins. The postoperative period was uncomplicated. Five years later the patient was symptom-free and the chest radiograph normal.

⁴Professor Swierenga died on 14 December 1977.

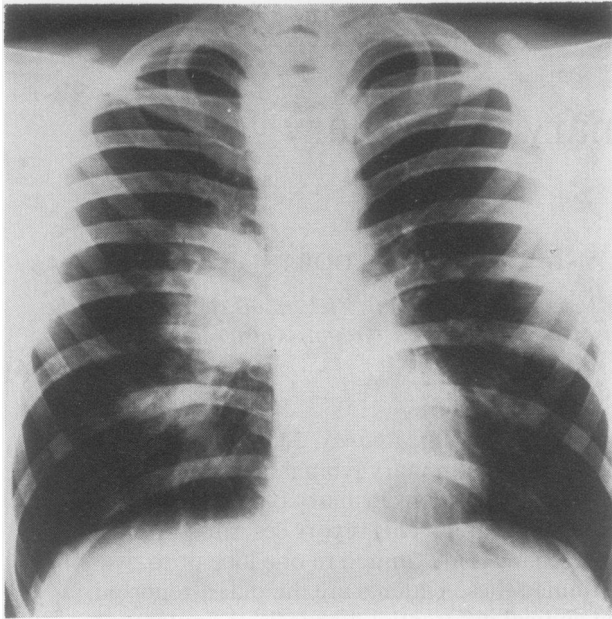


Fig 1 *Case 1. There is a well-circumscribed shadow at level of right hilum and a slight enlargement of mediastinum.*

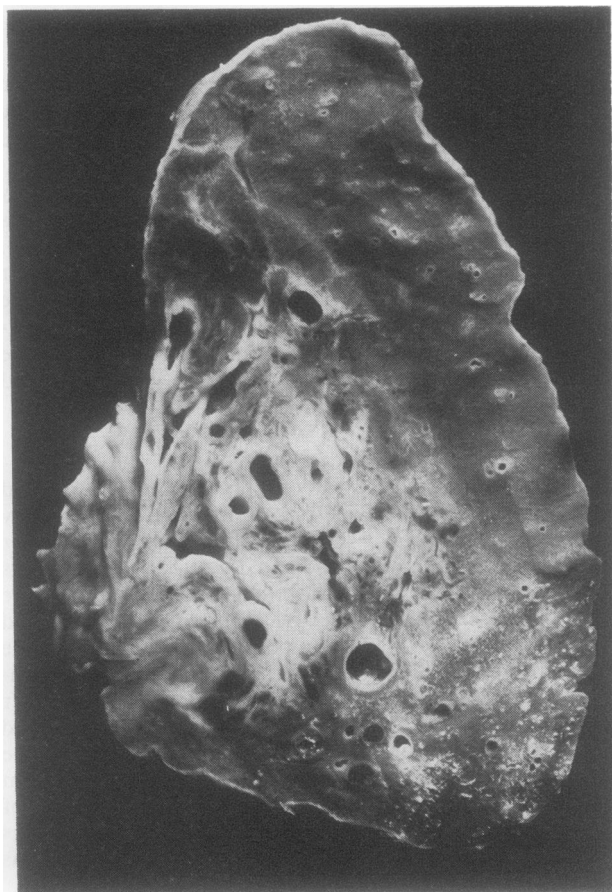


Fig 2 *Case 2. Cut surface of left upper lobe showing cystic changes along bronchi and vessels.*

CASE 3

Two years before the admission of this 19-year-old man a routine chest radiograph showed changes in the right lower lung, which were diagnosed as bronchiectases. On admission the radiographic changes had increased (fig 3). Infiltrates and cystic changes in right lower and middle lobes were found. Moreover, a cyst was noticed adjacent to the right side of the mediastinum. Results of physical and laboratory investigations were normal. Bronchoscopy showed no changes. The bronchial biopsies taken at this time contained normal mucosa. A right-sided thoracotomy was performed, and the right middle lobe was resected along with a cyst from the lower lobe. In addition, cysts were discovered in the mediastinum near the hilum; these were also removed. The patient made an uncomplicated recovery and had had no recurrence five years later.

Pathology

All three lung specimens showed the same macroscopic features. The pleural surface was smooth and intact but showed multiple localised areas of swelling, which were fluctuant on palpation. The cut surface showed numerous cysts with a maximum diameter of 1.5 cm, filled with a fluid having the appearances of lymph. The cyst walls were extremely thin with a smooth luminal surface. The lesions were not limited to the subpleural

region but could be found throughout the affected parts of the lungs. They had a distant localisation around bronchi and in interlobular septa.

Histological examination showed varying but usually extreme dilatation of lymph vessels. The dilatation was sometimes cystic, the vessels being closely adjacent to bronchi, pulmonary vessels, septa, and pleura (fig 4). In the bronchial walls the dilated lymphatics could be seen both inside and outside the cartilage rings, where these were present. The surrounding lung was sometimes collapsed due to compression by the lymphatic dilatation. There was a normal endothelial lining in the lymph vessels. The walls contained only sporadic smooth muscle cells. There were no elastic fibres, nor were there fibrous or hyaline changes. The lumens contained eosinophilic material. Locally, the vessel walls were infiltrated with lymphocytes, sometimes with the formation of lymph follicles. The fibrous tissue around bronchi and in septa and pleura was separated by oedema. There was, however, no oedema in the alveolar walls, nor was there interstitial fibrosis or haemosiderosis. The pulmonary and bronchial arteries had a normal structure without medial thickening or intimal proliferation. Only in case 2 was there any thickening of some venous walls, but there was no arterialisiation. The bronchial veins were not dilated. The excised solitary cysts showed the same structure as the dilated lymph vessels.

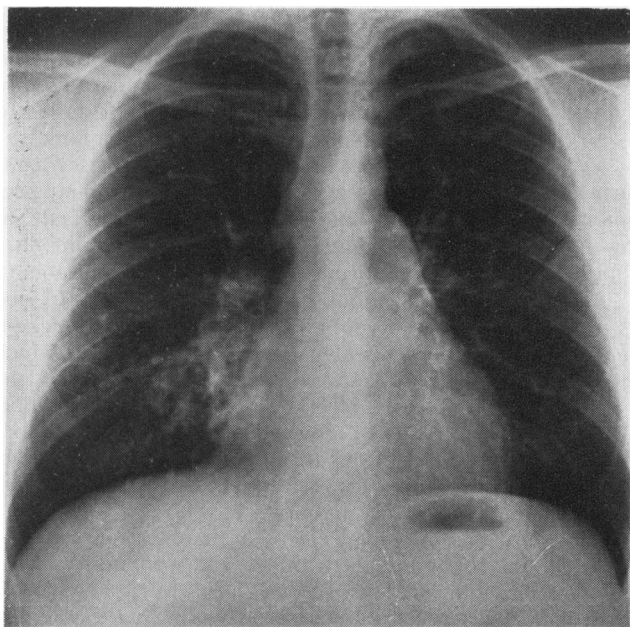


Fig 3 Case 3. Infiltrates and cystic changes in right lower and middle lobes.

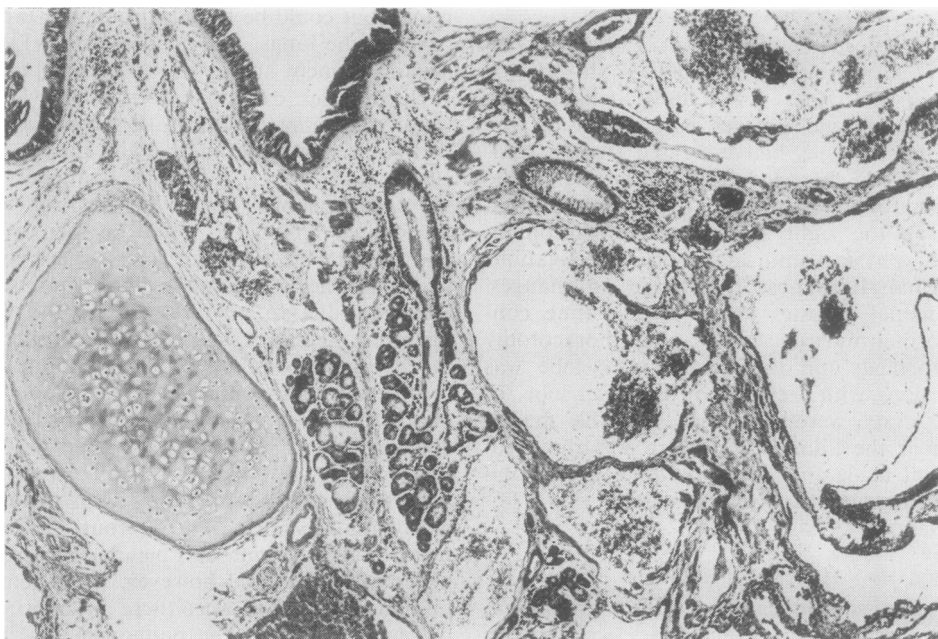

Fig 4 Case 3. Lung histology showing lymphangiectasis around a bronchus (Haematoxylin and Eosin $\times 9$).

Discussion

According to Noonan *et al* (1970) the occurrence of pulmonary lymphangiectases can be divided into three groups:

- (1) Generalised form of lymphangiectasis (lymphoedema with intestinal lymphangiectasis).
- (2) Secondary to pulmonary venous hypertension or obstruction.
- (3) Primary developmental defect of lung.

Lymphangiectasis as a complication of disturbed venous drainage can occur at all ages. Primary lymphangiectasis (groups 1 and 3) according to Noonan *et al.* (1970) have been described almost exclusively in infants and young children.

The oldest cases are reportedly 11 years for group 1 and 5 years for group 3 (Noonan *et al.*, 1970). Solitary primary pulmonary lymphangiectasis is more frequent in boys than in girls. The generalised forms are rare (McKendry and Lindsay, 1957; Frank and Piper, 1959; Fonkalsrud, 1974). Cases of primary lymphangiectasis limited to the lungs are often fatal, while generalised cases have a better prognosis, probably because the pulmonary lesions are less pronounced.

In our cases, all male, one (case 2) showed changes limited to one lobe. In the other two

cases two lobes were affected and dilated lymphatics were also found in the mediastinum. In none of the cases could a generalised disease of the lymph vessels, for instance affecting the intestines, be shown. The remaining pulmonary tissue was normal; on the side of the thoracotomy this was established by direct examination, and on the opposite side by radiological examination. Subsequent investigation of the patients also failed to show signs of similar changes in other organs.

The histological investigation of our cases lends weight to the suggestion that the lymphangiectases are congenital rather than the result of chronic congestion. In all cases the pulmonary arteries were normal, and in two the pulmonary veins were without pathological changes. In one patient (case 2) some veins showed slight thickening of the walls. This was also the case in which there was an abnormal venous drainage of the upper left lobe into the vein of the lower lobe. The supposition, however, that the pronounced dilatation of lymphatics could have resulted from chronic pulmonary congestion is untenable in our opinion. If pulmonary venous hypertension causes lymphangiectasis, pronounced arteriolarisation of pulmonary veins and pronounced pulmonary arterial lesions are to be expected (Wagenvoort and Wagenvoort, 1977). The

congenitally abnormal venous course in this case rather should support the idea that the changes of the lymphatics are equally congenital.

Our cases 1 and 3 do not fit very well in Noonan's classification as they were not limited to the lung nor did they have intestinal involvement. A more appropriate classification therefore might be:

I Primary: (a) limited to the lungs, (b) with pulmonary and mediastinal involvement, and (c) generalised.

II Secondary: to obstruction of the pulmonary venous outflow.

In this new classification our cases 1 and 3 would therefore come into group Ib and our case 2 into group Ia.

The unilateral nature of the lymphangiectasis, which is supported by the follow-up findings, has not been described previously. Our findings would indicate that lymphangiectasis should be considered in the clinical differential diagnosis of "pulmonary cysts" in children and young adults.

References

- Felman, A H, Rhatigan, R M, and Pierson, K K (1972). Pulmonary lymphangiectasia. *American Journal of Roentgenology*, **116**, 548-558.
- Fonkalsrud, E W (1974). Surgical management of congenital malformations of the lymphatic system. *American Journal of Surgery*, **128**, 152-159.
- Frank, J, and Piper, P G (1959). Pulmonary cystic lymphangiectasis. *Journal of the American Medical Association*, **171**, 1094-1098.
- McKendry, J B J, and Lindsay, W K (1957). Congenital defects of the lymphatics in infancy. *Pediatrics*, **19**, 21-34.
- Noonan, J A, Walters, L R, and Reeves, J T (1970). Congenital pulmonary lymphangiectasis. *American Journal Diseases of Children*, **120**, 314-319.
- Wagenvoort, C A, and Wagenvoort, N (1977). *Pathology of Pulmonary Hypertension*, p 302. J Wiley and Sons, New York.

Requests for reprints to: Dr C A Wagenvoort, Department of Pathology, Wilhelmina Gasthuis, University of Amsterdam, Amsterdam, the Netherlands.