

# *Klebsiella pneumoniae* Liver Abscess and Metastatic Endophthalmitis

Journal of Investigative Medicine High  
Impact Case Reports  
January-March 2016: 1–3  
© 2015 American Federation for  
Medical Research  
DOI: 10.1177/2324709615624125  
hic.sagepub.com



Jason T. Wells, MD<sup>1</sup>, Catherine R. Lewis, MD, PhD<sup>2</sup>,  
Omar K. Danner, MD, FACS<sup>2</sup>, Kenneth L. Wilson, MD, FACS<sup>2</sup>,  
and L. Ray Matthews, MD, FACS<sup>2</sup>

## Abstract

**Introduction.** *Klebsiella pneumoniae* is a well-known cause of liver abscess. Higher rates of liver abscess associated with *Klebsiella pneumoniae* are seen in Taiwan. Metastatic endophthalmitis is a common complication associated with a poor prognosis despite aggressive therapy. **Case Report.** We report a case of a 67-year-old Korean female with *Klebsiella pneumoniae* liver abscess. The patient developed metastatic endophthalmitis and ultimately succumbed to her disease despite aggressive medical and surgical treatment. **Conclusion.** Dissemination of *Klebsiella pneumoniae* is associated with significant morbidity and mortality. Liver abscesses preferably should be treated with percutaneous drainage, but surgical treatment is needed in some cases. Metastatic spread to the eye is a common complication that must be treated aggressively with intravenous antibiotics and surgical intervention if necessary.

## Keywords

*Klebsiella pneumoniae*, liver abscess, metastatic endophthalmitis, percutaneous drainage

Received 19 November 2015. Accepted for publication 23 November 2015

## Introduction

*Klebsiella pneumoniae* has been implicated as a common cause of infection in the human body. The liver is a common source of infection, either due to a primary hepatobiliary disease or secondary to an intra-abdominal infection. Although rare, there is significant mortality and morbidity associated with this organism.

## Case Report

This patient was a 67-year-old previously healthy Korean female with no significant past medical or surgical history, who presented with a 7-day history of progressively worsening abdominal pain. She had recently come to America from South Korea to stay with her daughter about 13 months ago. The patient's vital signs were within normal limits. Abdominal examination was significant for diffuse tenderness to palpation, distention, and voluntary guarding. White blood cell count was 16 000 / $\mu$ L and alkaline phosphatase was 133 U/L. Computed tomography (CT) scan of the abdomen showed a large hepatic abscess noted in the right lobe of the liver (Figure 1).

The patient was treated aggressively for septic shock over the next several days with vancomycin and zosyn. The patient was taken to the operating room for an exploratory

laparotomy for likely perforated hepatic abscess. A large hepatic abscess was noted within the right lobe, with free suppurative fluid in the abdomen. There was an extensive amount of fibrinous exudate present within the abdominal cavity, which was irrigated thoroughly with normal saline. The abscess cavity was opened and Penrose drains were placed into the abscess cavity and brought out through the skin to allow for drainage. The abdomen was closed in the standard fashion. Postoperatively, the patient was admitted to the surgical intensive care unit and treated for septic shock. Intra-abdominal cultures taken during the surgery were positive for *Klebsiella pneumoniae*. Despite intravenous antibiotics therapy, the patient continued to have severe sepsis. Infectious Disease services were consulted to assist in the patient's management. Her antibiotic course was later changed to imipenem, vancomycin, and fluconazole due to the development of microbial resistance. On postoperative day 7, the patient developed swelling and purulent drainage

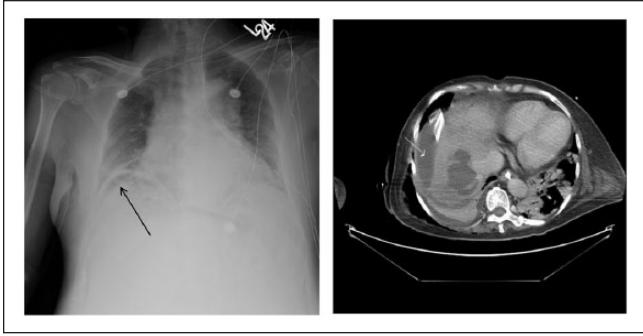
<sup>1</sup>Greenville Health System, Greenville, SC, USA

<sup>2</sup>Morehouse School of Medicine, Atlanta, GA, USA

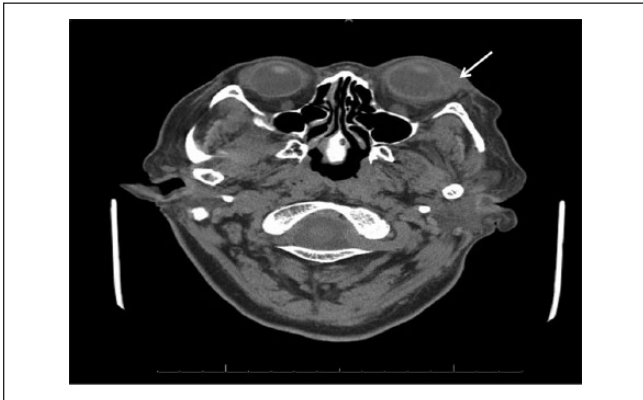## Corresponding Author:

L. Ray Matthews, MD, FACS, Department of Surgery, Morehouse School of Medicine, 720 Westview Drive, SW, Atlanta, GA 30310, USA.  
Email: lemattthews@msm.edu





**Figure 1.** (A) Chest x-ray demonstrating a crescentic lucency underneath the right hemidiaphragm concerning for free air within the abdomen (black arrow). (B) Large right liver abscess (white arrow).



**Figure 2.** Abnormal intraocular enhancement of the left globe involving both the posterior and anterior chambers consistent with active endophthalmitis (arrow).

from the left eye. A CT scan of the orbits showed a detached retina on the left with opacification and endophthalmitis (Figure 2).

Intravitreal injections of vancomycin and ceftazidime antibiotics were given for 8 days and the patient was subsequently taken to the operating room for enucleation and washout by the ophthalmology service. Pathology was consistent with Panophthalmitis. Tissue cultures of the eye, optic nerve, and bronchial washings were also positive for *Klebsiella pneumoniae*. Despite aggressive medical and surgical efforts, the patient eventually succumbed to multiorgan system failure from septic shock on postoperative day 45.

## Discussion

The most common location for a visceral abscess is the liver. The incidence of liver abscesses depends on the population studied. The rate can be estimated at 2.3 cases per 100 000 people, with a higher incidence in men versus women (3.3 to 1.3 per 100 000). Higher rates are reported in Taiwan at 17.6 cases per 100 000.<sup>1-4</sup> Although the mortality rate is relatively

low, the prognosis in patients who develop metastatic endophthalmitis is poor despite aggressive therapy, as many patients develop impaired vision or blindness.<sup>5</sup> While rare, this condition has significant morbidity that depends on the type and source of the primary infection.

Most incidences of metastatic infection are reported in Asia.<sup>5-7</sup> At least one retrospective review in the United States examined 79 cases of liver abscess during which *Klebsiella pneumoniae* was the most commonly found pathogen in 43% of patients.<sup>8</sup> Primary *Klebsiella* liver abscesses commonly occur in diabetics, but other comorbidities can increase the risk of this infection.<sup>7,9-11</sup>

The most common clinical manifestations of a primary liver abscess include fever, right upper quadrant tenderness, nausea, vomiting, diarrhea, leukocytosis, and elevated alanine aminotransferase, aspartate aminotransferase, alkaline phosphatase and bilirubin.<sup>7</sup> Approximately 13% of patients with a primary liver abscess develop metastatic infections, with the most common manifestations being endophthalmitis, meningitis, and cerebral abscess.<sup>5,7,9,12</sup> *Klebsiella pneumoniae* is the most common bacterial isolate to cause metastatic infections.<sup>9</sup>

The imaging modalities of choice for diagnosis of a liver abscess are ultrasonography and CT. Once the area of infection has been identified, the preferred method of treatment is percutaneous drainage and intravenous antibiotics. Initial antibiotic treatment should be empiric until sensitivities and specificities have been obtained. The duration of antibiotics should be a total of 4 to 6 weeks. Studies show that abscesses <5 cm in diameter can be treated with simple aspiration and/or by leaving a drainage catheter in place until the output is minimal. For lesions >5 cm, surgical intervention is preferred.<sup>13</sup> In this case, emergent surgical exploration was warranted due to peritonitis and perforation.

## Conclusion

*Klebsiella pneumoniae* dissemination is associated with significant morbidity and mortality. A high index of suspicion for metastatic spread to various other organs including the eye is necessary. Because of the frequency of *Klebsiella*-associated liver abscesses in the Asian population, treatment of *Klebsiella* species should begin until proven otherwise. Early detection of *Klebsiella*-associated endophthalmitis and prompt treatment with aggressive intravenous antibiotics may be the only method to salvage visual acuity and decrease the incidence of overall morbidity and mortality.

## Acknowledgments

We would like to acknowledge the support staff of the Department of Surgery for their editing and critical review.

## Declaration of Conflicting Interests

The author(s) declared no potential conflicts of interest with respect to the research, authorship, and/or publication of this article.

## Funding

The author(s) received no financial support for the research, authorship, and/or publication of this article.

## References

1. Huang CJ, Pitt HA, Lipsett PA, et al. Pyogenic hepatic abscess. Changing trends over 42 years. *Ann Surg.* 1996;223:600-607.
2. Mohsen AH, Green ST, Read RC, McKendrick MW. Liver abscess in adults: ten years experience in a UK centre. *QJM.* 2002;95:797-802.
3. Kaplan GG, Gregson DB, Laupland KB. Population-based study of the epidemiology of and the risk factors for pyogenic liver abscess. *Clin Gastroenterol Hepatol.* 2004;2:1032-1038.
4. Tsai FC, Huang YT, Chang LY, Wang JT. Pyogenic liver abscess as endemic disease, Taiwan. *Emerg Infect Dis.* 2008;14:1592-1600.
5. Fang CT, Lai SY, Yi WC, Hsueh PR, Liu KL, Chang SC. *Klebsiella pneumoniae* genotype K1: an emerging pathogen that causes septic ocular or central nervous system complications from pyogenic liver abscess. *Clin Infect Dis.* 2007;45:284-293.
6. Yu WL, Ko WC, Cheng KC, et al. Association between *rmpA* and *magA* genes and clinical syndromes caused by *Klebsiella pneumoniae* in Taiwan. *Clin Infect Dis.* 2006;42:1351-1358.
7. Wang JH, Liu YC, Lee SS, et al. Primary liver abscess due to *Klebsiella pneumoniae* in Taiwan. *Clin Infect Dis.* 1998;26:1434-1438.
8. Rahimian J, Wilson T, Oram V, Holzman RS. Pyogenic liver abscess: recent trends in etiology and mortality. *Clin Infect Dis.* 2004;39:1654-1659.
9. Yang CC, Yen CH, Ho MW, Wang JH. Comparison of pyogenic liver abscess caused by non-*Klebsiella pneumoniae* and *Klebsiella pneumoniae*. *J Microbiol Immunol Infect.* 2004;37:176-184.
10. Chan KS, Chen CM, Cheng KC, Hou CC, Lin HJ, Yu WL. Pyogenic liver abscess: a retrospective analysis of 107 patients during a 3-year period. *Jpn J Infect Dis.* 2005;58:366-368.
11. Fung CP, Chang FY, Lee SC, et al. A global emerging disease of *Klebsiella pneumoniae* liver abscess: is serotype K1 an important factor for complicated endophthalmitis? *Gut.* 2002;50:420-424.
12. Cheng DL, Liu YC, Yen MY, Liu CY, Wang RS. Septic metastatic lesions of pyogenic liver abscess. Their association with *Klebsiella pneumoniae* bacteremia in diabetic patients. *Arch Intern Med.* 1991;151:1557-1559.
13. Rajak CL, Gupta S, Jain S, Chawla Y, Gulati M, Suri S. Percutaneous treatment of liver abscesses: needle aspiration versus catheter drainage. *AJR Am J Roentgenol.* 1998;170:1035-1039.