

## Short Reports

### Probable malignant transformation of a pulmonary hamartoma

J THOMAS POULSEN, MARIANNE JACOBSEN, AND DORTHE FRANCIS

*From the Institute of Pathological Anatomy, Bispebjerg Hospital, Copenhagen, Denmark*

A pulmonary hamartoma is an uncommon benign tumour arising in the bronchial wall. The component tissues follow the general plan of development and may reach varying degrees of maturity and functional ability (Spencer, 1977). McDonald *et al* (1945) found hamartoma in 0.25% of pulmonary tumours in a necropsy series. Possible malignant transformation in a hamartoma is extremely rare, and only sporadic case reports on malignant hamartomas are at hand (Hayward and Carabasi, 1967). We report a further case.

#### Case report

An 81-year-old woman with no previous stay in hospital was admitted because of a rounded mass 7 cm in diameter in the left lung. Within the next two weeks a fracture developed in the body of the ninth thoracic vertebra.

An aspiration biopsy of the lung infiltrate showed pieces of mesenchymal, partly chondroid material with free oval nuclei consistent with a pulmonary hamartoma. An aspiration biopsy two months later of the fractured bone showed no tumour cells, while a repeated aspiration biopsy of the lung tumour showed, besides chondroid material, an unusual dominance of atypical epithelial elements suggestive of a malignant tumour. Because of pain, local x ray treatment was given to the spine. The patient died six months after admission.

#### NECROPSY FINDINGS

In the proximal part of the left lower lobe a 6 cm diameter rounded tumour was found. Tumour tissue was seen along the left main bronchus with infiltration of the regional lymph nodes. A compression fracture of the body of the ninth thoracic vertebra was noted. No other tumours were found throughout the body.

#### HISTOLOGICAL EXAMINATION

The round tumour consisted of chondromatous islands separated by loose, partly myxomatous connective tissue with areas containing fat cells, and clefts lined with small cylindrical or cuboid epithelial cells. Cilia were seen in some places on the surface of the epithelial cells. About three-quarters of the tumour consisted of this typical hamartoma-like picture, and the periphery was here well demarcated and surrounded by compressed lung tissue.

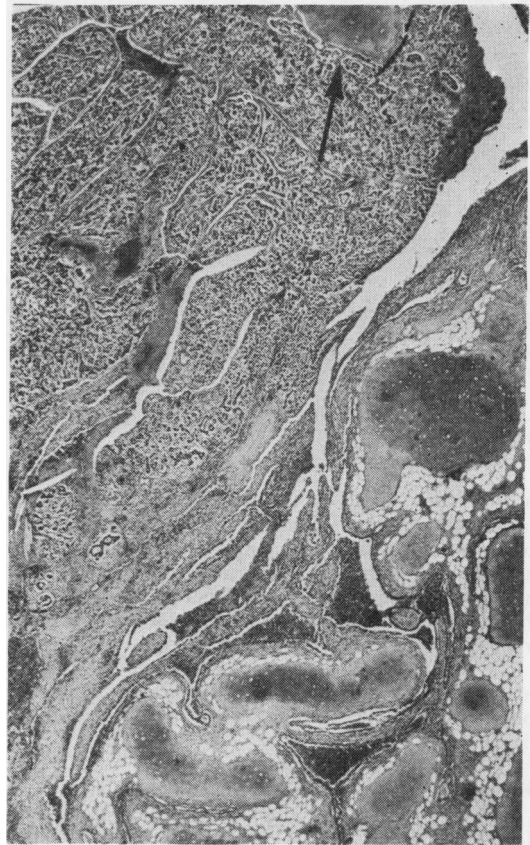

Fig 1 *An area from edge of tumour. In lower right corner is typical cartilage-containing hamartoma. Arrow shows typical malignant tumour tissue surrounding an island of cartilage. Haematoxylin and eosin  $\times 25$  (original specification).*

In the remaining quarter of the tumour the epithelial component had a different appearance. Between the chondromatous islands the tissue was split by numerous clefts and gland-like, epithelial lined spaces and, in some places, diffusely invaded by epithelial-like cells (fig 1). These cells were small and regular, the cytoplasm being scanty or indistinguishable. The picture was that of an immature tumour. Epithelial

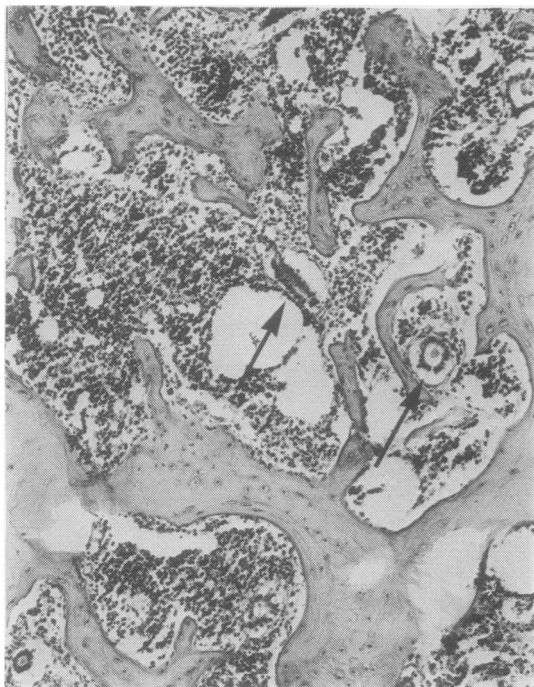


Fig 2 Bone marrow (fractured vertebra) containing several solitary glandlike configurations (arrows). *H and E*  $\times 100$ .

tumour components infiltrated the adjacent part of the surrounding lung tissue, partly growing in alveolar spaces, partly infiltrating along blood vessels. Furthermore, this tumour tissue infiltrated the wall of the left main bronchus including vessels, peripheral nerves, and lymph nodes. Tumour tissue was not seen invading or arising from the mucosal cell lining.

The samples from the fractured spine showed, besides reactive changes, metastatic tumour. Numerous solitary gland-like configurations were encountered (fig 2).

### Discussion

Hayward and Carabasi (1967) have reported a case similar to ours, a malignant adenocarcinoma probably arising in a chondromatous hamartoma. In a critical review of 12 reported cases they concluded that most either lacked evidence that the original tumour was a hamartoma or scarcely showed convincing evidence of malignant change. We were able to review the speci-

mens from one of these cases (Schjødt and Jensen, 1960) and these authors agree with us that their case should more correctly have been classified as a malignant pulmonary blastoma, a tumour entity defined and named by Spencer in 1961. (For ref see Spencer, 1977.)

We have shown a classical chondromatous hamartoma and adjacent malignant metastasising adenomatous tumour tissue. Coincidental development of two independent tumours, a metastatic or a primary adenocarcinoma in the main left bronchus infiltrating the periphery of a hamartoma, is a possible explanation. The following findings may, however, be considered to oppose this theory. Tumour tissue was found only in the left lung and in the spine, so the possibility of metastasis from an adenocarcinoma elsewhere seems unlikely. The malignant adenomatous tumour appears morphologically rather immature with only some signs of differentiation. The picture is quite different from the usual types of primary lung adenocarcinomas. Especially, the configuration of the adenomatous formations in the fractured bone appears different from that which is usually seen in bone metastasis from ordinary lung adenocarcinomas.

Stone and Churg (1977) found certain ultrastructural features indicating that the epithelial cells lining the clefts of a hamartoma could be part of the neoplasm rather than incorporated normal bronchial epithelia. In accordance with this view we have found that the malignant component of our case shows tumour tissue, which is morphologically different from ordinary bronchogenic adenocarcinomas. In our opinion this case is most probably a malignant transformation of the epithelial part of a hamartoma.

### References

- Hayward, R H, and Carabasi, R J (1967). Malignant hamartoma of the lung: fact or fiction? *Journal of Thoracic and Cardiovascular Surgery*, **53**, 457-466.
- McDonald, J R, Harrington, S W, and Clagett, O T (1945). Hamartoma (often called chondroma) of the lung. *Journal of Thoracic Surgery*, **14**, 128-143.
- Schjødt, T, and Jensen, K G (1960). Malignant teratoid tumour of the lung: malignant hamartoma. *Thorax*, **15**, 120-123.
- Spencer, H (1977). *Pathology of the Lung*, 3rd edn, p 973. Pergamon Press, Oxford.
- Stone, F J, and Churg, A M (1977). The ultrastructure of pulmonary hamartoma. *Cancer*, **39**, 1064-1070.

Requests for reprints to: J Thomas Poulsen, 62 Skriverhusene, DK 2620 Albertslund.