

Treatment of postpneumonectomy empyema: the case for fenestration

P GOLDSTRAW*

From the Cardiothoracic Unit, Mearnskirk Hospital, Glasgow

ABSTRACT In Mearnskirk Hospital, Glasgow, 29 patients with postpneumonectomy empyema were treated by fenestration in a 12-year period. Seven of these were not considered fit enough for definitive closure and died of continuing disease or respiratory infection. Twenty-two patients went on to closure of their fenestra, and in 17 (77%) the pneumonectomy space was rendered permanently sterile. If the empyema recurred treatment was repeated but proved less successful. Fenestration is an effective method of dealing with postpneumonectomy empyema, but also has several other advantages, particularly if the empyema is associated with a bronchopleural fistula.

The treatment of postpneumonectomy empyema follows the principles used in the management of any abscess. Drainage is of prime importance initially and can be achieved quickly and readily in the ward if necessary. Closed drainage with underwater seal is required if the empyema presents in the first few days after pneumonectomy while the mediastinum remains mobile and when it presents as an emergency with a large bronchopleural fistula and aspiration into the remaining lung. In most cases, however, drainage can be performed electively, and open drainage has been regarded as more satisfactory. Fenestration, the performance of a skinlined thoracostomy, was first developed by Eloesser in 1935 to manage tuberculous empyemas, and was adapted by Clagett and Geraci (1963) for the treatment of postpneumonectomy empyema. I report the results of treating postpneumonectomy empyema with this procedure, and detail its place in managing patients with this complication.

Patients

In the 12-year period 1964-76, 225 patients underwent pneumonectomy in the cardiothoracic unit, Mearnskirk Hospital, Glasgow. Two hundred and nineteen case records were available for study, and from these 35 cases of postpneumonectomy empyema were discovered. The patients were aged from 21 to 66 (mean 52.4). There were 29 men and

six women, a male to female ratio of 4.8:1. Nineteen patients had undergone left pneumonectomy, 15 right pneumonectomy, one patient a right completion pneumonectomy, and 28 underwent pneumonectomy for carcinoma of the bronchus. Pneumonectomies were performed for inflammatory conditions such as bronchiectasis and tuberculosis (four patients), alveolar cell carcinoma (two), and an unrecognised carcinoid tumour (one). Those patients undergoing pneumonectomy for carcinoma of the bronchus had the usual distribution of cell types—21 patients having squamous carcinoma, four anaplastic carcinoma, two adenocarcinoma, and one oat cell carcinoma. Twelve of the patients fell into tumour stage I, five into stage II, and 11 patients had stage III tumours resected.

In 20% of patients found to have frank pus in their pneumonectomy space no organism was cultured. Of those with positive cultures, *Staphylococcus aureus* was found in two-thirds while the other cases were infected with various coliforms, streptococcal and acid-fast bacilli. Only the initial cultures were regarded as significant since, after drainage, various organisms colonise the pneumonectomy space. The time between pneumonectomy and the discovery of the empyema varied from one week to seven months (mean five weeks). The empyema was apparent within two weeks of operation in 19 cases (54%) and within four weeks in 27 cases (77%). One patient developed a recurrence of his empyema 52 months after completing his treatment for the initial

*Present address: Brompton Hospital, London.

postpneumonectomy empyema. The second infection, like the first, was due to *S aureus*. Fistulae were sought routinely in all patients developing postpneumonectomy empyema. Four patients were found to have bronchopleural fistulae, one an oesophagopleural fistula, and one patient developed a compound fistula affecting bronchus and oesophagus. One of these bronchopleural fistulae occurred in a patient who developed an empyema after pneumonectomy for inflammatory disease, but the rest followed resections for malignant neoplasms.

Treatment

Of the 35 patients developing postpneumonectomy empyema, 29 underwent treatment by fenestration. The other six patients were treated with various techniques early in the series, or else developed their empyema when moribund from other causes. Fenestration was usually performed under general anaesthesia. The middle third of the wound was reopened and 6–8 cm of the underlying rib resected. Opening into the pneumonectomy space through the bed of this rib invariably led to the most dependent lateral extent of the pneumonectomy space. Up to three more ribs were removed with the intervening intercostal bundles to provide a reasonable stoma, and the skin edges were then sutured to the parietal pleura to create a skinlined fenestra. Forty-eight hours after fenestration, irrigations were started and continued daily thereafter. During irrigation the patient was placed in the lateral position with the fenestra forming the highest point in the chest wall. The pneumonectomy space was inspected for fibrin or slough. The space was then mechanically debrided, irrigated with aqueous hibitane solution, and filled with a hibitane solution. After 30–40 minutes the patient was allowed to turn, which drained the antiseptic into a suitable basin. The pneumonectomy space was inspected periodically and bacteriology swabs were taken weekly. The results of these, coupled with observations on the patient's general condition, dictated the timing of closure of the fenestra. All patients were kept in hospital for the duration of their treatment. The mean interval between fenestration and closure was 40 days (21–74). Closure was a minor procedure consisting of mobilisation of the wound margins, identification of tissue planes, final debridement of the space, and closure in layers after displacing all air with a 0.25% solution of neomycin. The resultant wound had to be watertight and remained fluctuant for only a few days.

Results

The results of fenestration are shown in fig 1. Of the 29 patients who underwent fenestration, seven died with advanced disease or respiratory failure before their fenestra could be closed. Of the 22 patients undergoing fenestration and closure, 17 (77%) were clear of infection five weeks to nine years after closure. Eleven (65%) of these patients were followed for at least one year and eight (47%) for more than three years. Five patients had a recurrence of the empyema, usually within three weeks. One empyema recurred 52 months after closure and should probably be considered as a second infection, rather than failure of treatment. Both infections, however, were due to *S aureus*. All the five recurrences were treated by a second fenestration that eradicated the infection in two patients and failed again in three. These three patients were subjected to further procedures and eventually thoracoplasty, but died with continuing sepsis 1–3 years after their second fenestration.

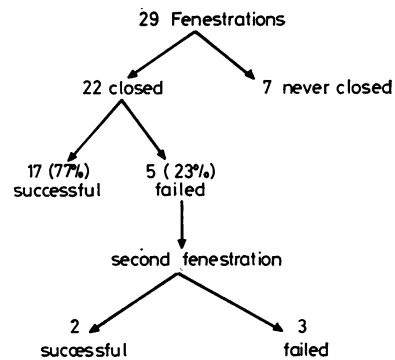


Fig 1 Results of fenestration (Mearns Kirk Hospital).

Discussion

The treatment of postpneumonectomy empyema has three components. Drainage is the initial concern but can only be palliative, since cure is prevented by the bony thorax that forms a rigid wall to the abscess cavity. For the second step the surgeon must obliterate the pneumonectomy space or accept its presence and attempt to sterilise it. The third component consists of identifying and treating any oesophagopleural or bronchopleural fistulae.

DRAINAGE

The usual method of open drainage is rib resection, which permits the use of a wider bore tube than could be inserted in the intercostal

space and delays the inherent tendency of the track to close. A rib resection is a minor surgical procedure, tolerated by even the most debilitated patient, and can be performed under local anaesthesia. At the initial rib resection a limited view is afforded into the pneumonectomy space, and the more accessible fibrinous material may be removed. The wide bore tube inserted to keep the track patent is uncomfortable, requires changing periodically, and will displace on occasions.

For the ill patient, fenestration represents little more stress than a rib resection, and can also be performed under local anaesthesia. The skinlined thoracostomy has little tendency to close spontaneously and this obviates the need for an indwelling tube. The fenestra allows periodic inspection of the space for slough or tumour, free drainage of liquid pus, and mechanical or chemical scouring of fibrin debris that may harbour infection. It may be created as a permanent defect, as used by Dorman *et al* (1973) and Virkkula and Eerola (1974), in which case three or four ribs would be resected. Alternatively, fewer ribs are resected and after sterilisation of the space by daily irrigations of antiseptic, the defect may be closed.

OBLITERATION OR STERILISATION OF THE RIGID ABSCESS CAVITY

Many surgeons are content to perform rib resection and allow reduction of the space to proceed at a slow rate, relying upon the chronic infection to result in the deposition of a progressively thicker cortex on the inner aspect of the chest wall. Many patients undergoing pneumonectomy for bronchogenic carcinoma have limited survival prospects, and the prolonged morbidity of this treatment may seriously detract from the palliation afforded by the pneumonectomy. Thoracoplasty achieves obliteration of the space more rapidly, but it is a formidable surgical procedure and can be undertaken only in fit individuals. It causes permanent disfigurement, and in at least one other report (Zumbro *et al*, 1973) failed to eradicate the infection. Eerola (1976) has suggested obliterating the space using skin pedicles and free skin grafts. This needs a series of operations, and its place in the management of postpneumonectomy empyema would seem limited. It may find a place in younger patients, where the empyema followed pneumonectomy for non-malignant conditions such as trauma, and in whom less extensive procedures have already failed.

Sterilisation of the space is an attractive alternative and may be coupled with tube thoracostomy

or fenestration. In 1970 Dieter *et al* described sterilisation of empyemas in six cases by irrigation with neomycin solution via a chest drain. The empyema in one of these cases followed pneumonectomy and appeared to be eradicated by closed chest drainage with irrigations. No follow-up of this case was presented. Provan (1971) altered the technique by using two catheters, a low one for drainage and a high one for irrigation of antibiotic solutions, and added systemic antibiotics as dictated by bacteriological studies. His results are shown in table 1, along with those of Kärkölä *et al* (1976) who used a similar method. The pooled results show that after 2–4 weeks of treatment, the pneumonectomy space was rendered permanently sterile in 56% of patients. The failures were usually apparent between one week and seven months after cessation of treatment, and one-third of these failures were treated successfully at a second attempt.

In 77% of our patients the pneumonectomy space was rendered permanently sterile by fenestration and closure. These patients had irrigation of their space for 3–11 weeks before closure (mean six). In the original series of Clagett *et al* (1963) patients were allowed home after fenestration to continue their irrigations as outpatients, and this is plainly desirable where local circumstances permit. At closure, the pneumonectomy space is completely filled with 0.25% neomycin solution. There are theoretical dangers in the instillation of neomycin into the pleural space. Adler and Plaut (1972) have shown surprisingly high serum neomycin concentrations one hour after instilling 0.25% neomycin into the empyema cavity, indicating good absorption even through the thick cortex of a chronic empyema. Myerson *et al* (1970) record a case of ototoxicity after 33 irrigations of an empyema space with a 1% solution of neomycin, followed by closure of the fenestra. No toxicity has been reported using a single exposure to 0.25% solution. Potentiation of non-depolarising muscle relaxants by neomycin and other aminoglycoside antibiotics is a further hazard.

Table 1 Results of irrigation and tube thoracostomy

Author	Length of treatment	No	First-time success	Interval to failure	Second-time success
Kärkölä, <i>et al</i> (1976)	Usually one month	7	57%	1/52–7/12	67%
Provan (1971)	12–21 days	2	50%	5/12	—
Combined experience	—	9	56%	—	67%

Table 2 shows the results of fenestration and closure in our series and in other reports. There is a uniformity of success in these five studies. Three-quarters of the empyema cavities were rendered permanently sterile at the first attempt, which is appreciably better than the 56% reported for irrigation and tube thoracostomy (table 1). On second attempts, irrigation and tube thoracostomy proved marginally more successful than fenestration, although the numbers in these studies were small.

Table 2 Results of fenestration

Author	Length of treatment	No	First-time success	Interval to failure	Second-time success
Adler and Plaut (1972)	5-12 weeks	3	100%	—	—
Stafford and Clagett (1972)	4-8 weeks	18	61%	1/12-6 yr	60%
Virkkula and Eerola (1974)	6.5 months	13	77%	—	—
Zumbro, <i>et al</i> (1973)	6-8 weeks	3	100%	—	—
Present study	40 days	22	77%	2/52-52/12	40%
Combined experience	—	59	75%	—	50%

The foregoing methods of treatment rely on prolonged drainage and sterilisation. Conklin (1968) attempted to telescope both these components into a single procedure. He performed a second thoracotomy, debrided the space, and after filling it with neomycin solution closed the chest without drainage. Surprisingly, in one of his two cases the infection was apparently eradicated.

CLOSURE OF FISTULAE

Bronchopleural and oesophagopleural fistulae must be sought routinely, since they are of importance aetiologically and therapeutically. A bronchopleural fistula makes drainage imperative to prevent aspiration, and as long as it persists, any sterilisation of the space can only be temporary. Once satisfactory drainage has been established, small bronchopleural fistulae may be left to close spontaneously, although irrigation may be hazardous. Fenestration permits the use of antiseptic packs to deslough and sterilise the space while closure is progressing. Major fistulae usually require operative closure (Naef, 1976). Until recently this has meant major operations to re-amputate the stump, cover the defect with muscle pedicles, or collapse the chest wall on to the fistulae. Mr R A McCluskie, at Hairmyres Hospital, near Glasgow, has recently treated a

major bronchopleural fistula by an adaptation of his chemical cautery treatment for oesophageal fistulae. His patient underwent emergency pneumonectomy in a general surgical unit for uncontrollable blood loss after a shotgun injury to the left chest. He had a stormy postoperative course and developed an empyema. Bronchograms (fig 2) showed retention of most of the main bronchus and a fistula from the stump of the left upper lobe bronchus. Bronchoscopic chemical cautery was performed on three occasions, after which bronchograms showed no evidence of the previous stump and no fistula (fig 3). Bronchoscopy confirmed an appearance indistinguishable from the expected result after pneumonectomy.

Conclusion

The following treatment schedule is proposed (fig 4):

The diagnosis should be established and any underlying additional problems detected.

The next step is to perform fenestration. The space can be debrided and inspected, and thereafter irrigated daily with antiseptic solution.

In the presence of a fistula, sterilisation may be attempted by wet antiseptic packs, while chemical cautery is used to speed closure of the fistula.

Once the fistula is closed, irrigation may be started and most patients may be allowed home

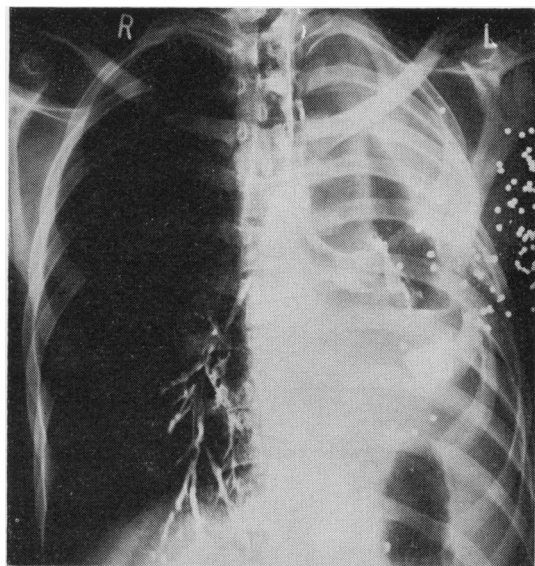


Fig 2 Initial bronchogram showing left bronchial tree and fistula from upper lobe stump. Shotgun pellets are visible in chest wall.

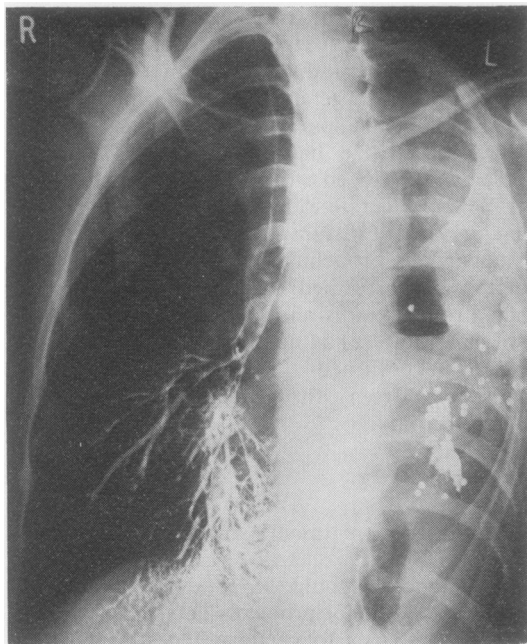


Fig 3 Bronchogram after course of chemical cautery. Dye in left pneumonectomy space remains from initial bronchogram.

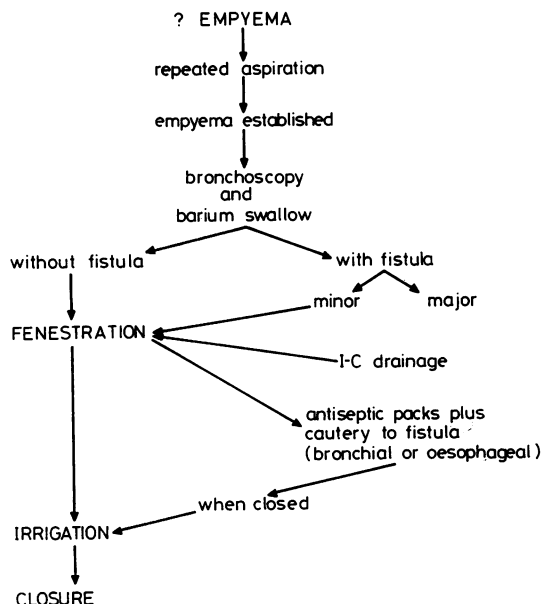


Fig 4 Postpneumonectomy empyema treatment schedule.

to continue treatment with the district nurse.

Periodic inspections and bacterial surveys, coupled with observation of the patient's general condition, will dictate the timing for closure of the fenestra. This step may have to be deferred indefinitely in some cases.

If the empyema recurs, the programme can be repeated.

I thank Mr R S Barclay, Mr T Welsh, and Mr N McSwan, consultant cardiothoracic surgeons, Mearnskirk Hospital, Glasgow, for permission to review the patients under their care; the late Professor P K Caves for help in preparing the manuscript; Mrs J Lowe and her colleagues in the Medical Illustration Department, Glasgow Royal Infirmary, and Miss M Tolland for her secretarial help.

References

- Adler, R H, and Plaut, M E (1972). Postpneumonectomy empyema. *Surgery*, **71**, 210-214.
- Clagett, O T, and Geraci, J E (1963). A procedure for the management of postpneumonectomy empyema. *Journal of Thoracic and Cardiovascular Surgery*, **45**, 141-145.
- Conklin, W S (1968). Postpneumonectomy empyema, single-stage operative treatment. *Journal of Thoracic and Cardiovascular Surgery*, **55**, 634-637.
- Dieter, R A, Pifarré, R, Neville, W E, Magno, M, and Jasuja, M (1970). Empyema treated with neomycin irrigation and closed chest drainage. *Journal of Thoracic and Cardiovascular Surgery*, **59**, 496-500.
- Dorman, J P, Campbell, D, Grover, F L, and Trinkle, J K (1973). Open thoracostomy drainage of postpneumonectomy empyema with bronchopleural fistula. *Journal of Thoracic and Cardiovascular Surgery*, **66**, 979-981.
- Eerola, S (1976). Pedicle thoracoplasty and free skin transplantations in the treatment of the open postpneumonectomy cavity after empyema. *Scandinavian Journal of Thoracic and Cardiovascular Surgery*, **10**, 175-179.
- Eloesser, L (1935). An operation for tuberculous empyema. *Surgery, Gynaecology and Obstetrics*, **60**, 1096-1097.
- Kärkölä, P, Kairaluoma, M I, and Larmi, T K I (1976). Postpneumonectomy empyema in pulmonary carcinoma patients. *Journal of Thoracic and Cardiovascular Surgery*, **72**, 319-322.
- Myerson, M, Knight, H F, and Gambarini, A J (1970). Intrapleural neomycin causing ototoxicity. *Annals of Thoracic Surgery*, **9**, 483-486.
- Naef, A P (1976). Prevention of recurrent empyema. *Annals of Thoracic Surgery*, **21**, 578.

Provan, J L (1971). The management of post-pneumonectomy empyema. *Journal of Thoracic and Cardiovascular Surgery*, **61**, 107-109.

Stafford, E G, and Clagett, O T (1972). Post-pneumonectomy empyema: neomycin instillation and definitive closure. *Journal of Thoracic and Cardiovascular Surgery*, **63**, 771-775.

Virkkula, L, and Eerola, S (1974). Treatment of post-pneumonectomy empyema. *Scandinavian Journal of Thoracic and Cardiovascular Surgery*, **8**, 133-137.

Zumbro, G L, Treasure, R, Geiger, J P, and Green, D C (1973). Empyema after pneumonectomy. *Annals of Thoracic Surgery*, **15**, 615-621.

Requests for reprints to: Mr P Goldstraw, Cardiothoracic Unit, Brompton Hospital, Fulham Road, London SW3.

Clinical Cytopathology for Pathologists—Postgraduate Course

Baltimore, Maryland, USA: 14-25 April 1980

The Twenty-first Postgraduate Institute for Pathologists in Clinical Cytopathology is to be given at The Johns Hopkins University School of Medicine and The Johns Hopkins Hospital. The full two-week programme is designed for pathologists who are certified (or qualified) by the American Board of Pathology (PA) or their international equivalents.

Application is to be made before 7 March 1980. For details, write: John K Frost, MD, 610 Pathology Building, The Johns Hopkins Hospital, Baltimore, Maryland 21205, USA. The language of the course is English.