

# Distribution and ultrastructural characteristics of Feyrter cells in the rat and hamster airway epithelium

NIGEL A EDMONDSON AND DAVID J LEWIS

*From the Huntingdon Research Centre, Huntingdon*

**ABSTRACT** Feyrter cells were found both singly and in groups at all levels of the respiratory tract studied in both rats and Syrian golden hamsters. Particularly large and prominent groups of Feyrter cells were present at bronchiolar bifurcations and bronchiolar-alveolar junctions. Single Feyrter cells were also found throughout the respiratory tract, but their distribution appeared entirely random. In all cases examined the groups of Feyrter cells were overlaid by intermediate and serous secretory epithelial cells. Occasionally small areas of the Feyrter cells were exposed to the airway lumen. Small canaliculi-like intercellular spaces were present between adjacent Feyrter cells. Single unmyelinated axons which contained neurotubules, mitochondria, and vesicles were occasionally seen in close association with Feyrter cells.

Both individual and groups of Feyrter argyrophilic cells (Feyrter cells) have been observed in the bronchial epithelium of foetal rats,<sup>1</sup> mice,<sup>2</sup> man,<sup>3</sup> and birds.<sup>4</sup> Feyrter cells are known to be functionally and structurally related to the cells of the APUD series<sup>5</sup> and possess granules with electron-dense cores which are thought to contain serotonin.<sup>6</sup> They have also been reported to be associated with intraepithelial non-myelinated axons<sup>7,8</sup> which arise from myelinated nerves in the bronchial lamina propria.<sup>9</sup> It has been postulated that the groups of Feyrter cells may be sensory receptor sites.<sup>4,10</sup>

Feyrter cells have been thought for some time to be the source of bronchial carcinoid tumour.<sup>11,12</sup> However this has not been demonstrated in an animal model, although hyperplastic areas of Feyrter cells have recently been reported in Syrian golden hamsters treated with diethylnitrosamine (DEN).<sup>13</sup> In the most comprehensive ultrastructural investigation of the rat respiratory epithelium to date,<sup>14</sup> Feyrter cells were rarely found and then only in the trachea.

The importance of these findings in relation to routine inhalation experiments and the infrequent finding of aggregates of Feyrter cells in our routine studies encouraged us to obtain more information about this cell type. Therefore, in the present study the distribution and ultrastructural

characteristics of Feyrter cells were studied in detail in the rat and hamster.

## Methods

Twenty 300 gram, albino, hysterectomy-derived rats of the CD strain of Sprague-Dawley origin (obtained from Charles River UK Limited, Manston, Kent) and five 95 gram Syrian hamsters (obtained from MK Wright, The Beeches, Catchingdon, Chelmsford, Essex) were used in this study.

All animals were killed by an intraperitoneal injection of sodium pentobarbitone (Abbot Laboratories Limited, Queenborough, Kent). The thoracic viscera were exposed and the trachea cut halfway along its length. The lungs were then removed and infused, via the trachea, using the constant pressure apparatus of Fawell and Lewis,<sup>15</sup> with 4% glutaraldehyde buffered with 0.1 M cacodylate to pH 7.3.

After fixation, 1 mm thick serial rings were taken from the left bronchiolus, washed in buffer, and postfixed in 1% osmium tetroxide buffered with 0.1 M cacodylate to pH 7.3 for two hours at 4°C. The tissues were dehydrated in ascending grades of alcohol and embedded in Epon 812. One micron survey sections were cut and stained with 1% toluidine blue for examination with the light microscope. Silver/gold ultra-thin sections were taken of bronchiolar areas

Address for reprint requests: NA Edmondson, Huntingdon Research Centre, Huntingdon, Cambridgeshire PE18 6ES.

thought to contain groups of Feyrter cells, mounted on copper grids, and subsequently stained with uranyl acetate and lead citrate. The sections were examined using a Philips EM 300, operating at 60 kV.

## Results

By light microscopy, groups of cells believed to represent Feyrter cells were found at all levels of the bronchiolar epithelium in both rats and hamsters. They appeared as light-staining cells at the base of the epithelium, overlaid by non-ciliated cells but surrounded by respiratory epithelium. Groups of several Feyrter cells were found at bronchiolar/alveolar junctions. These groups were considered to correspond to the aggregations of cells occasionally observed in paraffin sections. The groups of Feyrter cells found at bronchiolar bifurcations were larger and occasionally protruded into the lumen (fig 1). Single Feyrter cells were occasionally found at all levels of the airway but their distribution appeared entirely random.

Ultrastructurally the cuboidal Feyrter cells (fig 2) had a single ovoid nucleus with prominent nucleoli and occasional small invaginations. Numerous small (approximately 1100 Å) membrane-bound, dense-cored granules were present in the cytoplasm, predominantly at the base of the cell (fig 3). The density of the granules' central core varied within the same cell and some, mainly situated in the luminal aspect, appeared empty.

The cytoplasm of the Feyrter cells contained a well-developed perinuclear Golgi zone, several bundles of fibrils, numerous free ribosomes, occasional microtubules, occasional lipid droplets, short profiles of rough endoplasmic reticulum, and several small mitochondria. The hamster Feyrter cells (fig 4) appeared to contain more cytoplasmic fibrils than those of the rat.

Occasional regions of the Feyrter cells were exposed to the airway lumen. In these regions a tight junction (zonula occludens) was present between the Feyrter cell and adjacent epithelial cells. The luminal surface of these Feyrter cells possessed occasional small microvilli which pro-

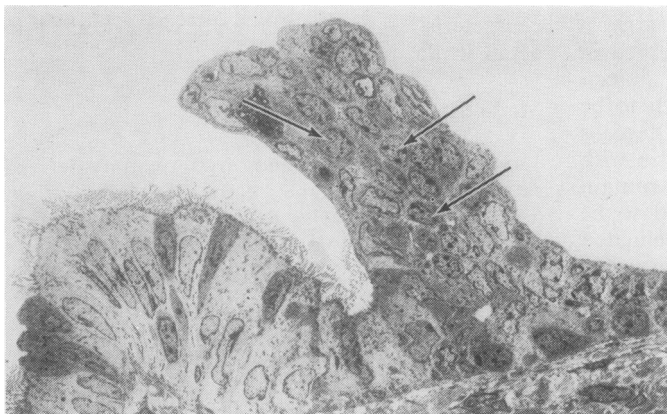


Fig 1 An aggregate of Feyrter cells (arrows) at a bronchiolar bifurcation in the rat. Note how the aggregate protrudes into the lumen. Original magnification  $\times 1300$ .

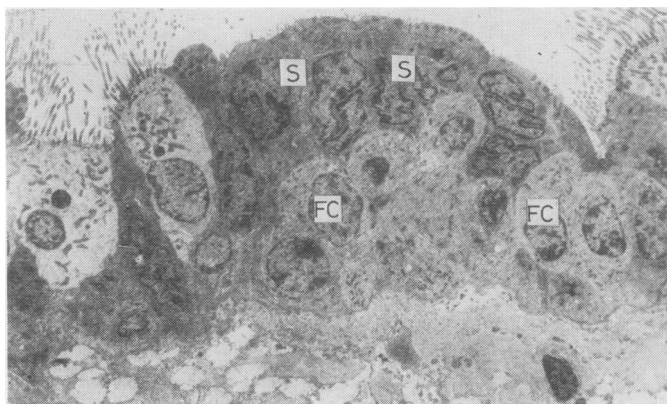


Fig 2 An aggregate of Feyrter cells (FC) in the rat bronchiolar epithelium overlaid by electron-dense secretory cells (S), and surrounded by normal bronchial epithelium. Original magnification  $\times 2600$ .

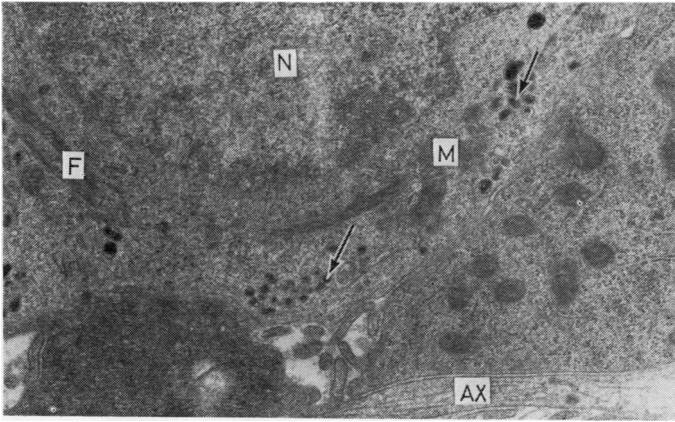


Fig 3 Hamster Feyrter cell showing basally situated granules with electron-dense cores (arrows). Nucleus (N), mitochondria (M), and bundles of perinuclear fibrils (F) are also present. Note single unmyelinated axon (AX) in close proximity to the Feyrter cell. Original magnification  $\times 24\ 400$ .

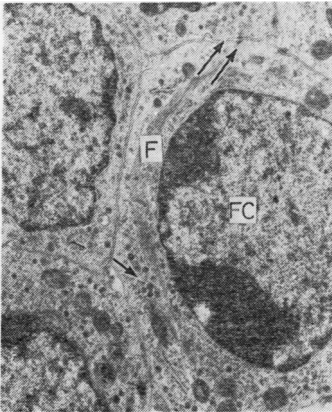


Fig 4 Hamster Feyrter cell (FC) containing granules (arrow) and bundles of perinuclear fibrils (F). Note parallel cell membranes with occasional small desmosomes (double arrow). Original magnification  $\times 16\ 200$ .

jected into the bronchial lumen.

The cell membranes of adjacent Feyrter cells were usually parallel and occasional small desmosomes (fig 4) were found, especially in the larger aggregates. In the large aggregates, small canaliculi-like spaces (figs 4 and 5) were usually found

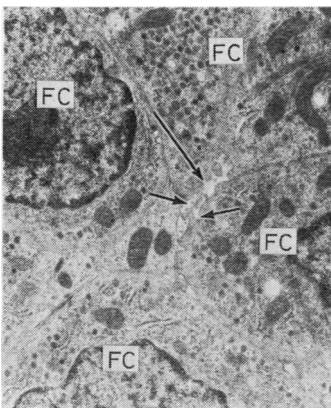


Fig 5 Canaliculus-like space (large arrow) at the junction of four hamster Feyrter cells (FC). Note microvilli projecting into the lumen and intracanalicular membrane-bound vesicles (small arrows). Original magnification  $\times 18\ 100$ .

at the junctions of the cells. These canaliculi often contained short microvilli and occasional membrane-bound vesicles.

In all areas containing aggregates of Feyrter cells the overlying cells had an electron-dense cytoplasm. Occasionally the cells contained a few electron-dense secretory granules in the apical region.

Occasional single unmyelinated axons containing neurotubules, mitochondria, and vesicles were found in the epithelium (fig 3). A close association was often observed between these axons and Feyrter cells.

## Discussion

This electron microscopical study confirms the presence of groups of Feyrter cells in the airway epithelium of both the mature Sprague-Dawley rat and Syrian golden hamster. The ultrastructural characteristics of these groups of Feyrter cells are similar to those previously reported in other animals.<sup>2-8</sup> In all groups (except the large aggregates at bronchiolar bifurcations) of Feyrter cells studied, single unmyelinated axons were found in close association, similar to those previously reported associated with individual Feyrter cells.<sup>16</sup> These axons are considered to be sensory in nature as they have been shown to contain neurotubules and mitochondria.<sup>3, 16</sup> Similar examples of the association between unmyelinated axons and specialised epithelial cells can also be found in the taste buds and the carotid body,<sup>17</sup> where they have a chemoreceptor function.

Our findings support the view that the axons are probably sensory and together with the groups of Feyrter cells form a sensory receptor unit. This view is further supported by the fact

that the Feyrter cells are often exposed to the bronchial lumen, possibly enabling them to detect substances in a similar way to other chemoreceptors. The fact that the Feyrter cell granules are predominantly at the base of the cells and in close proximity to the intraepithelial axons suggest that they may be responsible for stimulation of the axons.

Although axons were not always found associated with the large aggregates of Feyrter cells at bronchiolar bifurcations, the possibility that they were present but not in our section plane cannot be discounted. The canaliculi found between Feyrter cells in the large aggregates are of uncertain significance; however, they could be responsible for transport of substances to and from the Feyrter cells.

There is good evidence that the bronchial carcinoid tumour and oat cell carcinoma are derived from the bronchial Feyrter cells, as neurosecretory type granules are present in the tumour cells.<sup>7 11 12</sup> This view is further supported by the presence of large amounts of serotonin in both the tissue and serum in these cases.<sup>18</sup> Further, significant changes in both the size of Golgi complex and the number of neurosecretory type granules in Feyrter cells have been found in human dysplastic bronchial epithelium.<sup>19</sup>

An animal model has not been established for the bronchial carcinoid tumour because of inability to induce this type of neoplasm experimentally. Both diethyl-nitrosamine (DEN) and N-dibutyl-nitrosamine (DBN) were reported to produce hyperplasia of Feyrter cells in the Syrian golden hamster.<sup>18 20</sup> This hyperplasia of Feyrter cells was reported to occur after only two or three weeks of treatment with either DEN or DBN. Associated with this hyperplasia was an increase in the number of perinuclear filaments in Feyrter cells. However, neither single nor groups of Feyrter cells were found in the control animals of these studies.

In the present study, however, groups of up to approximately 40 Feyrter cells were found in the epithelium of the untreated control Syrian golden hamsters. It is also interesting to note that there is a larger number of perinuclear fibrils in the Feyrter cells of the hamster than in the rat.

## References

- 1 Cutz E, Chan E, Wong V, Conen PE. Endocrine cells in rat fetal lungs. *Lab Invest* 1974; **30**:458-64.
- 2 Hung KS, Hertwerk MS, Hardy JD, Loosli CG. Ultrastructure of nerves and associated cells in bronchiolar epithelium of the mouse lung. *J Ultrastruct Res* 1973; **43**:426-72.
- 3 Cutz E, Conen PE. Endocrine-like cells in human fetal lungs: an electron microscopic study. *Anat Rec* 1972; **173**:115-22.
- 4 Cook RD, King AS. A neurite-receptor complex in the Avian lung: electron microscopical observations. *Experientia* 1969; **25**:1162-3.
- 5 Pearse AGE. The APUD cell concept and its implications in pathology. *Pathol Annu* 1974; **9**:27-41.
- 6 Lauweryns JM, Cokelaere M, Theunynck P. Serotonia producing neuroepithelial bodies in rabbit respiratory mucosa. *Science* 1973; **180**:410-
- 7 Bensch KG, Gordon GB, Miller LR. Studies on the bronchial counterpart of the Kulchitsky (Argentaffin) cell and innervation of bronchial glands. *J Ultrastruct Res* 1965; **12**:668-86.
- 8 Lauweryns JM, Cokelaere M, Theunynck P. Neuro-epithelial bodies in the respiratory mucosa of various mammals. *Z Zellforsch Mikrosk Anat* 1972; **135**:569-92.
- 9 Hung KS, Loosli CG. Bronchiolar neuro-epithelial bodies in the neonatal mouse lungs. *Am J Anat* 1973; **140**:191-200.
- 10 Lauweryns JM, Peuskens JC. Neuro-epithelial bodies (neuroreceptor or sensory organs?) in a human infant bronchial and bronchiolar epithelium. *Anat Rec* 1971; **172**:471-81.
- 11 Toker C. Observations on the ultrastructure of a bronchial adenoma (carcinoid type). *Cancer* 1966; **19**:1948.
- 12 Bensch KG, Corrin B, Pariente R, Spencer H. Oat cell carcinoma of the lung: its origin and relationship to bronchial carcinoid. *Cancer* 1968; **22**:1163-72.
- 13 Reznik-Schüller H. Proliferation of endocrine (APUD-type) cells during early N-diethylnitrosamine-induced lung carcinogenesis in hamsters. *Cancer Letters* 1976; **1**:255-8.
- 14 Jeffery PK, Reid L. New observations of rat airway epithelium: a quantitative and electron microscopical study. *J Anat* 1975; **120**:295-320.
- 15 Fawell JK, Lewis DJ. A simple apparatus for the inflation fixation of lungs at constant pressure. *Lab Anim* 1971; **5**:267-70.
- 16 Jeffery P, Reid L. Intra-epithelial nerves in normal rat airways: a quantitative electron microscopical study. *J Anat* 1972; **114**:35-45.
- 17 Biscoe TJ, Sherkens WE. Ultrastructure of the carotid body. *J Cell Biol* 1966; **30**:563-
- 18 Hattori S, Matsuda M, Tateishi R, Tatsumi N, Terazawa T. Oat-cell carcinoma of the lung containing serotonin granules. *Gann* 1968; **59**:123-30.
- 19 Gould VE, Yannopoulos AD, Sommers SC, Terzakis JA. Neuroendocrine cells in dysplastic bronchi. *Am J Pathol* 1978; **90**:49-
- 20 Reznik-Schüller H. Ultrastructural alterations of APUD cells during nitrosamine-induced lung carcinogenesis. *J Path* 1977; **121**:79-82.