

Ultrastructural localisation of lactoferrin and glycoprotein in human bronchial glands

DENISE BOWES, A E CLARK, AND B CORRIN

From Midhurst Medical Research Institute, Midhurst, Sussex, and the Cardiothoracic Institute, Brompton Hospital, London

ABSTRACT The distribution of lactoferrin and glycoprotein in human bronchial glands has been studied by electron microscopy using an immunoperoxidase method to stain the former and a periodic acid-chromic acid-silver methenamine sequence for the latter, each applied to ultrathin Epon sections. The distribution of lactoferrin corresponds to that of lysozyme.¹ Lactoferrin and lysozyme are both confined to serous acini where the granules show a variable pattern of staining. Some serous granules are filled uniformly with lactoferrin, some lack lactoferrin in a small central core or a thin peripheral rim, and some are completely devoid of lactoferrin. Glycoprotein is present in all mucous granules but only certain serous granules. The latter may be filled uniformly with glycoprotein or glycoprotein may form a thin peripheral coat about centrally located lactoferrin and lysozyme. An electron-dense central core found in some serous granules contains neither glycoprotein, lactoferrin, nor lysozyme.

The serous and mucous acini of the bronchial glands differ from each other both structurally and functionally. Histochemical investigations have shown that whereas both types of acini are involved in glycoprotein secretion, differences exist in the type of glycoprotein found in each.² The serous acini also contain lactoferrin³ and lysozyme.^{4,5} The light microscope has been invaluable in identifying and localising these substances to particular acini, but little is known of their intracellular distribution. We have therefore extended our previous study of the ultrastructural localisation of lysozyme in human bronchial glands¹ to include lactoferrin and glycoprotein, attempting in particular to distinguish each of these three substances within the serous cell.

Methods

Samples of fresh human bronchus were obtained from nine patients undergoing surgery, generally for carcinoma of the lung but in one case, for bronchiectasis. In each case grossly normal tissue was selected and about 10 small pieces were fixed at 4°C for one to six hours in 4% methanol-free

formaldehyde buffered with 0.1 M sodium cacodylate (pH 7.4) containing 7.2% sucrose. They were then rinsed in the buffer, dehydrated in graded ethanols, and embedded in Epon 812. The cytochemical procedures were carried out on ultrathin sections of these non-osmicated tissues but some samples from each case were post-fixed in 1% osmium tetroxide containing 0.12% sucrose buffered to pH 7.4 with veronal acetate; ultrathin Epon sections of these were stained with uranyl acetate and lead citrate. Uranium and lead stains were also applied to ultrathin sections of some non-osmicated tissues. Complete bronchial rings were also fixed in commercial 10% formalin, dehydrated, and embedded in paraffin for light microscopy.

Lactoferrin localisation was carried out by an unlabelled antibody method,⁶ using Dako rabbit antihuman lactoferrin and soluble rabbit anti-horseradish peroxidase/horseradish peroxidase complex. Ultrathin sections were picked up on uncoated nickel grids, and endogenous peroxidase activity quenched by floating them on 10% hydrogen peroxide in methanol. The grids were then dipped into distilled water several times and treated with 10% normal sheep serum in tris-buffered sodium for 10 minutes to minimise the non-specific absorption of antisera. After this and between

Address for reprint requests: Professor B Corrin, Cardiothoracic Institute, Brompton Hospital, Fulham Road, London SW3 6HP.

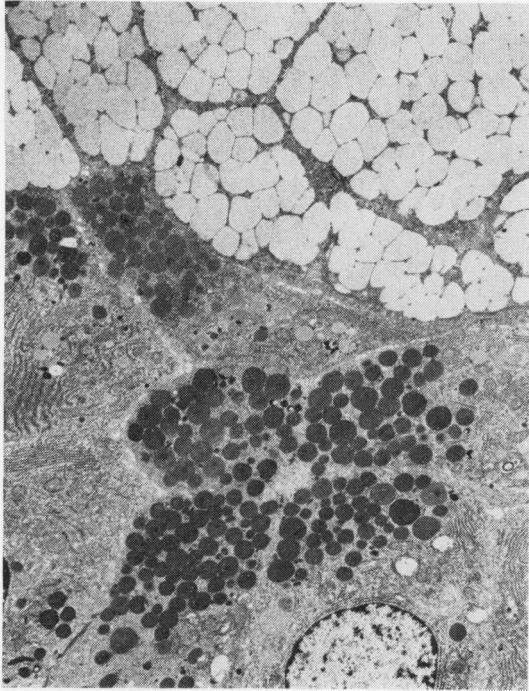
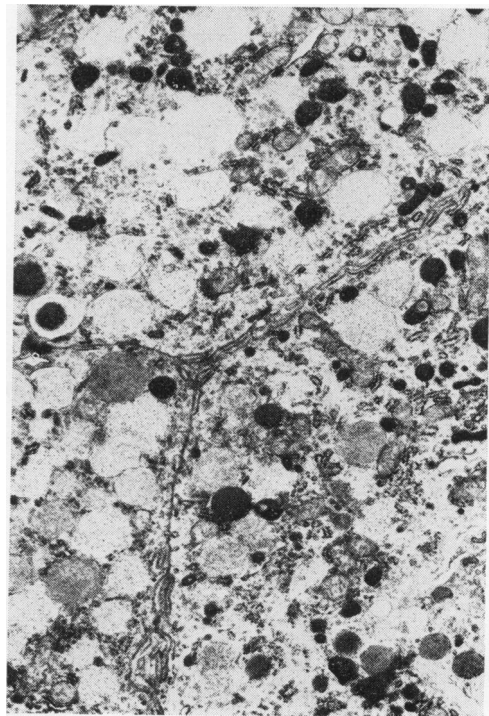


Fig 1 *Mucous granules (above) are electron-lucent and fuse together before discharge. Serous granules (below) are electron-dense and discrete. Osmium tetroxide, uranyl acetate, lead citrate $\times 3640$.*

Fig 2 *Rarely cells contain both mucous and serous granules. Osmium tetroxide, uranyl acetate, lead citrate $\times 8000$.*



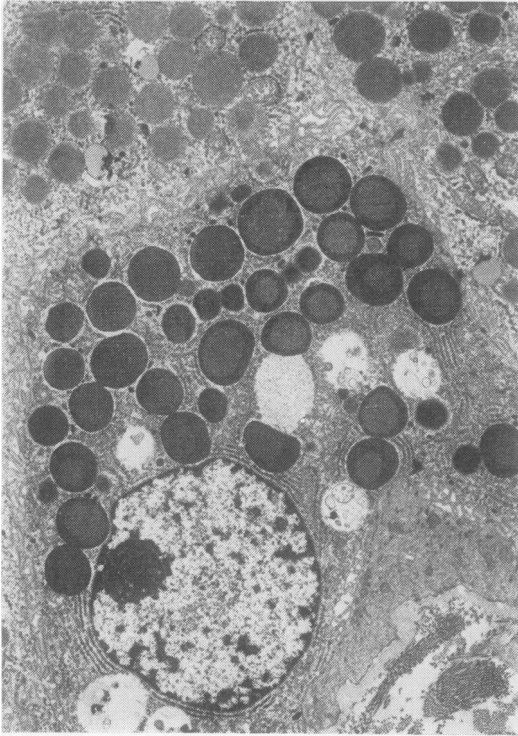
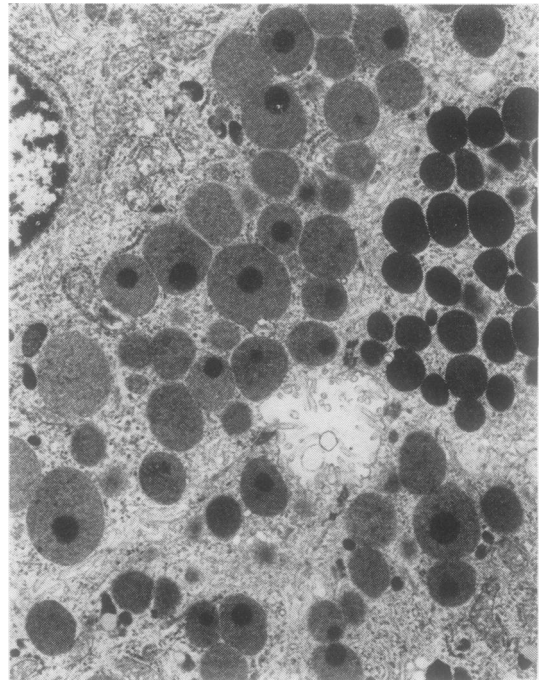


Fig 3 *Some serous granules have a particularly electron-dense outer rim. Osmium tetroxide, uranyl acetate, lead citrate $\times 4750$.*

Fig 4 *Some serous granules are uniform while others have a very electron-dense central core. Osmium tetroxide, uranyl acetate, lead citrate $\times 6000$.*



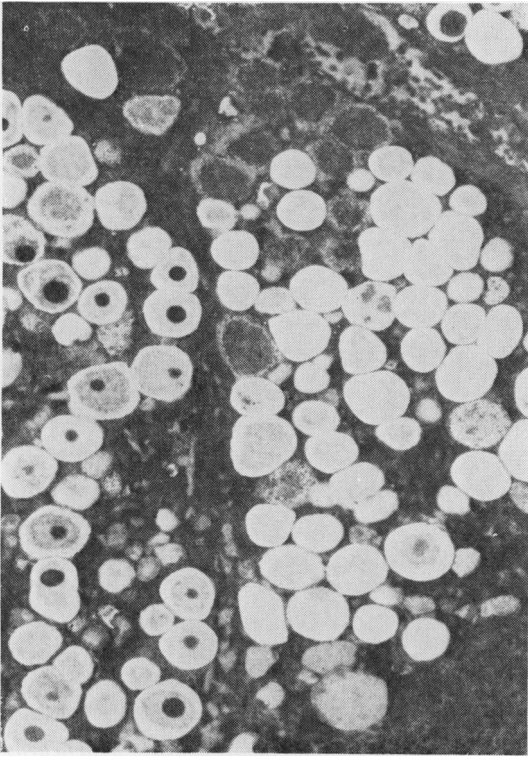
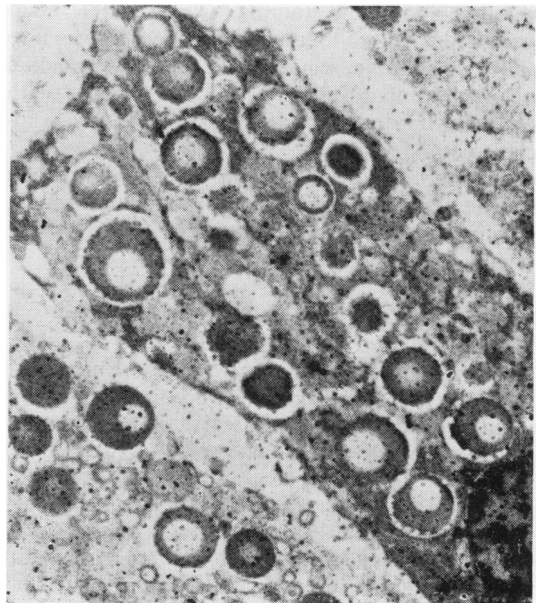


Fig 5 *Without osmium tetroxide the bulk of the serous granule stains poorly while the peripheral rim is completely electron-lucent but the central core is electron-dense. Uranyl acetate, lead citrate $\times 4800$.*

Fig 6 *Serous granules are filled with lactoferrin except for a central core and peripheral rim $\times 8500$.*



subsequent steps the sections were rinsed thoroughly with 1% normal sheep serum in tris-buffered saline. The sections were floated for three minutes on drops of each of the following antisera: (a) rabbit antihuman lactoferrin antiserum at dilutions of 1:2, 1:5, or 1:10; (b) goat or sheep antirabbit IgG antiserum diluted 1:10; (c) peroxidase/antiperoxidase complex diluted 1:10 or 1:50. The horseradish peroxidase was identified by incubating the grids for three minutes in 0.05 M tris buffer (pH 7.6) containing 12 mg/dl 3,3'-diamino benzidine tetrahydrochloride (Sigma), and freshly prepared 0.0025% hydrogen peroxide. The grids were washed in distilled water and floated on drops of 4% osmium tetroxide for 20 minutes to increase the electron density of the peroxidase reaction product. They were then washed thoroughly in distilled water, dried, and examined by transmission electron microscopy without any further counter-staining. Each experiment was controlled by substituting normal rabbit serum for the rabbit anti-human lactoferrin antiserum and separately by substituting normal goat or sheep serum for the goat or sheep anti-rabbit IgG antiserum.

Glycoproteins were demonstrated with a periodic acid-chromic acid-silver methenamine sequence,⁷ applied to ultrathin Epon sections supported on nickel grids. After preliminary experiments this method was preferred to Thiéry's periodic acid-thiocarbohydrazide-silver proteininate technique.⁸ Preliminary experiments also confirmed the value of a chromic acid step between periodic acid oxidation and silver staining.⁹ The periodic acid-chromic acid-silver methenamine method was also applied to paraffin sections of complete bronchial rings and compared to serial sections stained with haematoxylin and eosin and by the periodic acid-Schiff method.

Phosphotungstic acid staining was performed on ultrathin Epon sections of non-osmicated tissues, applying a 1% aqueous solution (pH 1.5) for five minutes.

Results

Serous and mucous cells were distinguished quite easily, particularly from the appearance of their secretory granules. Heavy metal staining of doubly fixed tissues showed that the serous cell granules were small, electron-dense, and discrete, whereas the mucous cell granules were large, electron-lucent, and frequently fused together (fig 1). Cells usually contained granules of one type only, but in two patients, including the one with bron-

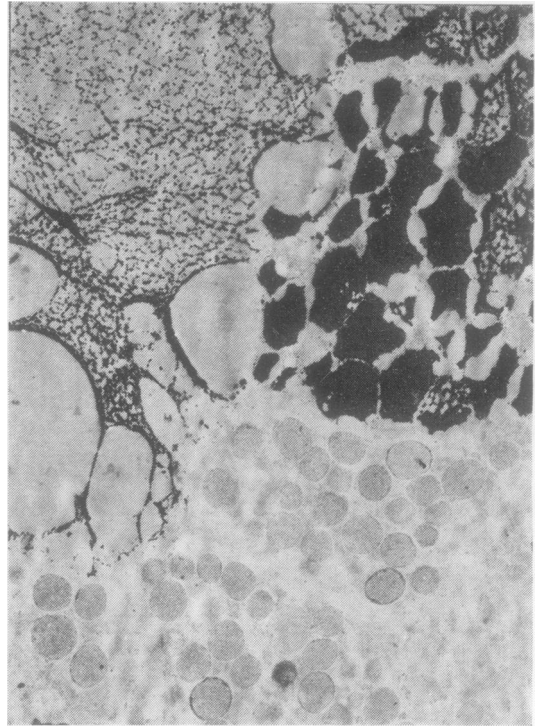


Fig 7 Mucous granules (above) always stain heavily for glycoprotein. Serous granules (below) are unstained in this area. Periodic acid-chromic acid-silver methenamine $\times 4500$.

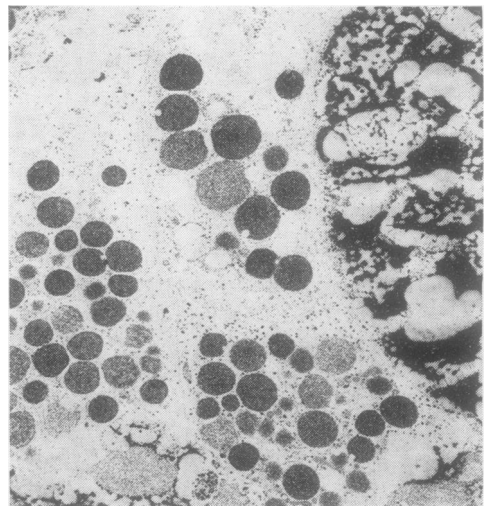


Fig 8 Here both mucous (right) and serous (left) granules contain glycoprotein. The serous granules are uniform in their reaction. Periodic acid-chromic acid-silver methenamine $\times 7800$.

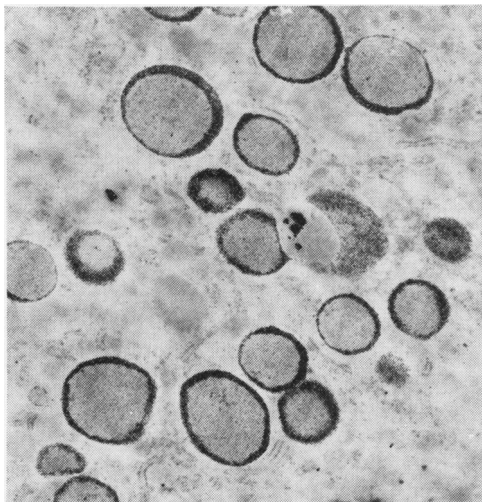


Fig 9 In some serous granules glycoprotein is limited to a thin peripheral rim. Periodic acid-chromic acid-silver methenamine $\times 12\,500$.

chiectasis, occasional cells contained both types of granule (fig 2). The secretory granules were usually homogeneous but some serous granules showed a zonal difference in their electron density, with a thin peripheral rim or a small central core being particularly electron-dense (figs 3 and 4). In non-osmicated tissues stained with uranium and lead salts the central cores and the peripheral rims contrasted markedly, the former being moderately electron-dense and the latter completely electron-lucent (fig 5).

No lactoferrin was detected in the mucous cells while the serous cell granules stained variably for lactoferrin. Some serous granules failed to stain for lactoferrin, some stained uniformly, and some showed a non-uniform pattern, lactoferrin being present in the bulk of the granules, but not in a small central core or a thin peripheral rim (fig 6). Control sections were negative.

In the glycoprotein localisation procedure, the use of chromic acid⁹ and the substitution of silver methenamine for Thiéry's silver proteinate⁸ were adopted because, at the fine structural level, there was less "non-specific" staining of the cytoplasm. However, comparison with the periodic acid-

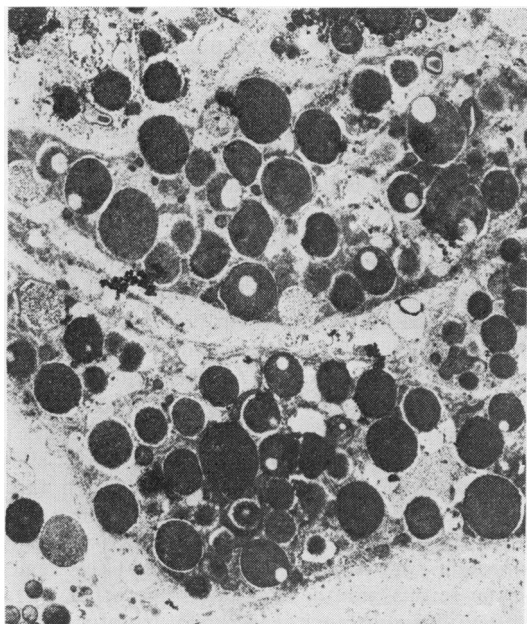


Fig 10 Some serous granules stain uniformly for glycoprotein while others have a non-reactive central core. Periodic acid-chromic acid-silver methenamine $\times 6200$.

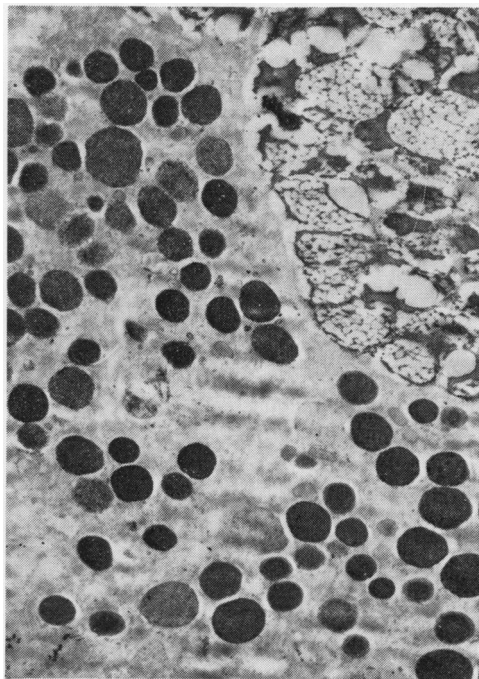


Fig 11 Phosphotungstic acid stains both mucous (upper right) and serous granules, the latter here staining uniformly $\times 4700$.

Schiff stain, using serial paraffin sections, showed that the improved "specificity" was only gained at the expense of diminished sensitivity. Whereas the Schiff method stained both mucous and serous acini of the glands and goblet cells of the surface epithelium, staining with the silver methenamine method was virtually confined to mucous acini. Despite this some staining of serous granules was detected at the ultrastructural level: here mucous cell granules always stained heavily while serous granules varied in their reaction. Many serous granules failed to stain, some stained uniformly while others showed a zonal variation in their staining. Staining confined to the peripheral rim was frequently observed and occasionally all but a small central core was stained (figs 7–10). Phosphotungstic acid stained all mucous granules but only certain serous granules, which stained either uniformly or only at the periphery (figs 11 and 12).

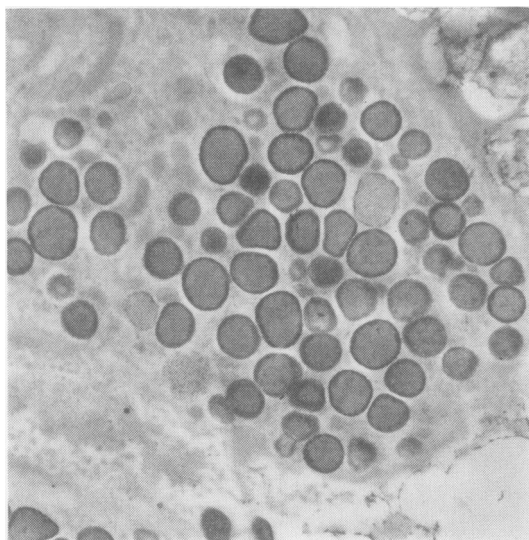


Fig 12 Some serous granules show a non-uniform pattern of staining with phosphotungstic acid $\times 6500$.

Discussion

Our observations on the morphology of serous and mucous cells conform to previous descriptions of human bronchial glands,^{1 10} with the exception of the cells which contained both types of granule. These probably represent a metaplastic change as our material derived from patients with smoking-associated tumours or bronchiectasis, in whom an increase in mucous cells is to be expected.

While the lactoferrin localisation technique has the specificity of an immune reaction, the chemical basis of the glycoprotein localisation techniques is less firmly established. We assumed initially that the periodic acid-chromic acid-silver methenamine method was comparable to the periodic acid-Schiff stain of light microscopy, and therefore stained all compounds containing hexose sugars rich in vicinal glycol groups. Comparison of these two methods at the light microscopic level showed, however, that the silver method was more selective, presumably staining a narrower range of glycoproteins. The significance of phosphotungstic acid staining is even more controversial: some claim that it stains basic proteins, such as lysozyme, while others claim that it stains glycoprotein. These differences can probably be explained by variations in technique. Thus when mixed with solutions of basic proteins or when applied to tissue blocks, there appears to be an ionic precipitation of the protein. But when applied to sections of resin embedded tissues, low pH aqueous solutions of phosphotungstic acid appear to form a complex with highly polymerised carbohydrates.⁷ The method we used corresponds to the latter technique and the results obtained match well with the distribution of glycoproteins demonstrated by the periodic acid-chromic acid-silver methenamine sequence.

The main purpose of the present study was to compare the distribution of lactoferrin and glycoprotein in human bronchial glands with that of lysozyme, which we investigated earlier.¹ The distribution of lactoferrin corresponds with that of lysozyme and it is likely that these two substances are intimately related within the secretory granule. Lactoferrin and lysozyme are confined to the serous cells whereas glycoprotein is found in both the mucous and serous cell granules. All mucous granules contain glycoprotein but the distribution of glycoprotein, lactoferrin, and lysozyme in the serous granules is uneven. All these substances fill some serous granules uniformly yet each may be completely absent from others. Serous granules in which there is non-uniform distribution show zonal differences in the distribution of all three substances. Thus the small electron-dense core failed to react for lysozyme, lactoferrin, or glycoprotein, and it may be assumed that this region of the serous granule contains some other so far unidentified substance. Lysozyme, lactoferrin, and glycoprotein differ in regard to their distribution at the periphery of the non-uniform serous granules; it is now evident that this zone contains glycoprotein and is devoid of lysozyme and lacto-

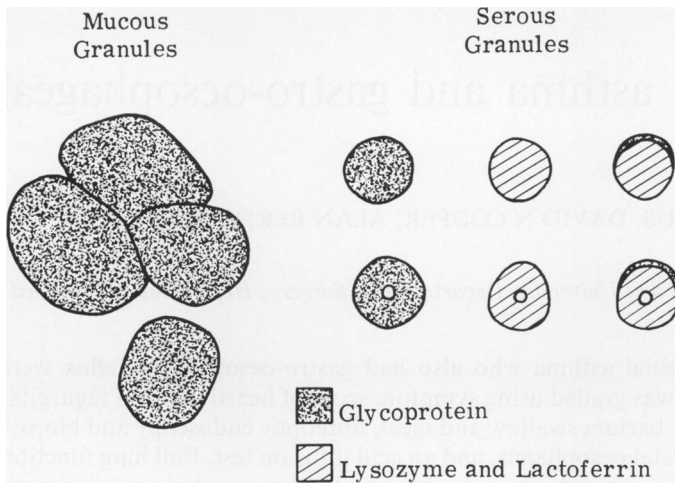


Fig 13 Diagram of the distribution of glycoprotein lactoferrin and lysozyme in mucous and serous granules. Whereas mucous granules have only been shown to contain glycoprotein, serous granules are more complex: some serous granules contain only glycoprotein while others contain only lactoferrin and lysozyme; some consist largely of lactoferrin and lysozyme but have a thin peripheral rim of glycoprotein; some have a central core of unknown content.

ferrin. With regard to the serous granules of uniform aspect, we now know that some of these contain lysozyme, some contain lactoferrin and some glycoprotein. The similar distribution of lysozyme and lactoferrin suggests that these substances are present within the same secretory granules. We cannot be certain that lysozyme and lactoferrin, on the one hand, and glycoprotein on the other, are mutually exclusive but the contrasting patterns seen in the mucous granules and the peripheral crescents of non-uniform serous granules suggest that this is likely. Thus we would suggest the following (fig 13): (1) mucous granules contain glycoprotein but not lysozyme or lactoferrin; (2) some homogeneous serous granules contain glycoprotein while others contain lysozyme and lactoferrin; (3) serous granules with a peripheral crescent contain centrally located lysozyme and lactoferrin with a thin outer coat of glycoprotein; (4) serous granules with a central core contain either lysozyme and lactoferrin or glycoprotein except for the central core which contains none of these substances.

References

- 1 Bowes D, Corrin B. Ultrastructural immunocytochemical localisation of lysozyme in human bronchial glands. *Thorax* 1977; **32**:163-70.
- 2 McCarthy C, Reid L. Intracellular mucopolysaccharides in the normal human bronchial tree. *Q J Exper Physiol* 1964; **49**:85-94.
- 3 Masson PL, Heremans JE, Prignot JJ, Wauters G. Immunohistochemical localization and bacteriostatic properties of an iron-binding protein from bronchial mucus. *Thorax* 1966; **21**:538-44.
- 4 Klockars M, Reitamo S. Tissue distribution of lysozyme in man. *J Histochem Cytochem* 1975; **23**:932-40.
- 5 Mason DY, Taylor CR. The distribution of muramidase (lysozyme) in human tissues. *J Clin Pathol* 1975; **28**:124-32.
- 6 Erlandsen SL, Parsons JA, Taylor TD. Ultrastructural immunocytochemical localization of lysozyme in the Paneth cells of man. *J Histochem Cytochem* 1974; **22**:401-13.
- 7 Hayat MA. *Positive staining for electron microscopy*. New York: van Nostrand-Rheinhold, 1975.
- 8 Thiéry J-P. Mise en évidence des polysaccharides sur coupes fines en microscopie électronique. *J Microscopie* 1967; **6**:987-1017.
- 9 Mowry RW. Effect of periodic acid used prior to chromic acid on the staining of polysaccharides by Gomori's methenamine silver. *J Histochem Cytochem* 1959; **7**:288-9.
- 10 Meyrick B, Reid L. Ultrastructure of cells in the human bronchial submucosal glands. *J Anatomy* 1970; **107**:281-99.