

Diffuse fibrosing alveolitis (diffuse interstitial fibrosis of the lungs)

Correlation of histology at biopsy with prognosis

J. G. SCADDING AND K. F. W. HINSON

From the Institute of Diseases of the Chest, Brompton Hospital, London

'Fibrosing alveolitis' refers to a broad general category of disease characterized by an inflammatory process in the lung beyond the terminal bronchiole having as its essential features (1) cellular thickening of the alveolar walls with a strong tendency to fibrosis, and (2) the presence of large mononuclear cells, presumably of alveolar origin, within the alveolar spaces. Sixteen cases in which lung biopsies conformed to this general pattern and whose course is known thereafter for at least two years or until death have been reviewed. There was an inverse relationship between the degree of alveolar wall thickening and the number of large mononuclear cells of granular type in the alveolar spaces. Corticosteroid treatment suppressed symptoms and signs in a few of the patients whose biopsy specimens showed only slight alveolar wall thickening and many intra-alveolar mononuclear cells but in none of those with much thickened alveolar walls. More or less prolonged remissions of progression of the disease were observed in a few patients, both with and without prominent alveolar wall thickening. There was no evident relationship between the histology at the time of biopsy and the total duration of the disease from onset to death.

The disease, which is generally called acute or chronic diffuse interstitial fibrosis of the lungs, and to which a variety of other names, such as chronic interstitial pneumonia or pneumonitis and Hamman-Rich disease or syndrome have also been applied, has been the subject of several extensive reviews (*e.g.*, Grant, Hillis, and Davidson, 1956; Rubin and Lubliner, 1957; Scadding, 1960; Livingstone, Lewis, Reid, and Jefferson, 1964; Stack, Grant, Irvine, and Moffat, 1965). One of us has suggested that it might be appropriate and convenient to adopt the generic name 'fibrosing alveolitis' for this disease (Scadding, 1964). Gough (1964) accepted this suggestion but wished to retain the adjective 'diffuse', which we agree is appropriate. Fibrosing alveolitis may be defined as a disease characterized by an inflammatory process in the lung beyond the terminal bronchiole having as its essential features (1) cellular thickening of the alveolar walls showing a tendency to fibrosis, and (2) the presence of large mononuclear cells, presumably of alveolar origin, within the alveolar spaces. The word 'inflammatory' is used in the broad sense, which admits such diseases of unknown aetiology as

rheumatoid arthritis into the category of chronic inflammations. The two essential features of fibrosing alveolitis are present in varying proportion in different cases, and probably at different stages of the same case. There may be other features, such as other forms of cellular exudate, fibrinous exudate, and hyaline membrane formation in the more acute cases; hyperplasia of lymphoid follicles; and, in the more chronic ones, varying degrees of fibrotic destruction of lung structure leading to such anatomical changes as honeycombing, apparent or real excess of smooth muscle, and hyperplasia of bronchiolar epithelium to line residual air spaces. The term 'fibrosing alveolitis', however, is intended to refer to a broad general category of which only two defining features—thickening of the alveolar walls and mononuclear cells within the alveoli—are essential characteristics. It is, of course, possible that subgroups will be defined within this broad category. The most useful type of grouping would be an aetiological one; but though some investigation, *e.g.*, into auto-immune factors, has been undertaken, no practical advance in this direction has yet been made. Classification on histological

criteria would be useful if it provided clues to aetiology, or if it could be correlated with prognosis or response to treatment in such a way that it permitted forecasts that could not be deduced from other data.

Liebow, Steer, and Billingsley (1965) have recently described a group of cases which they differentiated from 'other forms of interstitial pneumonia' on histological grounds, and to which they applied the name 'desquamative interstitial pneumonia' (DIP). They characterized this group by the possession of the following histological features: (1) masses of large alveolar cells, thought to be granular pneumocytes, both filling the alveoli and lining them; (2) prominence of lymphoid follicles in the periphery of the lung; (3) absence of necrosis, hyaline membranes or fibrin exudation; (4) relatively slight thickening of the alveoli; and (5) uniformity of the lesion. Radiologically, most of their cases showed opacities of even density at the periphery of the bases of the lungs rather than widespread mottled or irregular opacities. Clinically, they tended to show a good response to corticosteroid treatment, sometimes with clinical and radiological remission. Liebow and his colleagues contrasted these with the features of the 'usual forms of interstitial pneumonia', which they described as showing a varied histological picture, with more focal fibrosis, proliferation of smooth muscle, and loss of alveolar tissue, leading to honeycombing, irregular and widespread radiographic opacities, and a poor response to corticosteroid treatment. They recognized that DIP might progress to a similar end result but implied the opinion that, since it was so different in prognosis, it was probably different also in pathogenesis.

It is perhaps not surprising that a group of cases selected on the histological criteria adopted for DIP had a better prognosis than that of a histologically more heterogeneous group of 'interstitial pneumonia', since these criteria included the absence of important fibrosis. Since both it and 'other forms of interstitial pneumonia' are of equally obscure aetiology, there is at present no method by which speculations about whether they are different in pathogenesis can be tested.

The usefulness of separating out this sub-group depends in part upon the precision with which it can be distinguished and in part upon how close is the correlation with prognosis. To study these points, we have reviewed 17 cases which we had placed in the category of fibrosing alveolitis after open lung biopsy, and in which the subsequent course is known to us for at least two years or

until death, and we have examined the correlations between histological features, singly and in various combinations, and prognosis. One of the biopsy specimens reviewed showed far advanced fibrotic changes with honeycombing, but no cells were present in the remaining air-spaces. Although we believe that at an earlier stage this case would have shown the characteristic intra-alveolar cells, it did not at the time of biopsy conform to the criteria of fibrosing alveolitis suggested above, and it is excluded from the main analysis, which therefore concerns 16 cases. We shall, however, refer to this seventeenth case in the discussion.

MATERIAL

The ages of the 16 patients at the time of biopsy ranged from 12 to 63 years (mean 45 years); nine were male and seven female. All had the characteristic clinical picture of progressive dyspnoea on exertion, accompanied in most by cough, either dry or with scanty mucoid sputum. Clubbing of the fingers was present at the time of biopsy in 10 patients. In all, the characteristic pattern of disordered function, consisting in a restrictive ventilatory defect with evidence of defective gas transfer, was present, though the degree of disability varied greatly.

The biopsies were performed by thoracotomy at intervals varying from six weeks to several years from the onset of symptoms. It was difficult to be certain of the duration in several of the longer-standing cases, because of the very insidious appearance of the symptoms and the uncertainty of some of the patients' memories about the earlier part of their illnesses. The history given by one suggested that the dyspnoea, which was his chief symptom, had been developing for 13 years. In one, there was radiological evidence that the lungs had been abnormal for eight years. The biopsies were performed by several surgeons, so that the sites from which they were taken varied. Generally, an evidently affected part of the lung conveniently accessible through a small lateral thoracotomy was chosen.

PROCEDURE

The biopsy sections of these patients were reviewed by one of us (K. F. W. H.) with special reference to the factors described by Liebow and others (1965) as characteristic of 'desquamative interstitial pneumonia'. One of these features was the absence of necrosis, hyaline membranes, or fibrin exudation; changes of this sort were found in none of our cases. This left four features for assessment: (a) degree of thickening of the alveolar walls; (b) uniformity of the changes; (c) large granular alveolar cells; and (d) lymphoid

TABLE I

HISTOLOGICAL FEATURES IN LUNG BIOPSY SPECIMENS FROM 16 CASES OF FIBROSING ALVEOLITIS

Patient	Sex	Age at Time of Biopsy (yrs)	Duration of Symptoms at Biopsy	Clubbing	Cells in Alveoli			Lymphoid Follicle Excess	Alveolar Wall Thickening	Uniformity of Changes
					Large Mononuclear		Other			
					Granular	Phagocytic				
L.W.	F	12	6 weeks	0	+	0	0	+	Slight	+
D.B.	M	27	2 years	+	+	(+)	0	+	Slight	+
E.C.	F	42	1 year	+	+	(+)	0	+	Slight	+
B.S.	M	27	3 months	+	+	0	0	0	Slight	+
H.N.	F	52	2 years	0	+	+	(N)	0	Slight	+
D.B.-C.	M	56	1½ years	0	0	+	LEP	+	Slight	+
J.K.	M	39	5 years	+	(+)	+	0	0	Slight	+
M.K.	F	50	3 months	+	0	+	0	0	Slight	+
S.McK.	M	38	3 years	+	0	(+)	0	0	Prominent	+
E.F.	F	41	1 year	0	(+)	+	0	+	Prominent	0
S.M.	M	44	8 years	+	0	+	0	+	Prominent	0
D.F.	F	63	2 years	0	0	+	0	+	Prominent	0
E.L.	F	57	1½ years	+	+	0	(E)	0	Prominent	0
H.B.	M	50	5 years	+	0	+	0	0	Prominent	0
H.E.	M	53	3 years	0	0	+	NE	0	Prominent	0
J.C.	M	56	13 years	+	(+)	+	(E)	0	Prominent	0

The cases are grouped according to the number of the following four features which they showed: predominance of granular pneumocyte in alveoli, excess of lymphoid follicles, slightness of alveolar wall thickening, and uniformity of the changes. From above downwards, the Table includes three cases with all four 'features', three with three, two with two, five with one, and three with none.

+ = present. (+) = present in small numbers. 0 = absent. N = neutrophil. E = eosinophil. L = lymphocyte. P = plasma cell.

follicles in the periphery of the lung. This assessment was made without knowledge of the clinical course. Data concerning the clinical course were collected by the other of us (J.G.S.), without knowledge of the detailed histological findings. The histological and clinical data were then correlated.

FINDINGS

Table 1 summarizes the histological features. A decision about the relative prominence of these was a matter of judgement and in some cases was eventually somewhat arbitrary. The assessment of thickening of the alveolar walls into two broad groups, 'prominent' and 'slight', was in general not difficult in spite of its potentially arbitrary nature. Even in those in which thickening was least, there was some increase in connective tissue. Slightness of alveolar wall thickening correlated remarkably with the uniformity of the lesion, all those classified as showing little alveolar wall thickening showing uniform appearances, as compared with only one of those with marked alveolar wall thickening. It must be remembered that 'uniformity' could apply only to the extent of a limited biopsy specimen. As would be expected, uniformity of the changes and slightness of alveolar wall thickening correlated inversely with destructive changes leading to disorganiza-

tion of the architecture of the distal part of the broncho-pulmonary tree and consequent 'honeycombing'. Classification of the large mononuclear cells within the alveolar spaces into granular and phagocytic types was difficult. The most useful characteristics distinguishing the granular from the phagocytic type were the more deeply eosinophilic cytoplasm and the presence of sharp cell boundaries separating them when they were aggregated into masses. In many instances cells of both types were present. If granular cells were the more numerous of the large mononuclear types, the feature 'large granular alveolar cells' was regarded as being present. In a few cases other cell types were present in the alveoli, as noted in Table I. A decision about the number of lymphoid follicles was generally not difficult.

On these criteria, three cases were judged to show all of the four 'features'—slightness of alveolar wall thickening, uniformity of the lesion, prominence of large granular alveolar cells, and increase in lymphoid follicles; three showed three features; two showed two; five showed one; and three showed none. The range of histological changes is illustrated in Figures 1 to 4. Figure 1 shows many large mononuclear cells of granular type occupying alveoli with little thickening of their walls; this comes from patient D.B., with all four 'features'. Figure 2 shows hyperplasia of

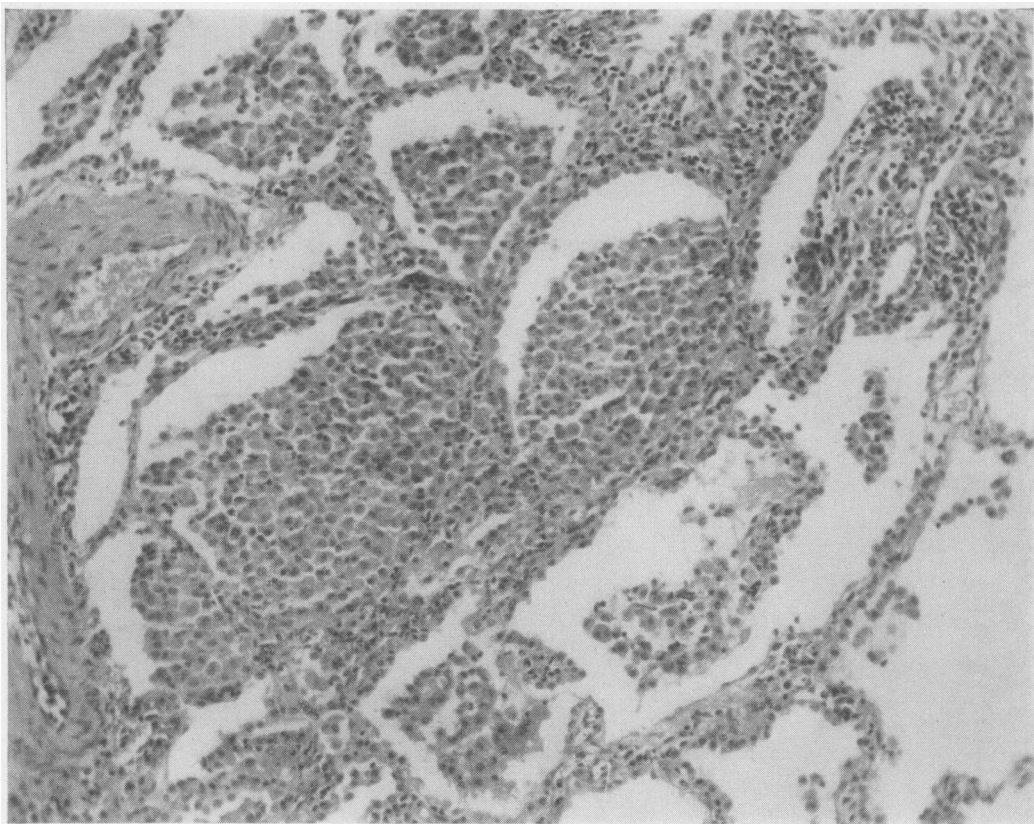


FIG. 1. Biopsy from patient D.B., showing many large mononuclear cells of granular type within the alveoli, with little thickening of the alveolar walls. H. and E. $\times 160$.

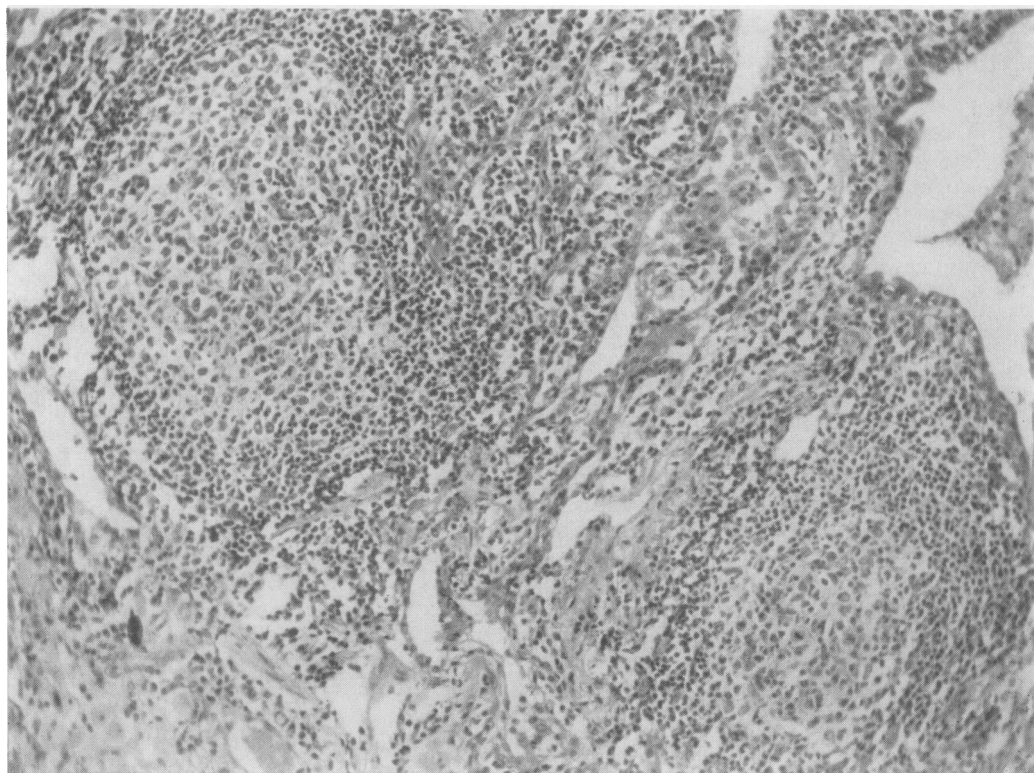


FIG. 2. Biopsy from patient D.B.-C., showing lymphoid follicle hyperplasia with germinal centres. H. and E. $\times 160$.

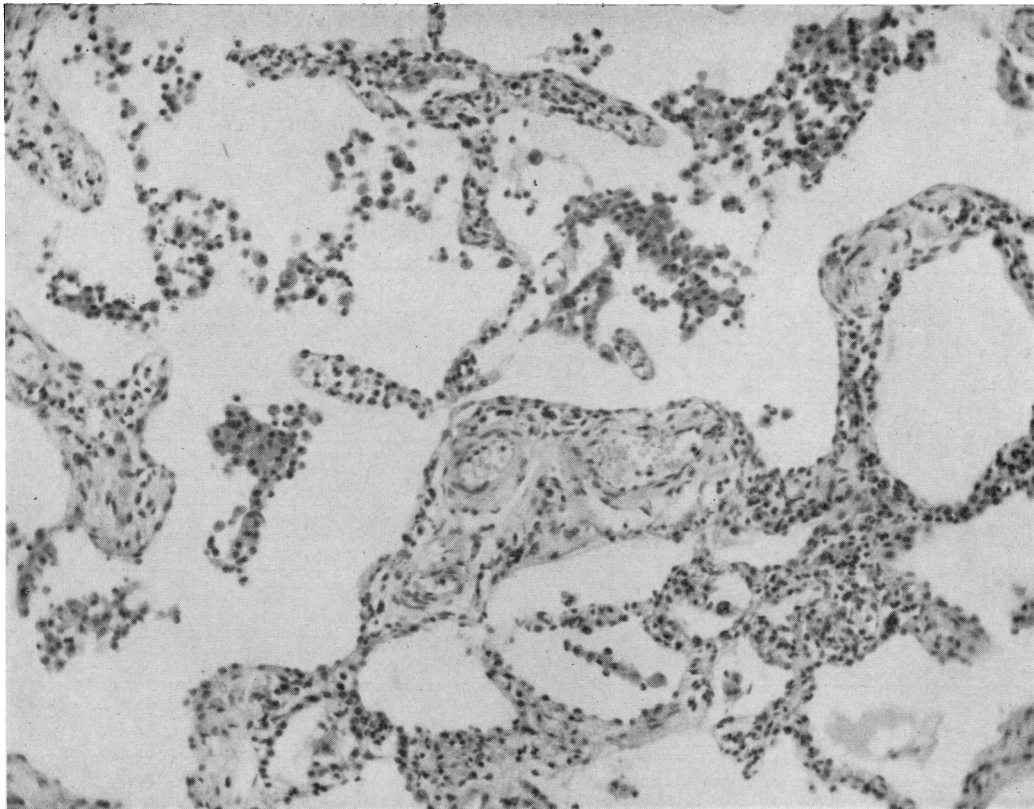


FIG. 3. Biopsy from patient *M.K.*, showing thickening of the alveolar walls, with moderate numbers of mononuclear cells, mostly phagocytic. *H. and E.* $\times 160$.

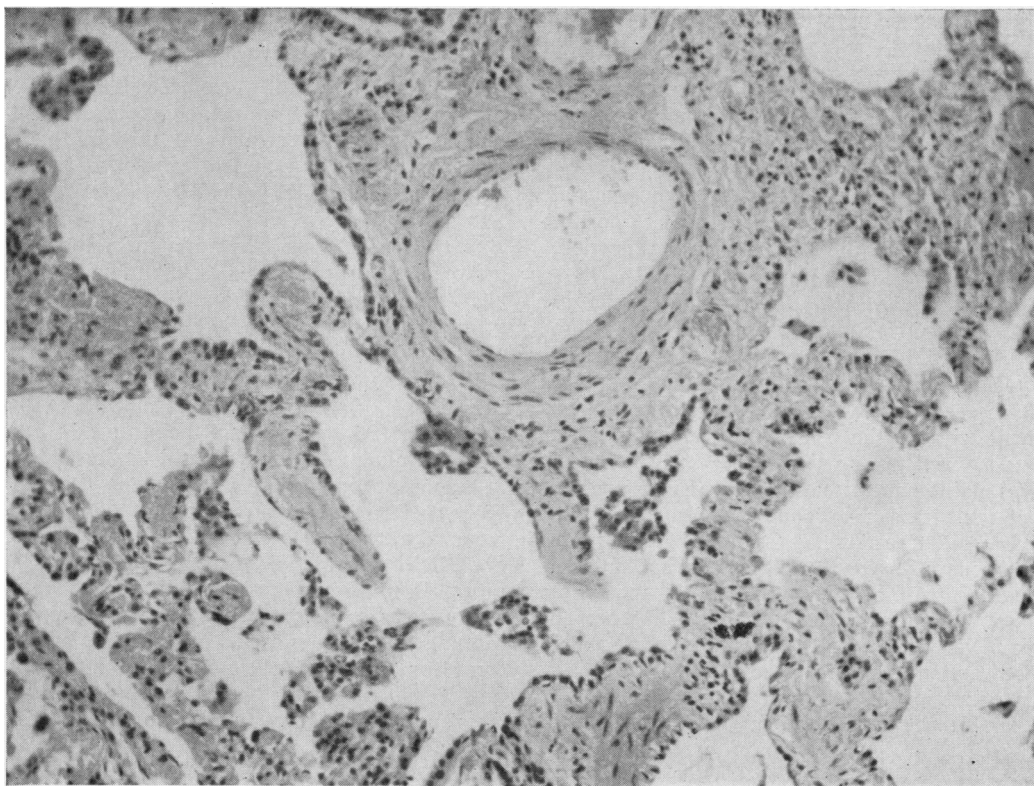


FIG. 4. Biopsy from patient *H.B.*, showing thickening of the alveolar walls with scanty mononuclear cells of phagocytic type in the alveolar spaces. *H. and E.* $\times 160$.

TABLE II

PROGRESS AFTER BIOPSY AND RESPONSE TO CORTICOSTEROID TREATMENT IN 16 PATIENTS WITH FIBROSING ALVEOLITIS

Patient	No. of 'Features' of DIP in Biopsy	Latest Known State				Response to Corticosteroid
		Surviving (no. of years)		Dead (no. of years)		
		After Onset	After Biopsy	After Onset	After Biopsy	
L.W. D.B. E.C.	4 4 4	4 5½	4 4½	9	7	Not given, spontaneously improved Equivocal, withdrawn Improvement, maintained only by continued treatment
B.S. H.N. D.B.-C.	3 3 3	8 4½ 4	7½ 2½ 2½			Improvement, maintained only by continued treatment Improvement, maintained only by continued treatment Slight improvement, treatment continued
J.K. M.K.	2 2	10 8½	5 8			No improvement, withdrawn Slight improvement, withdrawn; later spontaneous improvement
S.McK. E.F.	1 1	10	9	3½	½	No improvement Slight improvement, withdrawn; later spontaneous improvement
S.M. D.F. E.L.	1 1 1	17	9	5 10½	3 9	Slight improvement, treatment continued Equivocal Not given
H.B. H.E. J.C.	0 0 0	16 13	11 10	14½	13	No improvement, withdrawn No improvement, withdrawn No improvement, withdrawn

The upper half of the Table shows eight cases with only slight and the lower half eight with prominent alveolar wall thickening at the time of biopsy.

lymphoid follicles, with germinal centres, from a patient (D. B.-C.) with three 'features'. Figure 3 shows thickening of the alveolar walls and a moderate number of cells, mostly phagocytic, within the alveoli, in a patient (M. K.) with two 'features'. Figure 4 shows thickening of the alveolar walls with a few phagocytic cells within the alveoli in a patient (H. B.) with none of the 'features' of DIP.

Table II summarizes the latest known state of these 16 patients and the responses to corticosteroid treatment in the 14 in whom it was tried.

Correlation between histological changes at biopsy and course Of the three patients with all the 'features' of DIP, one has progressed outstandingly well, attaining apparent arrest of progression of the disease with only moderate functional impairment without the use of corticosteroids; one responded well to corticosteroid treatment but requires maintenance treatment to prevent progression of the disease; and one has died in spite of corticosteroid treatment. Clearly, it is not possible to generalize from these discordant findings. However, it will be observed that in the whole group of 16 patients two features, slightness of alveolar wall thickening and uniformity of the lesion, were more closely associated than any others, occurring in all the patients who had two, three, or four features; and a glance at Table II

shows that the eight cases in the upper part of the Table with only slight alveolar wall thickening certainly included a larger number with an evident response to corticosteroid treatment. For this reason, the 16 cases have been divided into those with only slight alveolar wall thickening at the time of biopsy (group I, eight cases) and those with prominent alveolar wall thickening (group II, eight cases), and these two groups have been compared (Tables III and IV).

Age and sex There was no significant difference between the groups in sex distribution, four of the eight patients in group I and three of the eight in group II being women. The patients in whom alveolar wall thickening was not prominent (group I) were younger both at the time of apparent onset (mean age 36 years) and at the time of biopsy (mean age 38 years) than the group II patients with prominent alveolar wall thickening (45½ years at apparent onset and 50 years at the time of biopsy). These differences are not significant. The mean duration of symptoms before biopsy was considerably less (1.5 years) in group I than in group II (4.6 years); the difference between the two groups is significant at the 5% level in a ranking test. Three group I patients had had symptoms for less than one year, as compared with one in group II. On the other hand, one patient in group I had had symptoms for five years.

TABLE III

COURSE OF 16 CASES OF FIBROSING ALVEOLITIS AND APPARENT RESPONSES TO CORTICOSTEROID TREATMENT IN RELATION TO DEGREE OF ALVEOLAR WALL THICKENING AT TIME OF BIOPSY

	Alveolar Wall Thickening	
	Not Prominent (Group I)	Prominent (Group II)
No. of cases	8	8
Mean age at apparent onset ..	36 yrs	45.5 yrs
at time of biopsy ..	38 yrs	50 yrs
Mean duration before biopsy ..	1.5 yrs	4.6 yrs
Patients who have died		
No.	1	4
Mean duration: total	9.5 yrs	8.4 yrs
after biopsy	7 yrs	6.4 yrs
Patients surviving at time of review		
No.	7	4
Mean duration to date of last observation: total	6.4 yrs	14.0 yrs
after biopsy	5.0 yrs	9.8 yrs
Apparent responses to corticosteroid treatment		
None or doubtful		
Corticosteroid withdrawn ..	3 (1†)	3 (1†)
Corticosteroid continued ..		3 (2†)
Corticosteroid withdrawn, later spontaneous improvement	1	1
Improvement, maintained by continued treatment	3	
Not given	1	1†

(†) number of deaths

TABLE IV

CLINICAL, FUNCTIONAL, AND RADIOGRAPHIC FINDINGS AT TIME OF BIOPSY IN 16 CASES OF FIBROSING ALVEOLITIS, RELATED TO DEGREE OF ALVEOLAR WALL THICKENING

	Group I	Group II
Total no. of patients	8	8
Clinical findings		
Persistent crepitations	6	7
Clubbing of fingers	5	5
Functional disturbance		
Ventilatory capacity		
Normal	1	
Obstructive defect	1	
Restrictive defect		
Slight	1	4
Moderate	2	3
Severe	2	1
Not tested	1	
CO transfer factor		
Slightly reduced	4	2
Reduced	2	1
Much reduced	1	4
Not tested	1	1
Radiographic appearances		
Normal	1	
Patchy consolidation + widespread mottling	3	
Basal shadows	4	2
Widespread mottling		6

Clinical, functional, and radiographic features

The clinical, functional, and radiographic features of the two groups are summarized in Table IV. Clinically, apart from the differing duration of symptoms, there was little systematic difference between the two groups. The most important symptom was dyspnoea on exertion. Clubbing was observed in 10 patients, five in group I and five in group II. The most frequent physical sign was the presence of persistent crepitations usually confined to the bases of the lungs even in patients in whom the radiographic changes were extensive; they were detected when the patients were first seen in six of the eight group I and in seven of the eight group II cases.

In both groups, tests of respiratory function showed varying combinations of restricted ventilation without airways obstruction and impaired gas transfer. Spirometry and CO transfer factor estimations by the steady-state method were performed in all but one patient in group I, in whom no pre-treatment tests were recorded, and one in group II, in whom only ventilatory tests were performed. In group I two showed severe, two moderate, and one slight restrictive ventilatory defects; one showed no ventilatory defect; and one showed a moderate obstructive defect, probably associated with incidental chronic bronchitis in a heavy cigarette smoker. In the CO transfer factor tests, one showed severe, two moderate, and four slight defects. In group II, one showed severe, three moderate, and four slight restrictive ventilatory defects; and four severe, one moderate, and two slight defects of gas transfer. Thus, although there was little difference between the two groups in severity of restrictive ventilatory defect, half the patients in each showing moderate or severe defects, a higher proportion of patients in group II showed severe defects of gas transfer. Possibly this can be correlated with the greater degree of disorganization of the peripheral gas-exchanging part of the lungs in this group leading to wider variations in alveolar ventilation-perfusion ratios.

The chest radiographs at the time of biopsy presented a wide range of appearances in both groups (Table IV). These are discussed below.

Deaths One patient in group I has died, 9.5 years from the onset of symptoms. Four patients in group II have died, the mean duration of illness being 8.4 years. It is difficult to draw any conclusion from these observations, since the mean duration of observation of surviving patients after

biopsy was considerably less in group I (5 years) than in group II (9.8 years).

Necropsies were performed in the group I case and in one of those in group II. In the group I case (patient D.B.), a definite increase in the fibrotic changes in the alveolar walls in the sub-pleural regions was observed. The former uniformity had been disrupted by destructive changes. Lymphoid follicles were still prominent. There was a striking reduction in the number of cells within the alveolar spaces, many of which were empty. The cells were of both phagocytic and granular types. The histology at this stage thus showed only one of the 'features' of DIP. In the group II case (patient S. McK.), the only 'feature' of DIP which had been observed in the biopsy specimen was uniformity of the changes; in the necropsy, this uniformity was no longer evident, severe fibrotic changes being patchily distributed.

Remission of progression Remission of progression of disease is here defined as non-progression of the disease for at least one year without continued corticosteroid treatment and with disability no greater than is compatible with leading a normal life. Three patients in group I and two in group II have attained this state.

Response to corticosteroid treatment Seven patients in group I and seven in group II received corticosteroid treatment, in the form of prednisolone by mouth. The usual policy was to start with a moderate dose, of the order of 20 mg. daily. If there was no response this was increased to a higher level. All those patients who responded did so to a daily dose of 30 mg. or less. Among those who did not respond and whose symptoms were thought severe enough to justify higher doses, one showed no response to doses as large as 40 mg. daily for one year, but eventually attained remission of progression, and one, who eventually died, failed to respond to 60 mg. daily.

In group I, four showed little or no response and the prednisolone was withdrawn without ill effect; in one of these, spontaneous improvement started several months later, and this patient was known to be well, without disability, more than eight years after the biopsy. Three improved symptomatically and radiologically and to a smaller extent in objective functional tests, but attempts to withdraw prednisolone have been followed by relapse so that improvement is maintained only by prednisolone treatment, which at the last observation had lasted 4, 2½, and 2 years. In these three cases the maintenance dose varies between 10 and 20 mg. daily.

In group II, little response to corticosteroid treatment was observed. Three patients were not improved and the treatment was withdrawn; one of these has attained remission of progression, as defined above. Three showed a doubtful response, with some symptomatic but no objective improvement, treatment being continued either because deterioration followed attempts at withdrawal or because the minor symptomatic improvement was considered worth while in a patient with a severe disability. One showed a slight response, slight deterioration on cessation of treatment after 12 months, then spontaneous improvement to a degree of functional and symptomatic improvement similar to that which she had attained during treatment: this improvement was maintained five years afterwards, and the patient was well with slight but tolerable functional disability.

Since the criterion by which groups I and II were distinguished was the degree of alveolar wall thickening, and since considerable thickening was always to a large extent fibrotic, the failure of most cases in group II to show any substantial response to corticosteroid treatment is not unexpected.

Radiographic appearances One patient in group I (J. K.) had no evident abnormality in the chest radiograph in spite of having had symptoms for five years, with moderately severe dyspnoea, a moderate reduction in CO transfer factor, great reduction in lung compliance, and severe histological changes in the lung biopsy. This patient made little response to corticosteroid treatment, which was withdrawn, but survives 10 years from the onset. Three of the 14 patients with DIP described by Liebow *et al.* (1965) had no evident radiographic abnormality.

Three of our patients, all in group I, showed combinations of irregular patchy consolidation, predominantly at the bases in two, with more widespread ill-defined mottling (Fig. 5). All these had had symptoms for relatively brief periods (three months or less) at the time of biopsy. Histologically, they all showed only slight alveolar wall thickening and uniformity of histological changes; one showed also both granular alveolar cells and excess of lymphoid follicles, one granular alveolar cells and no excess of lymphoid follicles, and the other neither of these features. All improved, one spontaneously, one during continued corticosteroid treatment, and one after the withdrawal of only partially effective corticosteroid treatment. The patient who requires continued corticosteroid treatment now shows widespread fine mottling

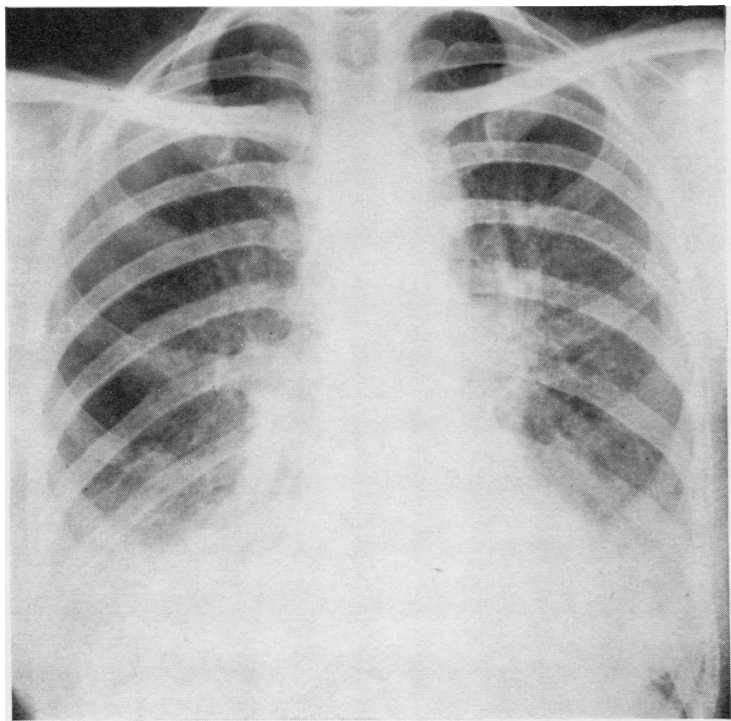


FIG. 5. Radiograph of the chest of patient M.K., showing uniform shadows above the diaphragm with light mottling in most of the left and the middle zone of the right lung.

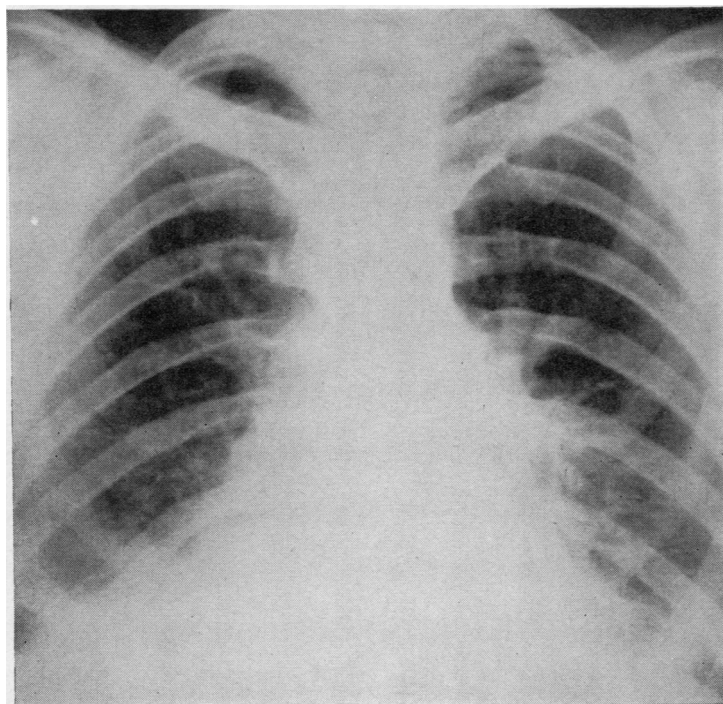


FIG. 6. Radiograph of the chest of patient D.B., showing bilateral basal opacities above a somewhat raised diaphragm.

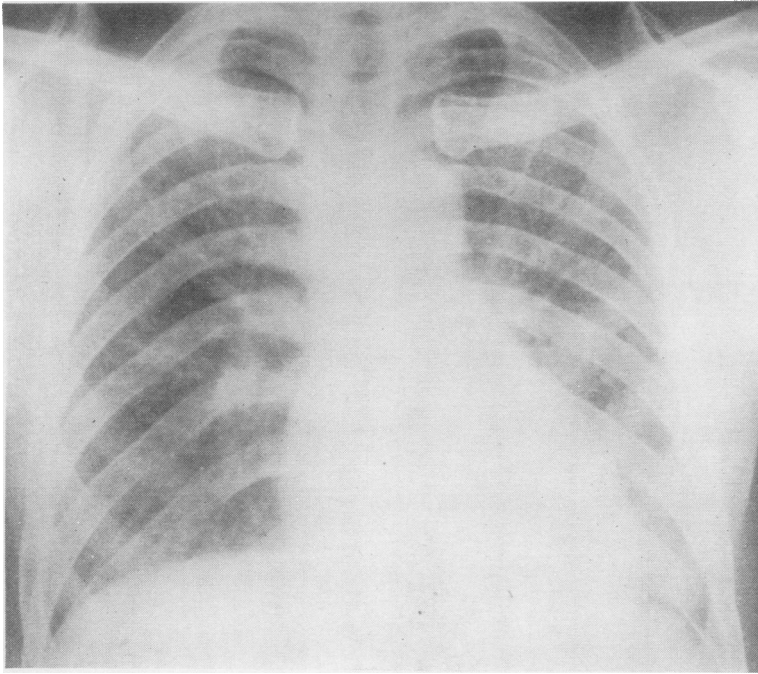


FIG. 7. Radiograph of the chest of patient S.McK., showing widespread mottling.

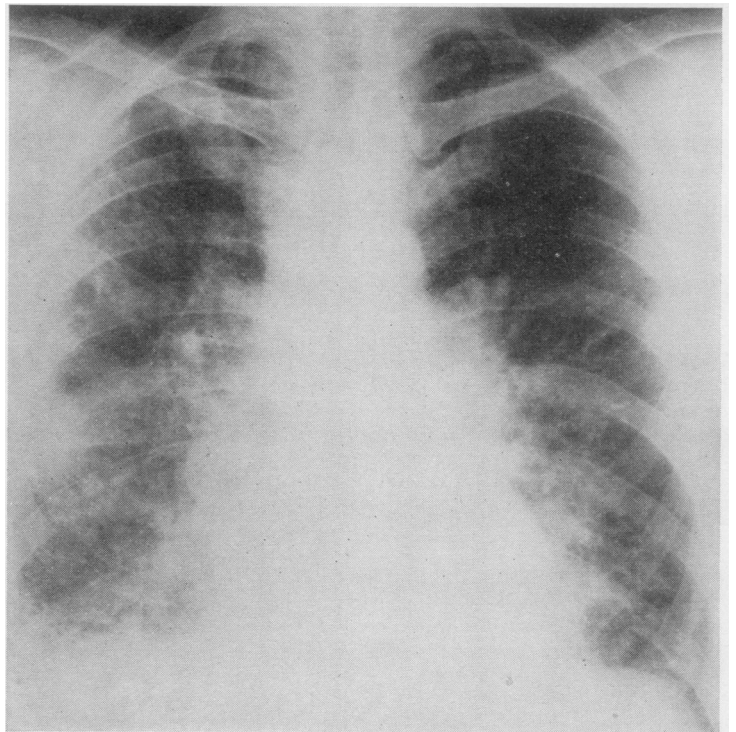


FIG. 8. Radiograph of the chest of patient S.M., showing extensive mottling with 'honeycomb' appearances. A radiograph six years earlier had shown fine generalized mottling without honeycombing.

with a fine 'honeycomb' pattern in parts of the lung fields.

Liebow *et al.* (1965) described opacities of more or less uniform density in the lower parts of the lungs, immediately above the somewhat elevated diaphragm, with ill-defined upper borders, in 10 of 14 patients with 'desquamative interstitial pneumonia'. Six of our patients showed appearances of this sort (Fig. 6), four in group I and two in group II. The duration before biopsy ranged from one to five years. Three, all in group I, responded to continued corticosteroid treatment; one in group I gradually deteriorated and died, nine years from the onset, in spite of corticosteroid treatment; one in group II improved spontaneously after corticosteroid treatment had been discontinued; and one in group II, not treated with corticosteroids, gradually developed honeycombing and died 10½ years from the onset. Thus, the response to corticosteroid treatment was not uniformly favourable, and this sort of radiographic change, while more frequent in group I patients, was not confined to them and was observed in one patient to progress to honeycombing.

The remaining six patients all belonged to group II, with prominent alveolar wall thickening. Radiographically, they showed widespread mottled opacities, in some denser at the bases but in others generalized throughout the lungs (Fig. 7). Two showed appearances suggestive of honeycombing, and one definite honeycombing at the time of biopsy (Fig. 8); the latter had shown fine generalized mottling without honeycombing in a radiograph six years earlier. The quality of the mottling in these six cases varied widely, from a uniform distribution of fine regular opacities to irregularly scattered opacities of varied size and shape. In one case, pleural thickening was evident in the costophrenic angles and was confirmed at biopsy. The duration of symptoms before biopsy was long, ranging from two to 13 years. No useful response to corticosteroid treatment was observed in any of these patients. Three have died 4, 5, and 14½ years from the onset; and three survive 11, 14, and 16 years from the onset with apparently non-progressive or only slowly progressive disability, severe in two and moderate in one.

Although there was thus a wide range of radiographic appearances in both groups, it appeared that opacities confined to the bases of the lungs and often with a rather high position of the diaphragm occurred with greater frequency in group I and were associated with the possibility

of regression of the disease, either spontaneously or under the suppressive influence of corticosteroids; and that widespread mottled shadows occurred more often in group II and were associated with changes unlikely to regress even under corticosteroid suppression. Honeycombing developed more frequently in those with widespread mottled opacities but did develop in one patient who, though histologically in group II, showed radiographic changes of the 'basal shadows' type.

Associated diseases and auto-immune factors in blood. Two patients in each group had clinical evidence of possibly associated diseases. In group I, patient D. B. developed joint pains with a rise in titre of rheumatoid factor about four years from the apparent onset of fibrosing alveolitis, but the symptoms subsided spontaneously; one year later he developed mild ulcerative colitis. Patient D. B.-C. had an obscure papular rash, showing on biopsy focal collagen degeneration with many polymorph neutrophils, and a Mooren's ulcer of the cornea, both of which disappeared promptly when corticosteroid treatment was begun for the pulmonary condition, although they had been present for more than one year and had been resistant to other forms of treatment. In group II, one patient (S. M.) had rheumatoid arthritis, the symptoms of which appeared two years after the first detection of abnormalities in the chest radiograph; and another (E. F.) had an unexplained cellular infiltration of portal tracts in a liver biopsy performed during the initial investigation and later developed Sjögren's syndrome and lymphadenoid goitre.

Eight patients among the 17 reviewed were included in the survey of auto-antibodies in sera from patients with interstitial pulmonary fibrosis by Turner-Warwick and Doniach (1965). These were equally divided between the two groups, and two of the four in each group showed significant titres in one or more of the tests. In group I, patients D. B. and D. B.-C., mentioned above, both showed Rose-Waaler differential agglutination titres (D.A.T.) of 1:64. In group II, sera from patient E. F., mentioned above, gave positive reactions for anti-nuclear factor (A.N.F.) at a dilution of 1:200, and to thyroglobulin by the tanned red-cell technique at a dilution of 1:2,500, and from patient S. McK., a positive reaction for A.N.F. at a dilution of 1:40. The patient S. M. who developed rheumatoid arthritis, as mentioned above, was not included in this survey; he gave positive Rose-Waaler tests in high titre.

There was thus no difference between the two groups in the proportions of patients with possibly associated diseases or, among those tested, with 'auto-immune' factors in the blood serum.

DISCUSSION

The cases selected for this survey all conformed to the definition of fibrosing alveolitis as a disease characterized by cellular thickening of the alveolar walls with a tendency to fibrosis and the presence of large mononuclear cells within the alveoli. Because this definition is in general terms, it permits the inclusion of a wide range of cases. In terms of the histological changes found in lung biopsy specimens, one end of this range was characterized by slightness of alveolar wall thickening and the presence of many large mononuclear cells, principally of granular type, in the alveoli; and the other by prominence of alveolar wall thickening with fewer mononuclear cells, many of phagocytic type, in the alveoli. The degree of thickening of the alveolar walls seemed to be correlated inversely with the number of mononuclear cells in the alveoli, especially those of granular type.

An extreme example of this trend was seen in one of the biopsies reviewed, the seventeenth case, which, as mentioned in the introduction, was excluded from the main analysis. This showed only alveolar wall thickening and no mononuclear cells in the alveoli; for this reason, the histology of this biopsy did not conform fully to the definition of fibrosing alveolitis, though we have no doubt that either in other parts of the same lung or at an earlier stage of the disease both essential features would have been found. Other aspects of this case resembled those of the other cases with prominent alveolar wall thickening; the patient was a woman aged 61, symptoms had been present for two years before biopsy, the changes were non-uniform, there was no lymphoid follicle excess, there was no response to corticosteroid treatment, and the patient died three years after the biopsy; there was no necropsy. Though a clinical diagnosis of fibrosing alveolitis was tenable in this case, expressing the belief that the defining characteristics would have been found if sought either at the appropriate time or in a more extensive examination than was in fact possible, the case could not be included in a study based on the histological criteria which we adopted.

Of the five features by which Liebow *et al.* (1965) distinguished 'desquamative interstitial

pneumonia', one was that necrosis, hyaline membranes or fibrin exudation should not be present. Among our cases, none showed such changes: there were thus four 'features' whose presence could be correlated with clinical, radiological, and physiological findings. Slightness of alveolar wall thickening and the presence of large mononuclear cells of granular type in the alveoli have already been noted to be correlated with each other and, to a lesser extent, with the possibility of response to corticosteroid treatment. Uniformity of the changes throughout the extent of the biopsy specimen showed almost complete correlation with the degree of alveolar wall thickening, the changes being uniform in all those in which it was only slight (group I) and in only one of the eight in which it was prominent (group II). There remains the excess of lymphoid follicles. This feature showed poor correlation with other histological features, being found in four of the eight group I and three of the eight group II cases. Lymphoid follicles were prominent in the one patient who showed early spontaneous improvement, in two of the three who showed a favourable response to corticosteroid treatment, and in one of the two who improved spontaneously after it had been discontinued. This feature was present in only two of the seven who showed no useful response to such treatment. There is thus some suggestion of a correlation between the possibility of response to corticosteroid treatment and an excess of lymphoid follicles.

There was no indication of a correlation between these histological features and duration of life after the onset of the disease or the prospect of attaining a remission of progression of the disease.

Radiographically, a wide range of patterns was seen, and there was some correlation both with histology and with the clinical course. Patchy consolidation, with ill-defined mottling of varying extent elsewhere in the lungs, was seen in three patients, all in group I, but was not correlated especially with the type of cell present in the alveoli or with excess of lymphoid follicles; in one patient, this sort of radiographic appearance has given place to widespread mottling with some honeycombing during long-continued corticosteroid treatment. More or less uniform shadows above the diaphragm, which was usually somewhat raised, were seen in four group I and two group II patients. In four of the six patients with this type of shadow, the granular type predominated among the alveolar mononuclear cells, and in four there was an excess of lymphoid

follicles; and, as noted above, half of them showed a response to corticosteroid treatment. One, who survived without corticosteroid treatment for nine years after biopsy, developed gross honeycombing of the greater part of one lung and the lower part of the other.

Six patients who showed widespread well-defined mottling all belonged to group II. Phagocytic mononuclear cells were predominant in the alveoli in all of these, and lymphoid follicles were numerous in only two. None showed a response to corticosteroid treatment; in two, the disease was uninterruptedly progressive, leading to death in less than five years, but in the other four it was much slower in progression, remaining stationary for long periods, so that three survive 13, 16, and 17 years from the onset, and one died after 10½ years. These six patients showed at least as much consistency in clinical, histological, and radiological features as, at the other end of the scale, did those selected because they showed the features upon which the description of DIP was based.

These observations in part confirm and in part conflict with those of Liebow *et al.* (1965). Among patients whose lung biopsies conformed to the wide general category of fibrosing alveolitis, those (group I) who had little alveolar wall thickening and large numbers of predominantly granular mononuclear cells in the alveolar spaces and who also, as might be expected, showed uniformity of appearances throughout the whole extent of the biopsy without destructive changes, were found to show certain differences from the rest and to resemble in some respects the cases described by Liebow *et al.* (1965) as 'desquamative interstitial pneumonia'. This group included most of the few who responded to corticosteroid treatment; radiographically none showed widespread, well-defined mottling, which was seen in most of those with prominent alveolar wall thickening, and some showed patchy consolidation which did not occur in the latter group.

On the other hand, viewing the series of 16 cases as a whole, we could not perceive a sharp distinction between a group having more or less uniform characteristics and the rest, but rather a range between cases with little alveolar wall thickening and many granular mononuclear cells in the alveoli and those with prominent alveolar wall thickening and fewer mononuclear cells, mostly phagocytic. The presence of excess of lymphoid follicles showed no correlation with the other features listed above, and doubtful correlation with radiographic appearances and with

response to corticosteroid treatment. The radiographic appearance of 'basal opacification at the periphery of the lung', regarded as typical of DIP by Liebow *et al.* (1965), was seen in only half of the group I cases and also in two of the eight group II cases; in one group I patient, who was among those whose histology most closely resembled that of DIP, the radiographic changes, at first patchy consolidations denser at the bases of the lungs, were observed to progress to widespread mottling with some honeycombing; in one patient initially showing uniform basal shadows but histologically in group II, honeycombing gradually developed; the differences between group I and group II patients in response to corticosteroid treatment were no more than might be expected from the difference in severity of alveolar wall fibrosis; and the proportions of cases in the two groups with possibly related diseases and with positive tests for a range of auto-immune factors in their blood sera were similar.

We conclude that there is an evident practical importance in recognizing the radiographic and therapeutic differences between those patients with fibrosing alveolitis showing little alveolar wall thickening and many alveolar cells, mostly granular, and those with prominent alveolar wall thickening and fewer cells, mostly phagocytic. But our study provides little support for the sharp contrast suggested by Liebow *et al.* (1965) between DIP and the 'usual forms of interstitial pneumonia' which they regard as representing 'a type of tissue response to many agents'. Viewing our series in all its aspects, we see no evidence to justify any positive statement about pathogenesis. Until more is known about the pathogenesis of this whole group of cases, it is premature to conclude that because a recognizable variant of the basic histological pattern shows some correlation with clinical and radiological features, it characterizes a pathogenetically distinct sub-group; this proposition may eventually be found to be true, but, until more is known about the pathogenesis of the whole group, it is no more than an interesting speculation. In the meantime, it seems to us useful to have available terms by which reference can be made to the variants at the two ends of the range without implication beyond histological description. Those characterized by large numbers of large mononuclear cells in the alveolar spaces and resembling the 'desquamative interstitial pneumonia' of Liebow *et al.* can be described as a desquamative type of fibrosing alveolitis. We recognize that the word 'desquamative' goes a

little beyond histological description, since it implies that the cells in the alveoli were derived from alveolar lining cells; but this seems a reasonable deduction from their morphology. The contrasting type of case, in which alveolar wall thickening is the predominant change, can be said to show a 'mural' type of fibrosing alveolitis.

We are indebted to the Professor of Child Health, Queen's University, Belfast, for permission to refer to patient L. W., and to the Professor of Pathology for the loan of histological material; and similarly to Dr. Oliver Jones and Dr. A. J. Shillitoe in relation to patient B. S.

REFERENCES

- Gough, J. (1964). Fibrosing alveolitis (correspondence). *Brit. med. J.*, **2**, 818.
- Grant, I. W. B., Hillis, B. R., and Davidson, J. (1956). Diffuse interstitial fibrosis of the lungs (Hamman-Rich syndrome). *Amer. Rev. Tuberc.*, **74**, 485.
- Liebow, A. A., Steer, A., and Billingsley, J. G. (1965). Desquamative interstitial pneumonia. *Amer. J. Med.*, **39**, 369.
- Livingstone, J. L., Lewis, J. G., Reid, L., and Jefferson, K. E. (1964). Diffuse interstitial pulmonary fibrosis: a clinical, radiological, and pathological study based on 45 patients. *Quart. J. Med.*, **33**, 71.
- Rubin, E. H., and Lubliner, R. (1957). The Hamman-Rich syndrome: review of the literature and analysis of 15 cases. *Medicine*, **36**, 397.
- Scadding, J. G. (1960). Chronic diffuse interstitial fibrosis of the lungs. *Brit. med. J.*, **1**, 443.
- (1964). Fibrosing alveolitis (correspondence). *Ibid.*, **2**, 686 and 941.
- Stack, B. H. R., Grant, I. W. B., Irvine, W. J., and Moffat, M. A. J. (1965). Idiopathic diffuse interstitial lung disease: a review of 42 cases. *Amer. Rev. resp. Dis.*, **92**, 939.
- Turner-Warwick, M., and Doniach, D. (1965). Auto-antibody studies in interstitial pulmonary fibrosis. *Brit. med. J.*, **1**, 886.