

# Pulmonary Sequestration: A 29 Patient Case Series and Review

BASHEER TASHTOUSH<sup>1</sup>, ROYA MEMARPOUR<sup>2</sup>, JOSE GONZALEZ<sup>3</sup>, JAMES BENJAMIN GLEASON<sup>4</sup>, ANAS HADEH<sup>5</sup>

## ABSTRACT

**Introduction:** Pulmonary sequestration also known as bronchopulmonary sequestration is a rare disease, with very few case series reviewed in literature. In this study, we review the demographics, presentation, imaging and treatment of pulmonary sequestration in 29 patients from our institution, and provide comparison data from previously published series with an overview of the disease history.

**Materials and Methods:** Records reviewed for all patients evaluated and treated in our institution with a pathological proven diagnosis of pulmonary sequestration from January 2004 through December 2013. Collected data included demographics, clinical presentation, diagnostic imaging, location of the lesion, type of sequestration, and subsequent treatment.

**Results:** Of the 29 patients reviewed 8 (28%) were children 0-2 years, 1 adolescent age 17, and 20 (69%) adults 21-70 years with a mean age of 42 among adults. Systemic arterial supply to the sequestered segment was demonstrated with computed tomographic angiography (CTA) in 25 patients (86%). In 19 patients (66%), the sequestered segment was located in the left lower lobe, and 16 (55%) were intralobar.

**Conclusion:** Diagnostic delays of pulmonary sequestration were common among the adult population as the presenting symptoms often mimicked other common pulmonary diseases, such as pneumonia and asthma. These findings were consistent among previously published series. CTA was the preferred imaging modality for preoperative planning with high sensitivity and specificity in identifying the lesion.

**Keywords:** Bronchopulmonary malformations, Computed tomographic angiography, Congenital lung diseases, Intralobar and extralobar sequestration

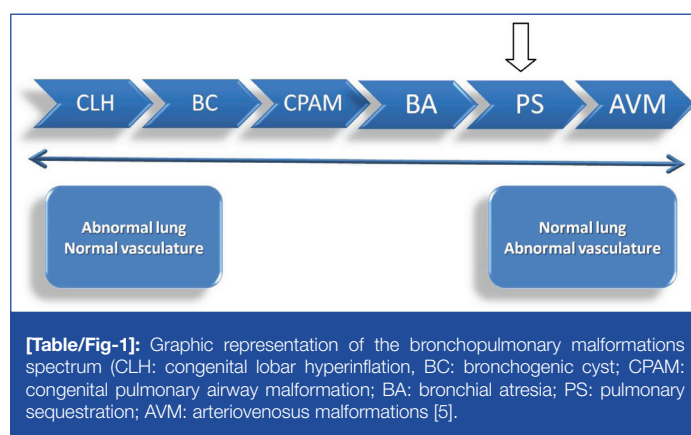
## INTRODUCTION

Pulmonary sequestration (PS) is a rare disease, of unknown aetiology, representing 0.1–6% of all structural lung diseases and developmental malformations. It is characterized by a mass of pulmonary tissue that becomes separated from the normal bronchopulmonary tree and supplied by one or more aberrant systemic arteries [1,2]. It is an entity for which no single embryonic hypothesis is clearly adapted, and no chromosomal abnormality yet identified. Many consider the disease part of an anomaly spectrum, with normal vessels supplying anomalous pulmonary tissue at one end, and aberrant vessels supplying normal lung tissue at the other [3,4] [Table/Fig-1].

Given its rarity, large institutional case series on PS are very few. In this study, we aim to analyse the demographics, presentation, diagnostic imaging, location, type, and treatment of pulmonary sequestration in our institution over a 9-year period. We also compare our findings to those reported in previously published series from different countries to assess regional differences in gender related PS type, and possible genetic and ethnic variations of the disease.

## MATERIALS AND METHODS

We conducted a retrospective medical records review of all patients evaluated and treated in our institution with a pathological proven diagnosis of PS from January 2004 through December 2013. We searched the electronic medical records (EMR) using the key words: pulmonary sequestration, bronchopulmonary sequestration, extralobar and intralobar pulmonary sequestration. Reviewed EMR included office notes, surgical and interventional procedure notes, diagnostic imaging studies, and pathology reports. Our radiologists reviewed all patients' imaging studies. We excluded patients who had imaging studies performed in outside facilities, which were unavailable for our review, and patients who had either an alternative or unproven diagnosis based on



pathology reports. Collected data included demographics, clinical presentation, diagnostic imaging, location of the lesion, type of sequestration, and subsequent treatment.

## RESULTS

### Gender and Age

Of the 29 patients, 15 were males and 14 females, 8 (28%) were children 0-2 years, 1 adolescent age 17 and 20 (69%) adults 21-70 years, with a mean age of 42.

### Presenting Symptoms

In adults, symptoms occurred in 18 patients (90%), with the most common presentation of cough associated with recurrent pulmonary infections in 13 patients (72%), haemoptysis in 3 patients (17%), and chest pain as the primary complaint in 2 patients (11%) [Table/Fig-2].

### Imaging Studies

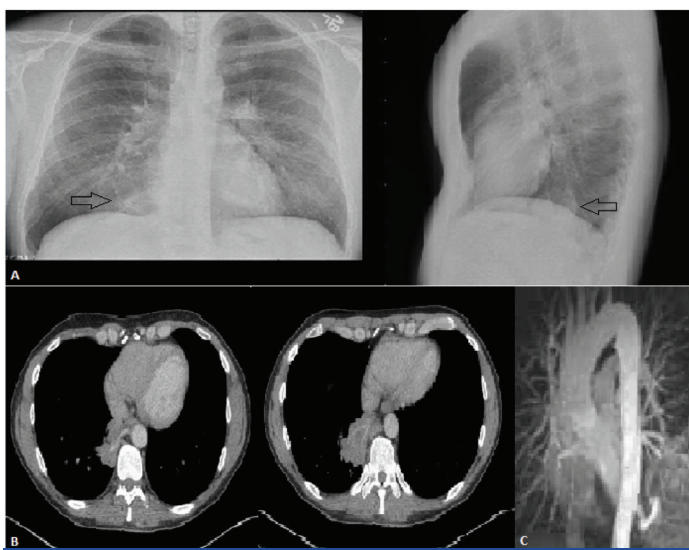
As the majority of the adult patients presented with respiratory symptoms mimicking pneumonia and asthma, chest X-rays were performed on all patients as the first imaging modality, this often

Demographic distribution and characteristics of pulmonary sequestration patients (n = 29)	
<b>Gender</b> Male = 15 (52%) Female = 14 (48%)	<b>Type of sequestration</b> Intralobar: 16 (55%) Extralobar: 13 (45%) 54% (7/13) Males 46% (6/13) Females
<b>Ethnicity</b> Whites: 21 (73%) African Americans: 5 (17%) Hispanics: 3 (10%)	<b>Age related type</b> Adults: 81% intralobar 19% extralobar Children: 38% intralobar 62% extralobar
<b>Age category</b> Children: 8 (28%) Adolescents: 1(3%) Adults: 20 (69%)	<b>Gender related type</b> Males: n = 15 53% (8/15) Intralobar 47% (7/15) Extralobar Females: n = 14 57% (8/14) Intralobar 43% (6/14) Extralobar
<b>Presentation</b> Symptomatic = 18 (62%) Recurrent pulmonary infections 13 (72%) Haemoptysis 3 (17%) Chest pain 2 (11%) Asymptomatic = 11 (38%) All children = 8 Adults = 2 (10% of adults)	<b>Ethnic group related type</b> Whites: n = 21 57% (12/21) Intralobar 43% (9/21) Extralobar African Americans: n = 5 20% (1/5) Intralobar 80% (4/5) Extralobar Hispanics: n = 3 100% 3/3 (intralobar)
<b>Imaging – arterial supply identification</b> CTA: 25 (86%) Pulmonary angiography: 2 (7%) MRA: 2 (7%)	<b>Treatment</b> Surgical resection: 27 (93%) Preoperative embolization: 2/3 of patients with haemoptysis, (7% of all patients) Observation: 2 (7%)
<b>Location of sequestration</b> Left lower lobe = 19 (66%) Other lobes = 10 (34%)	

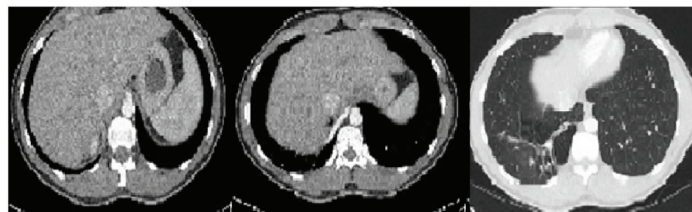**[Table/Fig-2]:** Review of the demographics and characteristics of 29 patients with pulmonary sequestration

showed nonspecific pulmonary opacities such as nodules, reticular infiltrates and mass-like consolidations. On CTA, lesions suspicious for pulmonary sequestration were identified, with a systemic arterial supply to the sequestered segment demonstrated in 25 patients (86%). In 4 patients (14%), where CTA failed to demonstrate the arterial supply, two were diagnosed with angiography and the other two with magnetic resonance angiography (MRA). Furthermore, a large aberrant artery was clearly identified on CTA in all three patients who presented with haemoptysis (PPV=100%) [Table/Fig-3-5].

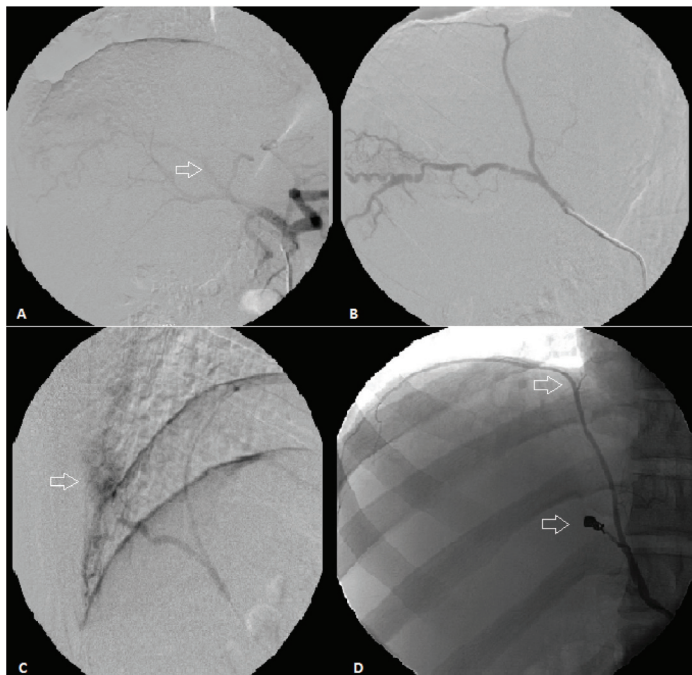
In 19 patients (66%), the PS was located in the left lower lobe and 16 (55%) were intralobar [Table/Fig-2].



**[Table/Fig-3]:** (a) Chest X-Ray, PA and lateral views demonstrating a right lower lobe round mass-like density (arrows), this is better visualized on the lateral view as the mass is located posterior to the heart. (b) Axial CTA chest revealing an aberrant artery branching off the descending thoracic aorta to supply a wedge shaped mass-like vascular lesion in the medial-basal segment of the right lower lobe. (c) 3D reconstructed MRA- left posterior oblique view showing the aberrant artery branching off the descending thoracic aorta, just above the diaphragm.



**[Table/Fig-4]:** Axial CTA chest. A large aberrant arterial supply originating from the abdominal aorta traversing the cruciate ligament of the diaphragm and supplying a sequestered right lower lobe segment. Right image demonstrate the lung window, where an intralobar sequestration appears as a wedge shaped heterogeneous mass of cystic and nodular densities.

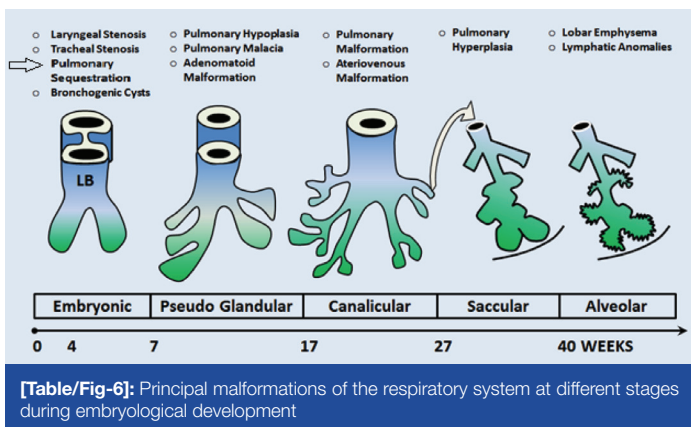


**[Table/Fig-5]:** (a) The celiac axis gives rise to the splenic artery, left gastric and common hepatic artery. An anomalous vessel (arrow) branches off superior and medial to the proper hepatic artery. (b) Selective catheterization of the aberrant artery shows a more medial branch of this vessel extending to the diaphragmatic surface and supplies the diaphragm. (c) The artery travels laterally to supply an area of abnormal vascularity in the right costophrenic sulcus (arrow), representing the area of pulmonary sequestration, which drains into a pulmonary vein. (d) The aberrant artery was embolized using 3 coils (bottom arrow), the major supply to the pulmonary vascularity was eliminated, and the phrenic branch (top arrow) was preserved.

**Age, Gender and Ethnic Group Related Sequestration Type:** In the adult group (21 patients) intralobar sequestrations were found in the majority of cases (81%), while in children the extralobar type was more predominant (62%). Gender distribution of sequestration types revealed a higher prevalence of extralobar sequestrations among males 54% vs. females 46%. However, intralobar sequestrations remained the most common type in both sexes, found in 53% of males and 57% of females. Of the 29 patients the Whites ethnic group formed the majority (21/29) (73%), African Americans (5/29) 17%, and Hispanics (3/29) 10%. Ethnic related variations in sequestration types may not be representative of a true genetic influenced trend of the disease as the numbers of patients in the none-white groups are too small. However, we found a significant predominance of the extralobar type among the African American group of patients (4 of the 5 patients) 80% [Table/Fig-2].

**Treatment**

All children and symptomatic adults were treated surgically with resection of the sequestered segment (93%), and 2 of the 3 patients who initially presented with haemoptysis underwent preoperative embolization (7% of all patients). Surgical treatment was differed in two asymptomatic adults due to significant medical co-morbidities and high operative risk. These were later followed with repeated CT scans.



## DISCUSSION

In 1861, Rokitsansky introduced the first description of the disease, and proposed that PS occurs when pulmonary tissue separates from the lung during embryogenesis; this was later known as “the fraction theory” [6] [Table/Fig-6]. Since then, many theories were introduced to explain the possible underlying pathophysiologic mechanisms producing the malformation [Table/Fig-7] [7-15].

In 1946, Pryce was the first to use the term “pulmonary sequestration”, and classified the disease into intralobar and extralobar types. An intralobar sequestration is the most common form of the disease where the lung malformation remains within the visceral pleura of its lobe, whereas the extralobar type corresponds to a true accessory lung, with a separate pleural envelope and an aberrant venous drainage [7].

As the ectopic accessory bud arise from the primitive foregut, during the fourth week of gestation, a lung-resembling structures develops without communicating with the main bronchial tree, it becomes enveloped by its separate visceral pleura and derives its arterial supply from the systemic circulation. An extralobar sequestration can be sub-classified depending on the level at which the accessory bud branches off the primitive foregut into and intrathoracic type (supradiaphragmatic), and abdominal type (subdiaphragmatic) [16].

Intralobar sequestration theories debate in defining the disease as either a congenital or acquired condition. Theories of the acquired aetiology state that chronic pulmonary infections of a lung tissue disconnected from the normal bronchial tree can cause hypertrophy of a regional systemic artery, hence the aberrant arterial supply. Despite being separated from the bronchopulmonary tree, infections may spread to the sequestered segment from adjacent aerated lung tissue via accessory inter-alveolar or broncho-alveolar connections, e.g. pores of Kohn, and canals of Lambert. These theories are supported by the low incidence of other congenital anomalies in association with intralobar sequestration, as opposed

to the extralobar type [17]. Additionally, more than half of intralobar sequestrations are diagnosed in later childhood or adulthood, while the majority of extralobar types are diagnosed during infancy [18].

Previous studies have demonstrated a greater male prevalence for the extralobar sequestration, approximately 3-4 times more common in males than in females [19-22]. In our population, the extralobar type was only slightly more common in males 54% vs. females 46%. The main clinical manifestations of PS in adults are recurrent respiratory tract infections, and respiratory symptoms that often mimic other common pulmonary diseases, such as pneumonia, asthma, interstitial and obstructive pulmonary diseases [23]. In a recent study, the misdiagnosis rate of PS was reported as high as 87%, due to the wide array of nonspecific symptoms, delaying treatment and limiting therapeutic options [24].

In the largest PS case series, Yong et al., retrospectively evaluated 2625 patients from China, where the majority had presented with respiratory symptoms of cough, sputum production, fever, haemoptysis, and chest pain, while 13% of patients presented with incidental imaging findings without respiratory symptoms.

The main CT findings in this large group of patients included a mass lesions (49%), cystic lesions (29%), cavitory lesions (12%), and pneumonic lesions (8%) [25].

A comparison review of previously published series from different countries [Table/Fig-8] [6,18,25-27], demonstrates a universal male predominance of the disease among the adult population, with the majority of cases being intralobar, and more than 80% of patients typically presenting with respiratory symptoms. Surgical resection of the sequestered lesion was performed in approximately 90% of cases without significant postoperative complications.

Surgical resection remains the standard of care for all patients with PS, as it serves to establish the diagnosis, differentiate anomalous pulmonary tissue from malignancies, and prevent recurrent infectious or haemorrhagic complications [27].

Imaging techniques that can accurately identify the arterial supply and venous drainage of the sequestered segment are considered the cornerstone of preoperative planning. To prevent intraoperative morbidity and mortality caused by an aberrant vascular haemorrhage in these patients, imaging studies are applied as an essential guide for the surgical procedure.

Pulmonary angiography is thought to be the gold standard for diagnosis; however, in recent years, several studies have shown that less invasive imaging techniques such as CTA and MRA may be equally effective and safer alternatives [28-31]. In a study by Yue et al., the treatments planned with CTA showed high accuracy, and sensitivity (both >90%) in both patient and artery-based evaluations, suggesting the potential utility of CTA as the primary tool in pre-treatment planning for most PS patients [32].

Reference	Theory
1861 Rokitsansky	Fraction theory: separation of normally- developed lung.
1878 Ruge	Excess theory: the malformation arises separately from the normal lung as the development of a rudimentary third lung.
1946 Pryce	Traction theory: traction of an anomalous branch of the aorta on a developing lung segment separates it from the bronchopulmonary tree.
1956 Smith	Blood supply theory: Insufficient arterial blood supply results in persistence of embryologic thoracic aortic arteries to the lung segment, with systemic blood pressure induced cystic degeneration of lung tissue.
1958 Boyden	No causal relationship between nonfunctioning lung and systemic artery.
1959 Gebauer and Mason	Theory of acquired anomalies: PS results from recurrent localized infectious process.
1967 Blesovskiy	Failure of embryologic growth factor signaling.
1968 Gene et al.	Congenital bronchopulmonary foregut malformation theory: Accessory lung bud develops in the embryo and becomes either incorporated in the normal lung (Intralobar) or remains separated (extralobar).
1968 Morscarella and Wylie	Intralobar sequestration is a collection of bronchogenic cysts associated with a systemic artery.
1984 Stocker and Malczak	An acquired malformation with arterial supply derived from hypertrophy of pulmonary ligament arteries.
1987 Clements and Warner	Malinosculature theory: a disruption the normal bronchopulmonary connection caused by an insult.

[Table/Fig-7]: Theories in the pathogenesis of Pulmonary Sequestration [7-15]

Study	Age group	No. of cases	Mean Age (years)	Type	Gender	Region	Symptomatic	Treatment
Yong et al., 2011 [25]	All	2625	–	ILS 84% ELS 16%	M: 61% F: 39%	China	87%	–
Ou et al., 2014 [26]	Children	30	4.3	ILS 77% ELS 23%	M: 40% F: 60%	China	90%	Surgical 87%
Gezer et al., 2007 [18]	Adult Children	21 6	23.3	ILS 70% ELS 30%	M: 63% F: 37%	Turkey	74%	Surgical 70%
Van Raemdonck et al., 2001 [27]	Adult Children	15 13	33±13 3±5	ILS 87% ELS 13% ILS 62% ELS 38%	M: 64% F: 36%	Belgium	87% 38%	Surgical 100% Surgical 100%
Halkic et al., 1998 [6]	Adult Children	22 4	25 <1	ILS 73% ELS 27%	M: 62% F: 38%	Switzerland	73%	Surgical 100%
Our study	Adults Children	21 8	42 <2	ILS 81% ELS 19% ILS 38% ELS 62%	M: 52% F: 48%	USA Whites 73% AA 17% Hispanic 10%	90% 0%	Surgical 90% Preop. embolization 7% Surgical 100% (8/8)

**[Table/Fig-8]:** Comparison review of the main pulmonary sequestration series

In our series, CTA had a diagnostic sensitivity and specificity of 86% and 100%, respectively, and served as the primary diagnostic and preoperative planning tool.

## CONCLUSION

Pulmonary sequestration is a rare disease with multiple theoretical aetiologies, often misdiagnosed due to its variable and nonspecific presentations. CTA and other imaging modalities, which can accurately identify the arterial supply and venous drainage of the sequestered segment, are essential for diagnosis and preoperative planning.

## REFERENCES

1. Kravitz RM. Congenital malformations of the lung. *Ped Clin N Am*. 1994; 41(3):453–73.
2. Yucel O, Gurkok S, Gozubuyuk A, Caylak H, Sapmaz E, Kavakli K, et al. Diagnosis and surgical treatment of pulmonary sequestration. *Thorac Cardiovasc Surg*. 2008;56(3):154–57.
3. Felker RE, Tonkin IL. Imaging in Pulmonary Sequestration. *AJR Am J Roentgenol*. 1990;154(2):241–49.
4. Sade MR, Clouse M, Ellis H. The spectrum of pulmonary sequestration. *Ann Thorac Surg*. 1974;18:644–58.
5. Traba OS, Vigara AP, Pajares MP, Zurita MB, Larrucea JAT, Arellano CP. Congenital Lung Malformations, what the radiologist should know. Available from: <http://dx.doi.org/10.1594/ecr2013/C-0457>
6. Halkic N, Cuénoud PF, Corthésy ME, Ksontini R, Boumghar M. Pulmonary sequestration: a review of 26 cases. *Eur J Cardiothorac Surg*. 1998;14(2):127–33.
7. Pryce DM. Lower accessory pulmonary artery with intralobar sequestration of lung; a report of seven cases. *J Pathol Bacteriol*. 1946;58(3):457–67.
8. Smith RA. A theory of the origin of intralobar sequestration of lung. *Thorax*. 1956;11(1):10.
9. Boyden EA. Bronchogenic cysts and the theory of intralobar sequestration: new embryologic data. *J Thorac Cardiovasc Surg*. 1958;35:604–16.
10. Gebauer PW, Mason CB. Intralobar pulmonary sequestration associated with anomalous pulmonary vessels: a nonentity. *Chest*. 1959;35:282–88.
11. Blesovsky A. Pulmonary sequestration: a report of an unusual case and a review of the literature. *Thorax*. 1967;22:351–57.
12. Gene RD, Jaretski AJ III, Ashley CA, Beme AS. Congenital bronchopulmonary foregut malformation; pulmonary sequestration communicating with the gastrointestinal tract. *N Engl J Med*. 1968;278(26):1413–15.
13. Moscarella AA, Wylie RH. Congenital communication between the esophagus and isolated ectopic pulmonary tissue. *J Thorac Cardiovasc Surg*. 1968;55:672–76.
14. Laje P, Martinez-Ferro M, Grisoni E, Dudgeon D. Intraabdominal pulmonary sequestration. A case series and review of the literature. *J Pediatr Surg*. 2006;41(7):1309–12.
15. Stocker JT, Malczak HT. A study of pulmonary ligament arteries: relationship to intralobar sequestration. *Chest*. 1984;86:611–15.
16. Clements BS, Warner JO. Pulmonary sequestration and related congenital bronchopulmonary-vascular malformations: nomenclature and classification based on anatomical and embryologic considerations. *Thorax*. 1987;42(6):401–08.
17. Miller, J.E. Cotes, D.J. Chinn, M.R. (2006). Lung function: theory and measurement in health and disease (6<sup>th</sup> ed.). Malden, Mass.: Blackwell Pub. P. 27.
18. Gezer S, Tastepe I, Sirmali M, Findik G, Türüt H, Kaya S, et al. Pulmonary sequestration: a single-institutional series composed of 27 cases. *J Thorac Cardiovasc Surg*. 2007;133(4):955–59.
19. Corbett HJ, Humphrey GM. Pulmonary sequestration. *Paediatr Respir Rev*. 2004;5(1):59–68.
20. Sakala EP, Perrott WS, Grube GL. Sonographic characteristics of antenatally diagnosed extralobar pulmonary sequestration and congenital cystic adenomatoid malformation. *Obstet Gynecol Surv*. 1994;49:647.
21. Clement BS. Congenital malformations of the lungs and airways. *Pediatric Respiratory Medicine*. St Louis, Mo: Mosby; 1999. 1124–25.
22. Devine PC, Malone FD. Noncardiac thoracic anomalies. *Clin Perinatol*. 2000; 27:865–99.
23. Drkulec V, Nogalo B, Perica M, Plavec D, Pezer M, Turkalj M. Sensitization profile in differential diagnosis: allergic asthma vs. chronic (nonspecific) cough syndrome. *Med Sci Monit*. 2013;19:409–15.
24. Chen BJ, Gao J, Li WM, Zhang SF, Liu D, Liu LX. An analysis of the clinicopathological features and misdiagnosis of 16 adults pulmonary sequestration. *Zhonghua Nei Ke Za Zhi*. 2012;51(1):42–45.
25. Yong W, Fan L. Pulmonary sequestration: a retrospective analysis of 2625 cases in China. *Eur J Cardiothorac Surg*. 2011;40(1):e39–e42.
26. Ou J, Lei X, Fu Z, Huang Y, Liu E, Luo Z, et al. Pulmonary sequestration in children: a clinical analysis of 48 cases. *Int J Clin Exp Med*. 2014;7(5):1355–65. eCollection 2014.
27. Van Raemdonck D, De Boeck K, Devlieger H, Demedts M, Moerman P, Coosemans W, et al. Pulmonary sequestration: a comparison between pediatric and adult patients. *Eur J Cardiothorac Surg*. 2001;19(4):388.
28. Abbey P, Das CJ, Pangtey GS, Seith A, Dutta R, Kumar A. Imaging in bronchopulmonary sequestration. *J Med Imaging Radiat Oncol*. 2009;53:22–31.
29. Lee EY, Siegel MJ, Sierra LM, Foglia RP. Evaluation of angioarchitecture of pulmonary sequestration in pediatric patients using 3D MDCT angiography. *Am J Roentgenol*. 2004;183:183–88.
30. Wang S, Ruan Z, Liu F, Huang H, Song K. Pulmonary sequestration: angioarchitecture evaluated by three-dimensional computed tomography angiography. *Thorac Cardiovasc Surg*. 2010;56:354–56.
31. Kang M, Khandelwal N, Ojili V, Rao KL, Rana SS. Multidetector CT angiography in pulmonary sequestration. *J Comput Assist Tomogr*. 2006;30:926–32.
32. Yue SW, Guo H, Zhang YG, Gao JB, Ma XX, Ding PX. The clinical value of computer tomographic angiography for the diagnosis and therapeutic planning of patients with pulmonary sequestration. *Eur J Cardiothorac Surg*. 2013;43(5):946–51.

### PARTICULARS OF CONTRIBUTORS:

1. Fellow, Department of Pulmonary and Critical Care Medicine, Cleveland Clinic, Florida, 2950 Cleveland Clinic Blvd. 33331, Weston, Florida, USA.
2. Research Fellow, Department of Pulmonary and Critical Care Medicine, Cleveland Clinic, Florida, 2950 Cleveland Clinic Blvd. 33331, Weston, Florida, USA.
3. Fellow, Department of Pulmonary and Critical Care Medicine, Cleveland Clinic, Florida, 2950 Cleveland Clinic Blvd. 33331, Weston, Florida, USA.
4. Fellow, Department of Pulmonary and Critical Care Medicine, Cleveland Clinic, Florida, 2950 Cleveland Clinic Blvd. 33331, Weston, Florida, USA.
5. Attending Physician, Department of Pulmonary and Critical Care Medicine, Cleveland Clinic, Florida, 2950 Cleveland Clinic Blvd. 33331, Weston, Florida, USA.

### NAME, ADDRESS, E-MAIL ID OF THE CORRESPONDING AUTHOR:

Dr. Basheer Tashtoush,  
Fellow, Department of Pulmonary and Critical Care Medicine, Cleveland Clinic Florida,  
2950 Cleveland Clinic Blvd. 33331, Weston, Florida, USA.  
E-mail: Basheer7tash@gmail.com

FINANCIAL OR OTHER COMPETING INTERESTS: None.

Date of Submission: Jul 31, 2015  
Date of Peer Review: Sep 19, 2015  
Date of Acceptance: Oct 22, 2015  
Date of Publishing: Dec 01, 2015