

# Melorheostosis – Case Report of Rare Disease

Rakesh Kumar<sup>1</sup>, S.S. Sankhala<sup>1</sup>, Isha Bijarnia<sup>2</sup>

## What to Learn from this Article?

*Review of Literature of this Rare Disease.*

### Abstract

**Introduction:** Melorheostosis (synonyms: candle bone disease, melting wax syndrome, Leri disease) is a rare chronic bone disorder, first described in 1922 by Leri and Joanny. Men and women are equally affected, and no hereditary features have been discovered. Onset is insidious, and most common symptom is pain. Most common part of bone is diaphysis of the long bone of lower limb rarely the axial skeleton. Classical radiological appearance of 'flowing hyperostosis' resembling hardened wax that has dripped down the side of a candle.

**Case Report:** A 35 years old woman presented with left leg pain with mild swelling and limitation of knee movement. On examination non tender bony hard swelling, hyperpigmented and restriction of knee movement present. Plain radiographs showed extensive, dense, undulating or irregular cortical hyperostosis, resembling candle wax, extending along the length of bone. Pamidronate as well as analgesic were given to the patient. Physiotherapy started for the deformity.

**Conclusion:** Routine laboratory findings usually are normal. The exact cause remain unclear. There is no definite treatment available for this disease. Only symptomatic treatment improve the condition of the patients, more fruitful result obtain with pamidronate and physiotherapy.



**Keywords:** Melorheostosis, rare, benign, insidious, candle wax.

### Introduction

Melorheostosis (synonyms: candle bone disease, melting wax syndrome, Leri disease), first described by Leri and Joanny in 1922[1], is a rare benign sclerosing bone dysplasia. Melorheostosis is a rare disorder characterized by mesodermal dysplasia of bone. Melorheostosis is derives

from the Greek word melos = limb and rheos = flow due to the classic radiological appearance of 'flowing hyperostosis' resembling hardened wax that has dripped down the side of a candle. Men and women are equally affected, and no hereditary features have been discovered. The disorder

### Author's Photo Gallery



### Reviewer's Photo Gallery



<sup>1</sup>Orthopedics Department, SMS Medical College & Hospital, Jaipur, Rajasthan. India.

<sup>2</sup>Anesthetic Department, SMS Medical College & Hospital, Jaipur, Rajasthan. India.

### Address of Correspondence

Dr. Rakesh Kumar, 10 Prem Nagar, Purani Chungi, Ajmer Road, Jaipur 302019, Rajasthan. India.  
Mob. No. 09828419762. Email- silayachrakesh@gmail.com

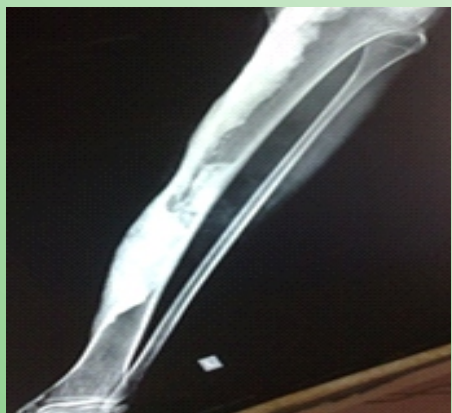

Figure 1: Full Length Leg Bone AP View X-ray.

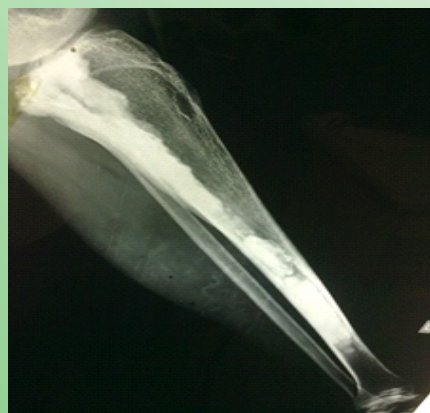

Figure 2: Full Length Leg Bone Lateral View X-ray.

begins in childhood. Most common symptom is pain and onset of disease is insidious [2]. Most common part of bone is diaphysis of the long bone of lower limb rarely the axial skeleton. It may also present with limb-length discrepancy, joint stiffness, progressive deformity, ossification in adjacent soft tissues[3]. The exact cause of disease still remain unclear.

### Case Report

A 35-year-old woman presented with a history of left leg dull and aching pain with mild swelling and limitation of left knee movement. Her limb pain presented since last 20 years. The swelling and restriction of joint movement gradually progressed. There was no relevant family history or trauma. On physical examination, the patient had hard swelling of the left leg. The swelling was bony hard, non tender and hyperpigmented. Skin temperature was normal. In knee joint about 20 degree flexion deformity present. No other abnormality was detected in the right lower limb and upper limbs.

Plain radiographs [Fig 1and 2] of left leg showed extensive, dense, undulating or irregular cortical hyperostosis, resembling candle wax, extending along the length of bone, resulting in deformity of the bone and narrowing of the medullary cavities. Plain radiographs of the bones on the right lower side was normal. Laboratory findings for CBC, serum calcium, phosphorus, alkaline phosphatase, erythrocyte sedimentation rate, C-reactive protein,  $\alpha$ -fetoprotein, carcinoembryonic antigen were within normal limits. The pathology report described nonspecific, dense cortical bone. The hyperostotic bone consisted of mature and immature bone elements. Treatment Pamidronat 30mg daily for 6 days as well as analgesic were given to the patient. Physiotherapy started for the deformity. After 3 months in

follow up, the patient reported alleviation of the pain.

### Discussion

Melorheostosis is a rare chronic bone disorder which was first described in 1922 by Leri and Joanny[1]. Male and female are equally affected, and no hereditary features have been discovered. The onset of this rare diseases is insidious, and the first symptom is usually pain because of the sub periosteal bone formation. Range of movement limitation and joint

deformities develops gradually[2]. Skin changes may be seen in about 17% of cases and that may include hyperpigmentation of overlying skin and scleroderma. Melorheostosis mainly affects, the long bones of the upper and lower limbs, and also the short bones of the hand and foot, but rarely the axial skeleton[3,4]. Melorheostosis may be associated with the tumours, including osteogenic sarcoma, malignant fibrous histiocytoma and dermoid tumours[5,6].

Melorheostosis may present in a monostotic, polyostotic, or monomelic form. The monomelic variant is the most common presentation of this rare disease [7]. In this patient, left leg was affected. Melorheostosis is often thought as a benign sclerosing bone dysplasia. The several hypothesis are given but the exact aetiology remain unclear. Murray and McCredie 1979[8], hypothesis was that, embryonic infection of nerve root causes neural scarring and segmental bone sclerosis responsible for melorheostosis, because they detected a good correlation between hyperostotic lesions and the sclerotomes. However, according to the hypothesis of Murray and McCredie, when infection encroaches on nerve roots, the involved nerve roots should adjoin each other.

Kim J-E demonstrated down regulation of adhesion proteins involved in osteoblastic regulation, specifically transforming growth factor  $\beta$  induced gene product, which may contribute to the development of hyperostosis and associated soft tissue abnormalities[9]. One possible etiology of melorheostosis is a loss of function mutation in the LEMD3 gene (12q12–12q14.3), a protein involved in bone morphogenic protein and tumor growth factor- $\beta$  signaling[10,11]. These two hypothesis support the genetic involment of this rare disease so further work have to be done, to find out exact cause and role of gene therapy for this disease.

It is associated with vascular malformations, soft tissue masses

adjacent to the affected bone and scleroderma of the overlying skin[12,13,14]. Routine laboratory findings usually are normal. Histologic findings are usually nonspecific and often show dense bone formation, a mixture of mature and immature bone elements[14]. Osteoclastic activity is not a prominent feature; however, osteoblastic activity along the margins of osteons is common[15]. Treatment is mainly symptomatic. Most patient receives nonoperative treatment. Operative treatment consists of tendon lengthening, excision of hyperostotic bone, osteotomies, sympathectomy and amputation[4]. Bisphosphonate are commonly use[16]. Potential causes of the bone pain in melorheostosis include increased osteoclastic bone resorption and activation of pain receptors, raised intraosseous pressure and increased vascularity secondary to hyperostosis and soft tissue involvement around joints. Thus, bisphosphonate treatment via a number of mechanisms would be expected to reduce inflammatory bone pain and symptoms in melorheostosis bisphosphonates inhibit osteoclast-mediated bone resorption by direct and indirect actions on osteoblasts and macrophages and bone vascularity. They have been shown to decrease bone pain, slow progression of bone lesion [17]. The prognosis of a patient with melorheostosis is variable and depends on the anatomical location, extension into the soft tissues, and soft tissue changes. Melorheostosis does not shorten life span, however, morbidity may be considerable. The disease exhibits a slow, chronic course, with periods of exacerbation and arrest. Recurrence usually is expected after operative excision [18].

### Conclusion

All routine laboratory findings usually normal. It is only diagnosed by characteristic candle wax type appearance in x-ray film. There is no definite treatment available for this disease. Only symptomatic treatment improve the condition of the patients, more fruitful result obtain with pamidronat and physiotherapy.

### Clinical Message

It is very rare benign disease. It is diagnosed by characteristic x-ray finding. There is no definite treatment available only symptomatic is given.

### References

1. Leri A, Joanny J. Une affection non décrite des os hyperostose "en coulée" sur toute la longueur d'un membre ou "melorhéostose." *Bull Mem Soc Med Hosp Paris.* 1922;46:1141-1145.
2. Biaou O, Avimadje M, Guira O, Adjagba A, Zannou M, Hauzeur JP. Melorheostosis with bilateral involvement in a black African patient. *Joint Bone Spine.* 2004;71:70-72.
3. Greenspan A, Azouz EM. Bone dysplasia series: melorheostosis: review and update. *Can Assoc Radiol J.* 1999;50:324-330.
4. Freyschmidt J.: Melorheostosis: a review of 23 cases. *Eur Radiol* 2001; 11: 474-9
5. Baer SC, Ayala AG, Ro JY, et al. Case report 843. Malignant fibrous histiocytoma of the femur arising in melorheostosis. *Skeletal Radiol* 1994; 23: 310.
6. Murphy M, Cavanagh M, Hurson B, et al. Occurrence of Osteosarcoma In a Melorheostotic Femur. *Ir Med J* 2003; 96: 55-6.
7. Zeiller SC, Vaccaro AR, Wimberley DW, Albert TJ, Harrop JS, Hilibrand AS. Severe myelopathy resulting from melorheostosis of the cervicothoracic spine: a case report. *J Bone Joint Surg Am.* 2005;87:2759-2762.
8. Murray RO, McCredie J. Melorheostosis and the sclerotomes: a radiological correlation. *Skeletal Radiol.* 1979;4:57-71.
9. Kim J-E, Kim E-H, Han E-H, et al. A TGF- $\beta$ -inducible cell adhesion molecule,  $\beta$ ig-h3, is downregulated in melorheostosis and involved in osteogenesis. *J Cell Biochem* 2000; 77: 169-78.
10. Mumm S, Wenkert D, Zhang X, McAlister WH, Mier RJ, Whyte MP. Deactivating germline mutations in LEMD3 cause osteopoikilosis and Buschke-Ollendorff syndrome, but not sporadic melorheostosis. *J Bone Miner Res.* 2007;22:243-250.
11. Hellemans J, Preobrazhenska O, Willaert A, Debeer P, Verdonk PC, Costa T, et al. Loss-of-function mutations in LEMD3 result in osteopoikilosis, Buschke-Ollendorff syndrome and melorheostosis. *Nat Genet.* 2004;36:1213-1218.
12. Morris JM, Samilson RL, Corley CL. Melorheostosis. Review of the literature and report of an interesting case with nineteen year follow up. *J Bone Joint Surg* 1963; 45A: 1191-2000.
13. Judkiewicz AM, Murphey MD, Resnik CS, et al. Advanced imaging of melorheostosis with emphasis on MRI. *Skeletal Radiol* 2001; 30: 447-53.
14. Ethunandan M, Khosla N, Tilley E, Webb A. Melorheostosis involving the craniofacial skeleton. *J Craniofac Surg.* 2004;15:1062-1065.
15. Campbell CJ, Papademetriou T, Bonfiglio M. Melorheostosis: a report of the clinical, roentgenographic, and pathological findings in fourteen cases. *J Bone Joint Surg Am.* 1968;50:1281-1304.
16. Donath J, Poor G, Kiss C, et al. Atypical form of active melorheostosis and its treatment with bisphosphonate. *Skeletal Radiol* 2002; 31: 709-13.
17. Wood J, Bonjean K, Ruetz S, et al. Novel antiangiogenic effects of the bisphosphonate compound zoledronic acid. *J Pharm Experimental Therapeutics* 2002; 302: 1055-61.
18. Goldman AB, Schneider R, Huvos AS, Lane J. Case report 778. Melorheostosis presenting as two soft-tissue masses with osseous changes limited to the axial skeleton. *Skeletal Radiol.* 1993; 22(3):206-210.

Conflict of Interest: Nil  
Source of Support: None

#### How to Cite this Article:

Kumar R, SS Sankhala, Bijarnia I. Melorheostosis – Case Report of Rare Disease. *Journal of Orthopaedic Case Reports* 2014 April-June;4(2): 25-27