



# A Case of Ocular Angiostrongyliasis with Molecular Identification of the Species in Vietnam

Nguyen Van De<sup>1,\*</sup>, Le Van Duyet<sup>2</sup>, Jong-Yil Chai<sup>3</sup>

<sup>1</sup>Department of Parasitology, Hanoi Medical University, Hanoi, Vietnam; <sup>2</sup>Department of Immunology, Institute of Bio-Technology, Hanoi, Vietnam; <sup>3</sup>Department of Parasitology and Tropical Medicine, Seoul National University College of Medicine, Seoul 03080, Korea

**Abstract:** A 23-year-old female residing in a village of Cao Bang Province, North Vietnam, visited the Hospital of Hanoi Medical University in July 2013. She felt dim eyes and a bulge-sticking pain in her left eye for some days before visiting the hospital. In the hospital, a clinical examination, an eye endoscopy, and an operation were carried out. A nematode specimen was collected from the eye of this patient. The body of this worm was thin and long and measured 22.0×0.3 mm. It was morphologically suggested as an immature female worm of *Angiostrongylus cantonensis*. By a molecular method using 18S rRNA gene, this nematode was confirmed as *A. cantonensis*. This is the first molecular study for identification of *A. cantonensis* in Vietnam.

**Key words:** *Angiostrongylus cantonensis*, eosinophilic meningoencephalitis, eye

## INTRODUCTION

In the genus *Angiostrongylus*, a total of 21 species have been described, including 2 species which cause diseases in humans such as *Angiostrongylus cantonensis* and *Angiostrongylus costaricensis* [1,2]. *A. cantonensis* causes eosinophilic meningoencephalitis in humans damaging the brain tissues, which result in bleeding, inflammation, and granuloma formation [1]. Neurological symptoms vary with the region affected. On the other hand, *A. costaricensis* causes abdominal infections [2].

*A. cantonensis* was first found from the lungs of rats *Rattus norvegicus* and *Rattus rattus* in 1935 by Chen in China [2]. The first human case infected with *A. cantonensis* was reported by Nomura and Lin in 1945 in Taiwan [2]. In 1962, Rosen et al. [3] reported 2 cases of eosinophilic meningoencephalitis caused by *A. cantonensis* and called the worm as the rat lung-worm. After then, *A. cantonensis* has been detected in Madagascar, Hawaii, South East Asia, and Japan [2]. Meanwhile, *A. costaricensis* was detected for the first time in Costa Rica, and then in Middle America and North America [2].

In Vietnam, eosinophilic meningoencephalitis caused by *A. cantonensis* was first detected in 1976 [4]. Phan [4] reported 2 human cases (3- and 7-year old) with symptoms like fever, vomiting, snatched legs, leg pain, paralyzes, positive meningoencephalitis, and eosinophilia (29-59%). In addition, An [5] reported 15 children cases (1-15 years old) of eosinophilic meningoencephalitis due to *A. cantonensis* infection in the National Children Hospital during 1995-2000. After then, De et al. [6,7] reported 5 cases of angiostrongyliasis in 2004 and another case in 2008. We report here an additional case of human angiostrongyliasis caused by *A. cantonensis*; the species was molecularly confirmed for the first time in Vietnam.

## CASE RECORD

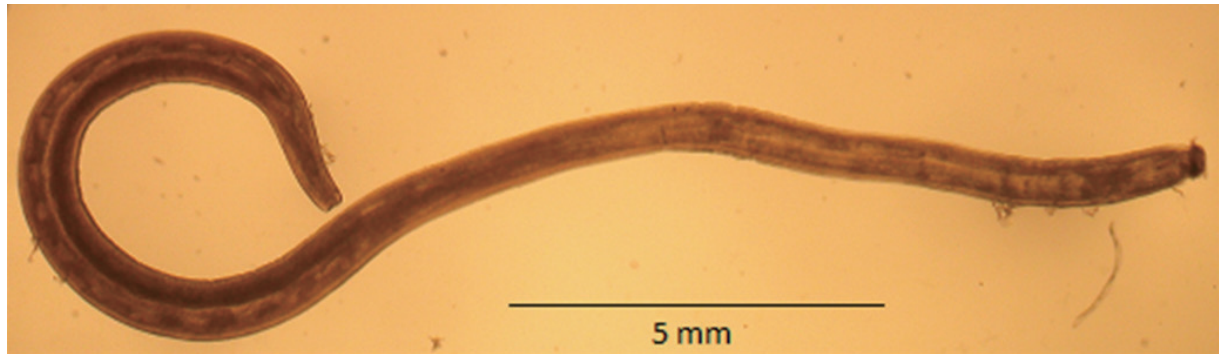The patient was a 23-year-old female residing in the Chi Thao Village, Quang Yen District, Cao Bang Province, North Vietnam. In July 2013, she felt dim eyes and a bulge-sticking pain in her left eye for some days at home. She visited the provincial hospital and then the Hospital of Hanoi Medical University, Hanoi, Vietnam. In the hospital, a clinical examination and an eye endoscopy were carried out, and a nematode worm was seen in the left eye. This nematode specimen was collected from the eye of this patient by operation. The body of this worm was thin and long and measured 22 mm in length and 0.3 mm in width (Fig. 1). It was morphologically suggested as

•Received 13 July 2015, revised 2 September 2015, accepted 29 September 2015.

\*Corresponding author (ngvdeyh@gmail.com)

© 2015, Korean Society for Parasitology and Tropical Medicine

This is an Open Access article distributed under the terms of the Creative Commons Attribution Non-Commercial License (<http://creativecommons.org/licenses/by-nc/3.0>) which permits unrestricted non-commercial use, distribution, and reproduction in any medium, provided the original work is properly cited.



**Fig. 1.** An immature female worm of *Angiostrongylus cantonensis* collected from the human eye in this study.

**Table 1.** Sequencing of a portion of 18S ribosomal RNA of different *Angiostrongylus* isolates from GenBank compared with *Angiostrongylus cantonensis* in Vietnam

Notation	Origin	Host	Length	Species	GenBank no.	Author
AC-VN	Vietnam	Human	522	<i>A. cantonensis</i>	-	This study
AC-NO	USA	Snail ( <i>Pomacea insularum</i> )	522	<i>A. cantonensis</i>	GU587760	Qvarnstrom et al. [12]
AC-BR	Brazil	Mollusk	522	<i>A. cantonensis</i>	GU733321	Qvarnstrom et al. [12]
AC-SZ1	China	Rat	522	<i>A. cantonensis</i>	GU540546	Liu et al. [13]
AC-SZ2	China	Rat	522	<i>A. cantonensis</i>	GU540547	Liu et al. [13]
AC-QY	China	Rat	522	<i>A. cantonensis</i>	GU540549	Liu et al. [13]
AC-WZ	China	Rat	522	<i>A. cantonensis</i>	GU540551	Liu et al. [13]
AC-CR	Costa Rica	Mollusk	522	<i>A. costaricensis</i>	GU587745	Qvarnstrom et al. [12]
AC-UK	UK	<i>Vulpes</i>	522	<i>A. vasorum</i>	GU045374	Jefferies et al. [14]

an immature (female) worm of *A. cantonensis*.


By the molecular method using a portion of 18S *rRNA* gene, this Vietnamese *Angiostrongylus* was sequenced and compared with different worldwide *A. cantonensis* isolates from GenBank (Table 1). A comparison was made on 522 nucleotides of a portion of 18S *rRNA* gene between the Vietnamese *Angiostrongylus* and isolates from USA (AC-NO), Brazil (AC-BR), China (AC-SZ1, AC-SZ2, AC-QY, and AC-WZ), Costa Rica (AC-CR), and UK (AV-UK). The results revealed 99% identity with other *A. cantonensis* reported in GenBank (Fig. 2).

## DISCUSSION

The symptoms in angiostrongyliasis patients in Vietnam included headache (15/15), fever (12/15), vomiting (11/15), harden neck (8/15), and eosinophilia (31.5-48.5%) [4]. In 2004, De et al. [6] also reported 5 cases (19-month to 10-year-old) of angiostrongyliasis with the symptoms of headache (5/5), fever (5/5), vomiting (4/5), snatched leg (5/5), disordered reflected knee (5/5), leg paralysis (5/5), positive meningoencephalitis (5/5), eosinophilia (5/5 with 19-30%), and

positive ELISA with *Angiostrongylus* antigen (5/5). A worm was collected from 1 of the 5 patients [6]. These symptoms were similar to those reported previously in Taiwan [8]. However, eosinophilic meningoencephalitis due to *A. cantonensis* occurred more and more often in Vietnam [7]. The parasitic place of *Angiostrongylus* was usually the brain, but can be in other places, including the eyes. In 2001, Xuan et al. [9] also reported a case infected with *A. cantonensis* in the eye.

The incidence of ocular angiostrongyliasis is low; however, it can cause hypopsia or even vision loss, which would seriously affect the quality of the life of patients [10]. Feng et al. [10] reviewed total 42 ocular cases reported worldwide; nearly a half of them were from Thailand and the rest were from other Asian countries, including Sri Lanka, India, Taiwan, Vietnam, Malaysia, Japan, and Indonesia. In most cases, worms were found from the anterior chamber or vitreous fluid, and in a few cases they were from the retina or subretina [10]. The majority of the ocular cases was not associated with cerebrospinal symptoms; only 12 of the 42 cases suffered from eosinophilic meningitis [10]. In our case, the patient felt dim eyes and a bulge-sticking pain in her left eye; however, she developed no further symp-



**Fig. 2.** Comparison of 522 nucleotides of a portion of 18S ribosomal RNA gene (*18S rRNA*) between the Vietnamese *Angiostrongylus cantonensis* and isolates from USA (AC-NO), Brazil (AC-BR), China (AC-SZ1, AC-SZ2, AC-QY, AC-WZ), Costa Rica (AC-CR), and UK (AV-UK). Note similarities between the Vietnamese (*A. cantonensis* Vietnam) and other isolates. Mark (.) is similar to each other in nucleotides; mark (-) is mismatching.

toms like meningoencephalitis. After the surgical removal of the worm, her eye symptoms completely disappeared.

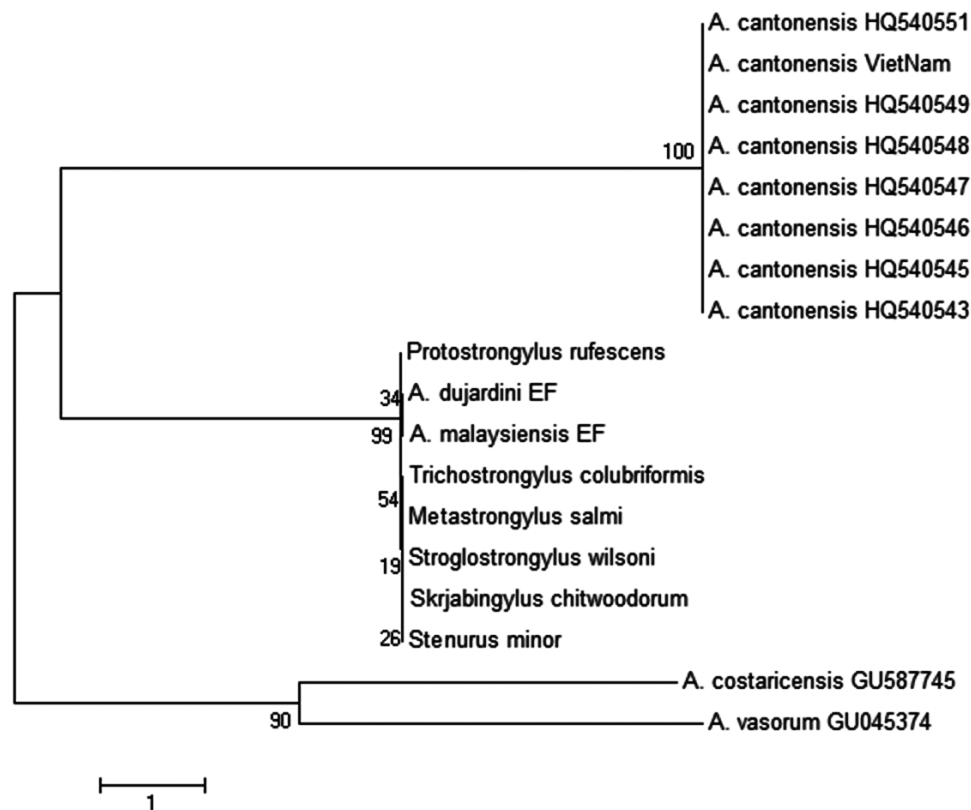
The phylogenetic tree of *A. cantonensis* Vietnam and other strains from different countries targeting a part of *18S rRNA* nucleotide sequences was constructed by the neighbor-joining (NJ) method using MEGA4.0 [11]. It has been shown that the Vietnamese *A. cantonensis* is located in the same group with other *A. cantonensis* isolates available in GenBank (Fig. 3). The present study is the first to identify the species of the nematode by a molecular method in Vietnam.

### ACKNOWLEDGMENTS

This research was funded by Vietnam National Foundation for Science and Technology Development (NAFOSTED) under grant no. 106-YS.05-2014.08, and collaborated with the National Hospital of Eyes, Hanoi, Vietnam.

### CONFLICT OF INTEREST

We have no conflict of interest related to this work.



**Fig. 3.** Phylogenetic tree of *Angiostrongylus cantonensis* Vietnam and other isolates targeting a part of 18S *rRNA* nucleotide sequences estimated by the neighbor-joining (NJ) using MEGA4.0 [9]. Note: *A. cantonensis* Vietnam = Vietnamese *Angiostrongylus*; *A. cantonensis* – GenBank no. HQ540548; *A. cantonensis* – GenBank no. HQ540547; *A. cantonensis* – GenBank no. HQ540546; *A. cantonensis* – GenBank no. HQ540545; *A. cantonensis* – GenBank no. HQ540543; *A. cantonensis* – GenBank no. HQ540551; *A. cantonensis* – GenBank no. HQ540549; *A. dujardini* EF – GenBank no. EF514915; *A. malaysiensis* EF – GenBank no. EF514914; *Metastrongylus salmi* – GenBank no. AY295809; *Protostrongylus rufescens* – GenBank no. AJ920364; *Skrjabinstrongylus chitwoodorum* – GenBank no. AY295819; *Stenurus minor* – GenBank no. AY295817; *Stroglostrongylus wilsoni* – GenBank no. AY295820; *Trichostrongylus colubriformis* – GenBank no. AJ920350; *A. costaricensis* – GenBank no. GU587745; *A. vasorum* – GenBank no. GU045374.

## REFERENCES

1. Spratt DM. Species of *Angiostrongylus* (Nematoda: Metastrongyloidea) in wildlife: a review. *Int J Parasitol Parasites Wildl* 2015; 4: 178-189.
2. Miyazaki I. Angiostrongyliasis. In *Helminthic Zoonoses*. Tokyo, Japan. International Medical Foundation of Japan. 1991, pp 347-355.
3. Rosen L, Chappell R, Laqueur GL, Wallace GD, Weinstein PP. Eosinophilic meningoencephalitis caused by a metastrongylid lung-worm of rats. *JAMA* 1962; 179: 620-624.
4. Phan TN. *Angiostrongylus cantonensis*. In *Textbook for Training Medical Doctors of Hanoi University*. Hanoi, Vietnam. National Hospital of Tropical Diseases. 2009, pp. 246-247 (in Vietnamese).
5. An PN. Some comments for eosinophilic meningoencephalitis in children in National Hospital of Children from 1995 to 2000. *J Pract Med* 2002; No. 3: 66-69 (in Vietnamese).
6. De NV. Report of eosinophilic meningoencephalitis caused by *Angiostrongylus*. *J Pharm-Med Inform* 2004; No. 5: 15-16 (in Vietnamese).
7. Hwang KP, Chen ER. Clinical studies on *Angiostrongylus cantonensis* among children in Taiwan. *Southeast Asian J Trop Med Public Health* 1991; 22(suppl): 194-199.
8. De NV, An PN, Huong TTT. Eosinophilic meningoencephalitis caused by *Angiostrongylus*. *J Pharm-Med Inform* 2008; No. 11: 9-13.
9. Xuan LT, Dung DH, Hien TV. A case infected by *Angiostrongylus cantonensis* in the eye in Ho Chi Minh City. *J Med Ho Chi Minh City* 2001; No. 1: 97-100 (in Vietnamese).
10. Feng Y, Nawa Y, Sawanyavisuth K, Lv Z, Wu ZD. Comprehensive review of ocular angiostrongyliasis with special reference to optic neuritis. *Korean J Parasitol* 2013; 51: 613-619.
11. Tamura K, Nei M, Kumar S. Prospects for inferring very large

- phylogenies by using the neighbor-joining method. Proc Natl Acad Sci USA 2004; 101: 11030-11035.
12. Qvamstrom Y, da Silva ACA, Teem JL, Hollingsworth R, Bishop H, Graeff-Teixeira C, da Silva AJ. Improved molecular detection of *Angiostrongylus cantonensis* in mollusks and other environmental samples with a species-specific internal transcribed spacer 1-based TaqMan assay. Appl Environ Microbiol 2010; 76: 5287-5289.
  13. Liu YJ, Han YP, Li ZY, Wei J, He HJ, Xu CZ, Zheng HQ, Zhan XM, Wu ZD, Lv ZY. Molecular cloning and characterization of cystatin, a cysteine protease inhibitor, from *Angiostrongylus cantonensis*. Parasitol Res 2010; 107: 915-922.
  14. Jefferies R, Shaw SE, Willesen J, Viney ME, Morgan ER. Elucidating the spread of the emerging canid nematode *Angiostrongylus vasorum* between Palearctic and Nearctic ecozones. Infect Genet Evol 2010; 10: 561-568.

