

## A case of corneal cystinosis in a patient with rickets and chronic renal failure

Jae Yon Won, Hyung Bin Hwang<sup>1</sup>, Sung Kun Chung<sup>2</sup>

A 22-year-old man diagnosed with nephropathic cystinosis at the age of 4 years was found to have progressive bilateral corneal crystal deposition. He presented with severe photophobia and decreased visual acuity. Ocular cystinosis was diagnosed on observing the typical crystals. Optical coherence tomography showed multiple areas of stromal hyperreflectivity due to crystal deposits within the corneal stroma. *Ex vivo* transmission electron microscopy of the cornea showed pathognomonic crystal deposits in corneal stromal keratocytes. Using polymerase chain reaction sequencing of the entire coding region, we identified five gene mutations, including two unreported mutations.

**Key words:** Optical coherence tomography, transmission electron microscopy, variants

A 22-year-old man diagnosed with nephropathic cystinosis at the age of 4 years was found to have progressive bilateral corneal crystal deposition. Optical coherence tomography (OCT) showed multiple areas of stromal hyper-reflectivity due to crystal deposits, and *ex vivo* transmission electron microscopy (TEM) of the cornea showed pathognomonic crystal deposits in corneal stromal keratocytes.

Nephropathic cystinosis is a rare autosomal recessive metabolic disorder characterized by a defect in lysosomal cystine transport.<sup>[1]</sup> Cystinosis is mapped to the CTNS gene on the short arm of chromosome 17 which encodes cystinosin,<sup>[2]</sup> a 367-amino acid transmembrane protein.<sup>[3]</sup> The main pathological finding is the intralysosomal accumulation of cystine crystals within most tissues as a result of defective transport.<sup>[4]</sup> This process eventually causes intracellular crystal deposits in tissues such as the conjunctivae, corneas, kidneys, and bone marrow.<sup>[2]</sup> The corneal accumulation of needle-shaped cystine crystals is characteristic and progresses from the epithelium toward the endothelium through the stroma of the cornea.<sup>[5]</sup> There are three main phenotypes of cystinosis: Infantile nephropathic cystinosis, the classic form, accounting for 95% of cases; juvenile cystinosis, the less severe late-onset variant; and adult cystinosis, the benign non-nephropathic form.<sup>[2]</sup> Cystine transport is retained partially

in patients with the intermediate and ocular forms resulting from milder mutations in the CTNS gene.<sup>[2]</sup>

We present a case of ocular cystinosis confirmed by anterior segment OCT and TEM showing cystine crystals in the cornea, and we identified five mutations, including two unreported ones, using sequencing analysis of the CTNS exon.

### Case Report

A 22-year-old man presented with severe photophobia and decreased visual acuity in the right eye. He was diagnosed initially with nephropathic and ocular cystinosis at the age of 4 years. The patient also had chronic renal failure and rickets. The visual acuity was hand motion in the right eye and 4/4 in the left eye. The intraocular pressure was 17 mmHg in the right eye, while that of the left eye could not be measured because the patient was uncooperative. In slit lamp examination, we found the moderate corneal edema and multiple crystal deposits in the right eye and an anterior segment photograph also showed opacity, moderate edema, and multiple progressive refractile polychromatic crystal deposits in the right cornea. Cystagon® (cysteamine bitartrate, Mylan, France) eye drops were prescribed, but there was no improvement in the patient's visual acuity or symptoms. Therefore, we performed penetrating keratoplasty of his right eye. Preoperative anterior segment OCT (Visante, Carl Zeiss Meditec) showed hyperreflectivity at the stroma of the cornea, indicating the presence of corneal cystine crystals [Fig. 1]. *Ex vivo* light

This is an open access article distributed under the terms of the Creative Commons Attribution-NonCommercial-ShareAlike 3.0 License, which allows others to remix, tweak, and build upon the work non-commercially, as long as the author is credited and the new creations are licensed under the identical terms.

**For reprints contact:** reprints@medknow.com

**Cite this article as:** Won JY, Hwang HB, Chung SK. A case of corneal cystinosis in a patient with rickets and chronic renal failure. Indian J Ophthalmol 2015;63:785-7.

#### Access this article online

##### Website:

www.ijo.in

##### DOI:

10.4103/0301-4738.171509

#### Quick Response Code:



Department of Ophthalmology and Visual Science, Seoul St. Mary's Hospital, College of Medicine, The Catholic University of Korea, <sup>1</sup>Department of Ophthalmology and Visual Science, Incheon St. Mary's Hospital, College of Medicine, The Catholic University of Korea, <sup>2</sup>Department of Ophthalmology and Visual Science, St. Paul's Hospital, College of Medicine, The Catholic University of Korea, Seoul, South Korea

**Correspondence to:** Prof. Sung Kun Chung, Department of Ophthalmology and Visual Science, St. Paul's Hospital, College of Medicine, The Catholic University of Korea, 180 Wangsan-ro Dongdaemun-gu, Seoul, 130-709, Republic of Korea. E-mail: eyedoc@catholic.ac.kr

**Manuscript received:** 06.10.14; **Revision accepted:** 22.09.15

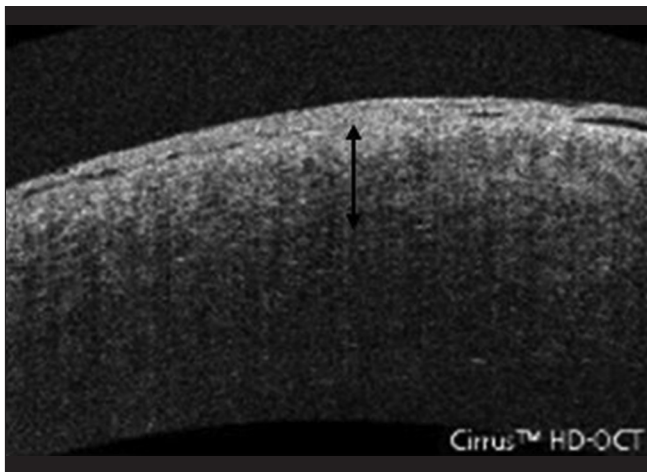
microscopy (LM) of the right cornea performed using special stains for colloidal iron and Masson's trichrome failed to show the crystalline deposits [Fig. 2]. TEM of a corneal biopsy specimen obtained during the operation showed needle-shaped crystalline deposits within keratocytes in corneal stroma of the right eye [Fig. 3]. To examine the genetics of ocular cystinosis, genomic DNA was extracted from peripheral leukocytes using standard protocols. Sequencing analysis identified three known single nucleotide variants (SNVs) and two novel mutations in exon 11 of the CTNS gene [Table 1].

## Discussion

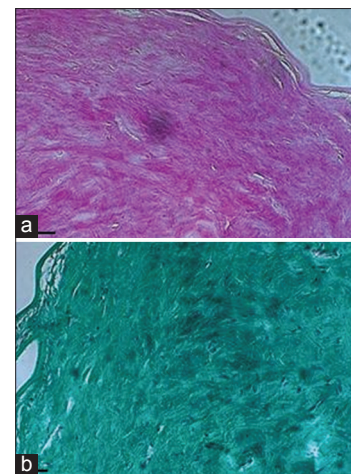
The typical untreated child with cystinosis has a short stature, light complexion, rickets, and photophobia.<sup>[6]</sup> Our patient had been diagnosed with rickets and growth failure. We evaluated the status of the cornea using several tools. Anterior segment OCT showed that the anterior one-third of the corneal stroma was hyperreflective, while the posterior two-third was not. The use of TEM to demonstrate the presence of intracellular crystals within corneal keratocytes is a reliable diagnostic tool for cystinosis.<sup>[7,8]</sup> In our case, TEM showed square or oblong cystine deposits measuring 0.5–2 μm in length. TEM and anterior segment OCT are useful for ocular cystinosis. These tools are useful in ocular cystinosis cases. Our patient presented with severe photophobia and decreased visual acuity in the right eye. However, *ex vivo* LM did not show crystalline deposits in the cornea, while *ex vivo* TEM did show a few such crystalline deposits. Therefore, the degree of symptoms does not correlate with deposits in the cornea, and even a small amount of crystals can cause problems. Topical cysteamine treatment has proven safe and efficient at dissolving corneal

crystals in cystinosis patients; it also relieves the symptoms of photophobia, blepharospasm, and ocular pain.<sup>[9]</sup> Although our patient had used topical cysteamine, he presented with severe photophobia and decreased visual acuity. Therefore, penetrating keratoplasty was performed.

The basic defect involved in cystinosis is impaired transport of cystine across the lysosomal membrane. The gene for cystinosis (CTNS) was mapped to chromosome 17p13 by linkage analysis,<sup>[10]</sup> and then isolated.<sup>[3]</sup> This gene contains 12 exons spanning 23 kb of genomic DNA, and exons 3–12 are coding. CTNS mutations result in either the complete abolition of or a reduction in cystine transport.<sup>[2,11]</sup> The CTNS gene product, cystinosin, comprises 367 amino acids, seven predicted transmembrane domains, a GY dipeptide for lysosomal targeting near the C-terminus, and eight potential glycosylation sites. Cystinosin has homology with a 55.5-kDa *Caenorhabditis elegans* protein and the yeast protein ERS1,<sup>[12]</sup> it facilitates cystine egress from lysosomes. At least 85 different CTNS mutations have been reported in the Human Gene Mutation Database (<http://www.hgmd.org/>). In cystinosis, the most common CTNS mutation is a 57-kb deletion in which the 3' border cuts into exon 10.<sup>[12]</sup> Our patient lacked the 57-kb deletion, but sequencing analysis of all CTNS exons revealed three known SNVs located in intron 6 and exons 7 and 10 in the dbSNP (<http://www.ncbi.nlm.nih.gov/snp/>) (rs459613, rs200313254, rs161400), and two novel mutations in exon 11 (c. 854C > A, c. 943C > T). Of the two novel gene mutations, one (c. 943C > T) resulted in an amino acid substitution (p.Gln315X), and the other (c. 854C > A) likely affected splicing during transcription because of its location near a predicted acceptor splice site,<sup>[13]</sup> which would result in an abnormal splicing.



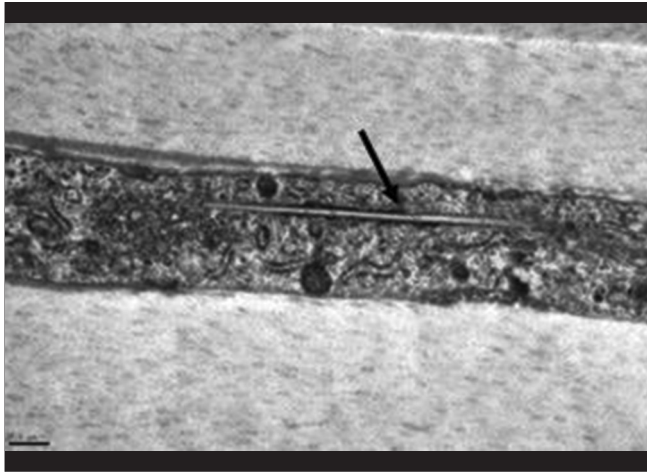
**Figure 1:** Corneal cystine deposition is observed as optical hyperreflectivity of right anterior one-third (arrow), as shown by cross-sectional anterior segment optical coherence tomography



**Figure 2:** *Ex vivo* light microscopy of the right eye (a) Colloidal iron stain, (b) Masson's trichrome stain (Scale bar = 0.5 μm)

**Table 1: CTNS gene analysis**

Type	Exon/Intron #	Nucleotide change	Amino acid change	Zygoty	rs cluster #
SNV	Intron6	c. 329+22C>G	-	Homozygous	rs459613
SNV	Exon7	c. 368T>G	p.Ile123Ser	Heterozygous	rs200313254
SNV	Exon10	c. 779C>T	p.Pro296=	Homozygous	rs161400
Mutation	Exon11	c. 854C>A		Heterozygous	
Mutation	Exon11	c. 943C>T	p.Gln315X	Heterozygous	



**Figure 3:** Electron micrographs of corneal stroma. Crystalline material deposits are shown in keratocyte of stroma layer (arrow). Note that crystalline deposits are also shown to be membrane-limited at higher magnification (Scale bar = 0.5  $\mu$ m)

As demonstrated in our patient, TEM and anterior segment OCT are useful to make a diagnosis of ocular cystinosis. Additional gene analysis using complementary DNA may confirm the function of the novel gene.

#### Financial support and sponsorship

Nil.

#### Conflicts of interest

There are no conflicts of interest.

#### References

- Iwata F, Kuehl EM, Reed GF, McCain LM, Gahl WA, Kaiser-Kupfer MI. A randomized clinical trial of topical cysteamine disulfide (cystamine) versus free thiol (cysteamine) in the treatment of corneal cystine crystals in cystinosis. *Mol Genet Metab* 1998;64:237-42.
- Gahl WA, Thoene JG, Schneider JA. Cystinosis. *N Engl J Med* 2002;347:111-21.
- Town M, Jean G, Cherqui S, Attard M, Forestier L, Whitmore SA, *et al.* A novel gene encoding an integral membrane protein is mutated in nephropathic cystinosis. *Nat Genet* 1998;18:319-24.
- Wong VG, Lietman PS, Seegmiller JE. Alterations of pigment epithelium in cystinosis. *Arch Ophthalmol* 1967;77:361-9.
- Melles RB, Schneider JA, Rao NA, Katz B. Spatial and temporal sequence of corneal crystal deposition in nephropathic cystinosis. *Am J Ophthalmol* 1987;104:598-604.
- Nesterova G, Gahl WA. Cystinosis: The evolution of a treatable disease. *Pediatr Nephrol* 2013;28:51-9.
- Garibaldi DC, Gottsch J, de la Cruz Z, Haas M, Green WR. Immunotactoid keratopathy: A clinicopathologic case report and a review of reports of corneal involvement in systemic paraproteinemias. *Surv Ophthalmol* 2005;50:61-80.
- Kleta R, Blair SC, Bernardini I, Kaiser-Kupfer MI, Gahl WA. Keratopathy of multiple myeloma masquerading as corneal crystals of ocular cystinosis. *Mayo Clin Proc* 2004;79:410-2.
- Jones NP, Postlethwaite RJ, Noble JL. Clearance of corneal crystals in nephropathic cystinosis by topical cysteamine 0.5%. *Br J Ophthalmol* 1991;75:311-2.
- McDowell GA, Gahl WA, Stephenson LA, Schneider JA, Jean W, Polymeropoulos MH, *et al.* Linkage of the gene for cystinosis to markers on the short arm of chromosome 17. *Nat Genet* 1995;10:246-8.
- Kalatzis V, Antignac C. New aspects of the pathogenesis of cystinosis. *Pediatr Nephrol* 2003;18:207-15.
- Anikster Y, Shotelersuk V, Gahl WA. CTNS mutations in patients with cystinosis. *Hum Mutat* 1999;14:454-8.
- Hamroun D, Desmet FO, Lalande M. Human Splicing Finder Version 2.4.1; 2010. Available from: <http://www.umd.be/HSF/>. [Last cited on 2014 Jul 17].