

Coxsackie group B fatal neonatal myocarditis associated with cardiomegaly

R. C. JENNINGS

From the General Hospital, Altrincham, Cheshire

SYNOPSIS Most fatal cases of Coxsackie group B neonatal myocarditis have been associated with nursery epidemics. Occasional sporadic cases have been reported, mainly from the U.S.A., and a further case with gross cardiomegaly is described.

CASE REPORT

The deceased, a male child, the second son of a 17-year-old mother, was born in hospital on 31 October 1964. The pregnancy and labour were normal and the child made good progress during its one-week stay in hospital. He appeared to be thriving normally during his first week at home, but from 14 November onwards both of the parents thought that his breathing appeared rather rapid and a number of friends also commented upon this. When seen at a child welfare clinic on 24 November this was the only abnormality found on clinical examination. Arrangements were made for the child to be seen by a paediatrician the following day, but the child was found dead in bed the same night. Neither the mother nor the other 18-month-old child had been ill during this period.

NECROPSY FINDINGS (48 HOURS AFTER DEATH) The body was that of a normally developed, well-nourished male child, measuring 56 cm. in length. The trachea and bronchi contained a small amount of frothy mucus, both lungs showed a slight fibrinous exudate over the basal parts of the lower lobes, with a small amount of slightly turbid fluid in the pleural cavities. The basal parts of the lower lobes were slightly firmer than normal on section and paler in colour than the remainder of the lungs. There was a little excess of slightly turbid pericardial fluid and the heart was markedly enlarged (76 g.) due to thickening of the walls of both ventricles. The muscle was uniform in appearance on section, of normal consistency but browner than normal. There was no evidence of congenital heart disease. All other organs appeared normal.

HISTOLOGICAL EXAMINATION Inflammatory foci, consisting mainly of lymphocytes and mononuclear cells with some polymorphs, with associated muscle necrosis, were present throughout both ventricles, atria, and auricular appendages (Fig. 1). There was a pericarditis and some mural endocardial lesions. The lower lobes of both lungs showed an interstitial and intra-alveolar mononuclear

infiltrate. The upper lobes were normal. No inflammatory foci were evident in the remainder of the organs.

BACTERIOLOGICAL AND VIROLOGICAL EXAMINATION
Saprophytic organisms only were isolated from swabs

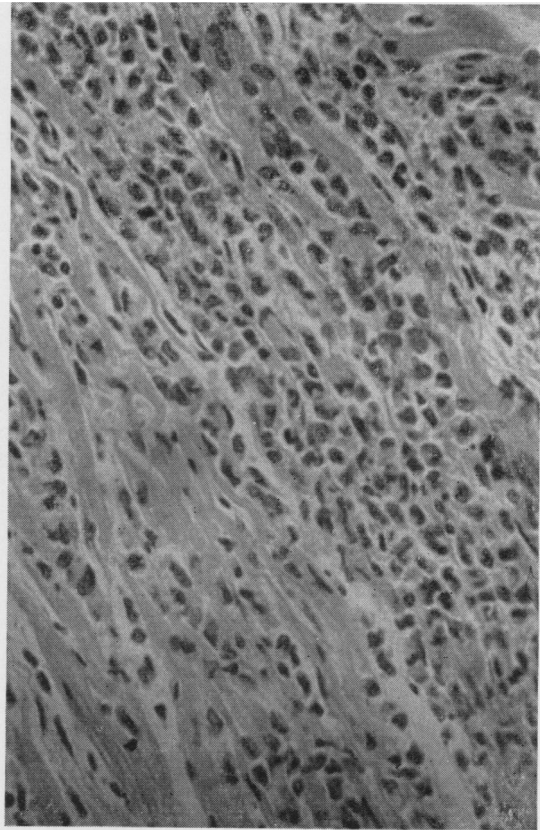


FIG. 1. *Left ventricle showing intense inflammatory infiltrate with muscle necrosis. Haematoxylin and eosin, $\times 400$.*

Received for publication 7 March 1966.

taken from the pleural cavities and lungs. A Coxsackie virus B type 5 was isolated from the contents of the small and large bowel. No virus was isolated from lung. No other specimens were examined. A Coxsackie B5 virus was isolated from the stool of the mother from a specimen taken three days after the death of the baby.

DISCUSSION

Coxsackie group B virus infections in adults and children are known to produce a wide range of clinical manifestations. These include pleurodynia, meningo-encephalitis, and benign pericarditis. These conditions are almost invariably associated with a favourable prognosis. In neonatal infection, however, the target organ most often involved is the heart and a fatal outcome is frequent. In older children and adults myocarditis is rarely recorded (Null and Castle, 1959; Connolly, 1961) and only one fatal case has been described (Sanyal, Mahdavy, Gabrielson, Vidone, and Browne, 1965). Most of the fatal cases of neonatal myocarditis reported have been associated with nursery epidemics. These have been fully described by Montgomery, Gear, Prinsloo, Kahn, and Kirsch (1955) in Southern Rhodesia, by Javett, Heymann, Mundel, Pepler, Lurie, Gear, Measroch, and Kirsch (1956) in South Africa, and by van Creveld and de Jager (1956) in Amsterdam. Sporadic fatal cases have been reported mainly from the U.S.A. (Kilbrick and Benirschke, 1956; Hosier and Newton, 1958; Fechner, Smith, and Middelkamp, 1963).

Infection occurs usually soon after birth but in some instances infection is intra-uterine and transplacental (Kilbrick and Benirschke, 1956). Not uncommonly there is a history of an acute illness in the mother, either before or shortly after birth (Robino, Perlman, Togo, and Reback, 1962). In the present case the mother reported no acute illness at the time, but a group B5 virus was isolated from her stool taken three days after the death of the child.

The affected infants usually present an acute fulminating illness with evidence of circulatory failure and respiratory distress. A tachypnoea out of proportion to the fever is a common finding. This in fact was the only clinical abnormality found in this case when the child was examined 15 hours before death.

Most of the necropsy reports stress the generalized nature of the infection, and, in addition to the myocarditis, necrotizing lesions may be found in the liver, adrenals, pancreas, and bone marrow. A meningoencephalitis has often been found to be present (van Creveld and de Jager, 1956; Robino *et al.*, 1962; McLean, Donohue, Snelling, and Wyllie, 1961). Simenhoff and Uys (1958) described a

fibrinous exudate of the peritoneal surface investing the liver as the second most common manifestation of Coxsackie virus infection in the neonate. This is not recorded by other writers and was not found in the present case.

The presence of cardiomegaly in Coxsackie myocarditis has been found in some cases (Saphir and Cohen, 1957; Hosier and Newton, 1958) but absent in others (Fechner *et al.*, 1963). It was the most dramatic finding at necropsy in the present case, the heart weighing four times the normal size. This is presumably a compensatory hypertrophy due to interference with normal function by widespread necrotic foci but the possibility of hyperplasia shortly before or after birth cannot be ruled out (Black-Schaffer and Turner, 1958).

The histological changes in the heart have to be distinguished from those of acute interstitial myocarditis. The presence of muscle necrosis is the hallmark of the virus myocarditis with a varying cellular exudate associated with the necrotic foci. An initial polymorphonuclear reaction followed by a predominantly mononuclear infiltration is found with fibroblastic repair at a later stage (Simenhoff and Uys, 1958). There is never any valvular endocarditis, but a mural endocarditis may occur (Sanyal *et al.*, 1965) with thrombi overlying areas of subendocardial necrosis. A pericarditis is often present and in the adult may be the only clinical evidence of Coxsackie virus infection.

The virus has been isolated at necropsy from a variety of sites, including the myocardium (Montgomery *et al.*, 1955), spinal cord (Kilbrick and Benirschke, 1956), liver and lung (McLean *et al.*, 1961), and faeces (Robino *et al.*, 1962). The accumulated evidence indicates that the heart muscle itself is the organ of choice for virus culture. All of the group B viruses have been isolated at one time or another from cases of neonatal myocarditis and none of the serological subgroups show any predominance.

There is some evidence to suggest that Coxsackie virus infections during pregnancy may have teratogenic effects (Evans and Brown, 1963). These writers found a slightly increased incidence of Coxsackie infection during pregnancy in women producing foetal abnormalities, compared with a control group. This possible hazard, together with the undoubted instances of direct transplacental foetal infection in the later stages of pregnancy, makes the diagnosis of this condition important, and, particularly so, with the possibility of the development of new antiviral agents (Hilleman, 1965).

I wish to thank Mr. J. F. Hibbert, H.M. Coroner for central Cheshire, for permission to publish details of the

necropsy findings, and Dr. J. O. H. Tobin, Director, Public Health Laboratory, Withington Hospital, Manchester, for the virological investigations.

REFERENCES

- Black-Schaffer, B., and Turner, M. E. (1958). *Amer. J. Path.*, **34**, 745.
 Connolly, J. H. (1961). *Brit. med. J.*, **1**, 877.
 Evans, T. N., and Brown, G. C. (1963). *Amer. J. Obstet. and Gynec.*, **87**, 749.
 Fechner, R. E., Smith, M. G., and Middelkamp, J. N. (1963). *Amer. J. Path.*, **42**, 493.
 Hilleman, M. R. (1965). *Amer. J. Med.*, **38**, 751.
 Hosier, D. M., and Newton, W. A., Jr. (1958). *Amer. J. Dis. Child.*, **96**, 251.
 Javett, S. N., Heymann, S., Mundel, B., Pepler, W. J., Lurie, H. I., Gear, J., Measroch, V., and Kirsch, Z. G. (1956). *J. Pediat.*, **48**, 1.
 Montgomery, J., Gear, J., Prinsloo, F. R., Kahn, M., and Kirsch, Z. G. (1955). *S. Afr. med. J.*, **29**, 608.
 Kilbrick, S., and Benirschke, K. (1956). *New Engl. J. Med.*, **255**, 883.
 McLean, D. M., Donohue, W. L., Snelling, C. E., and Wyllie, J. C. (1961). *Canad. med. Ass. J.*, **85**, 1046.
 Null, F. C., Jr., and Castle, C. H. (1959). *New Engl. J. Med.*, **261**, 937.
 Robino, G., Perlman, A., Togo, Y., and Reback, J. (1962). *J. Pediat.*, **61**, 911.
 Sanyal, S. K., Mahdavy, M., Gabrielson, M. O., Vidone, R. A., and Browne, M. J. (1965). *Pediatrics*, **35**, 36.
 Saphir, O., and Cohen, N. A. (1957). *Arch. Path.*, **64**, 446.
 Simenhoff, M. L., and Uys, C. J. (1958). *Med. Proc.*, **4**, 389.
 van Creveld, S., and de Jager, H. (1956). *Ann. paediat. (Basel)*, **187** 100.