

# Zahn's 'infarcts' of the liver

P. HORROCKS AND E. TAPP

*From the Department of Pathology, University of Manchester*

**SYNOPSIS** Three patients were found at necropsy to have Zahn's 'infarcts' of the liver. In one of these cases the 'infarct' merely showed severe centrilobular congestion. In the other two cases there was centrilobular necrosis, and in one of these early fibrosis was seen. Portal vein occlusion was present in all three cases and this had followed splenectomy in two of them. There was no evidence of hepatic artery or vein occlusion. Circulatory failure is considered to have played a part in the pathogenesis of the lesions.

Well-demarcated hyperaemic areas in the liver were first described by Zahn in 1898. He called them 'atrophische rothe Leberinfarcte' but noted that there was no histological evidence of necrosis of liver cells. Although Zahn associated the lesions with portal vein occlusion, the mechanism by which they are produced is still incompletely understood. Three examples of this condition seen recently at necropsy are described below and their aetiology and significance are discussed.

## CASE REPORTS

**CASE 1** In October 1965 a 62-year-old man was seen at the Manchester Royal Infirmary with a history of dysphagia and weight loss for seven months. Radiological examination showed an extensive carcinoma involving the lower half of the oesophagus. A transthoracic resection of the tumour was performed, with mobilization of the stomach and anastomosis of the stomach to the proximal oesophagus, during the course of which splenectomy became necessary. The patient had successive hypotensive episodes in the post-operative period and death occurred on the fourth day.

Necropsy was performed six hours after death. There was an early mediastinitis and bronchopneumonic consolidation of the right lower lobe. Other significant findings were confined to the liver and portal venous system. Externally the liver was generally pale but showed several large, dark red, sharply defined areas. On section these had the typical 'nutmeg' appearance normally associated with chronic venous congestion. In such areas, many large intrahepatic branches of the portal vein were occluded by thrombus. The splenic vein was also filled by thrombus which extended from the ligated splenic pedicle to the origin of the portal vein. No obstruction of the extrahepatic part of the portal vein was present and there was no abnormality of the hepatic artery or veins.

*Microscopy of liver* The pale areas in the liver showed considerable fatty change. In the dark red areas there was

generalized congestion of the sinusoids, most prominent in the centrilobular zones (Fig. 1). Liver parenchymal cells in the congested areas were shrunken and contained small amounts of lipofuscin pigment (Fig. 2). Several branches of the portal vein were occluded by organizing thrombus. The portal tracts were otherwise normal.

**CASE 2** A 70-year-old woman was seen during the following month complaining of constant epigastric pain of three weeks' duration. She was found to have an epigastric mass and a barium meal demonstrated a gastric carcinoma. A total gastric resection with oesophago-jejunostomy and splenectomy was carried out. Progress thereafter was at first good but 18 hours before death she became hypotensive and had signs suggesting peritonitis. She died on the sixth post-operative day.

At necropsy 36 hours after death localized peritonitis due to failure of the anastomosis was present. There was haemorrhage into the left adrenal gland. The remaining abnormalities were limited to the liver and portal venous system. The liver showed lesions similar to those described in case 1, but on section there was also thrombus in the larger branches of the portal vein supplying these areas. The splenic vein was filled by thrombus to its junction with the superior mesenteric vein. No lesions were found in the hepatic artery or veins.

*Microscopy of liver* There was marked fatty change in the uninvolved parts of the liver, which also showed the changes of mild chronic venous congestion. The dark red areas showed the same dilatation of sinusoids and shrunken parenchymal cells seen in case 1. In addition, however, in some parts of these areas there was much more severe congestion with necrosis of liver cells in the central parts of the lobules. There was an infiltration of polymorphonuclear leucocytes amongst the necrotic cells (Fig. 3). Surviving centrilobular parenchymal cells and Kupffer cells contained haemosiderin and lipofuscin pigment.

**CASE 3** An elderly man was admitted to the Manchester Royal Infirmary in January 1966 with three months' history of ankle swelling. He had severe congestive

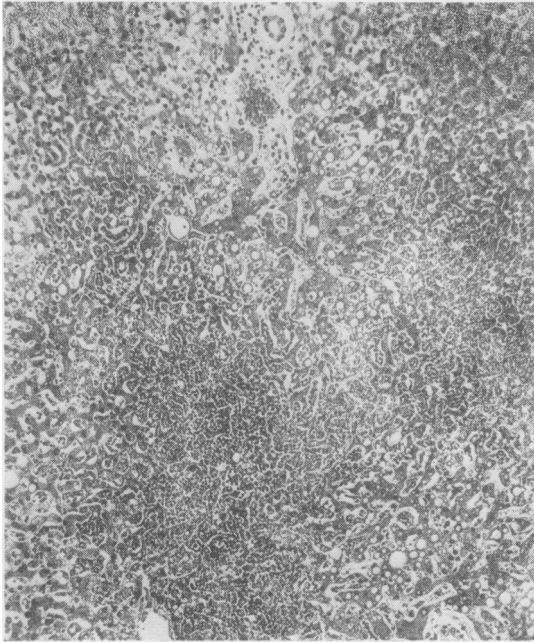


FIG. 1. There is marked congestion of the sinusoids in the centrilobular zones. Haematoxylin and eosin  $\times 90$ .

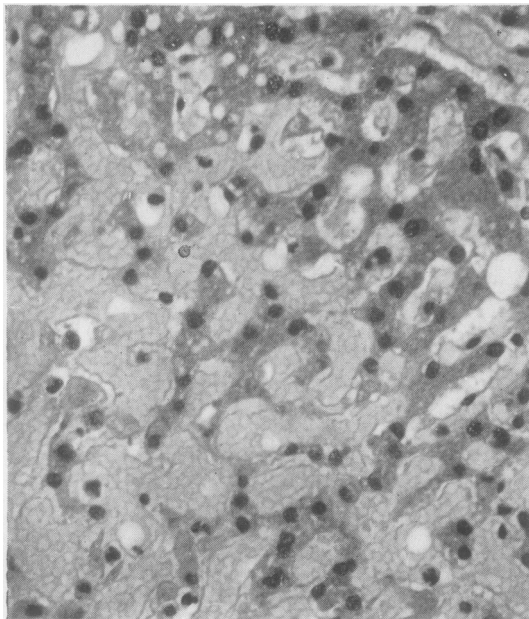


FIG. 2. The sinusoids are packed with red cells and the liver parenchymal cells are shrunken. These changes are most prominent towards the centre of the lobule (lower left side of photograph). Haematoxylin and eosin  $\times 360$ .

cardiac failure with massive oedema and ascites. A fairly good diuresis followed treatment but the ankle swelling persisted. Fourteen days after admission he suddenly collapsed and died.

Necropsy was performed 14 hours after death. Oedema was still present and there were effusions in the pleural, pericardial, and peritoneal cavities. The left coronary artery was partly occluded by atheroma with infarction of the wall of the left ventricle. The right lobe of the liver showed dark red areas, similar to those already described. At the hilum of the liver the portal vein and its right trunk were partially occluded by thrombus which was firmly adherent to the vessel wall (Fig. 4). The hepatic artery and veins were normal.

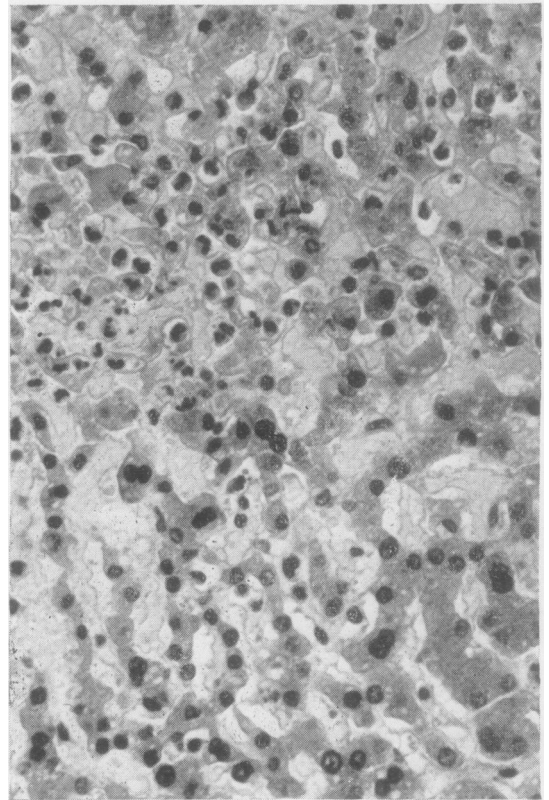


FIG. 3. There are many polymorphonuclear leucocytes amongst the necrotic liver parenchymal cells towards the centre of the lobule (upper left side of photograph). Haematoxylin and eosin  $\times 360$ .

*Microscopy of liver* Throughout the liver there were the changes of chronic venous congestion. In sections from the dark red areas, there was striking congestion of the inner parts of the lobules and the sinusoids were generally widened. In the central areas necrosis of parenchymal cells was present. Many of the necrotic cells had disappeared and in some places had been replaced

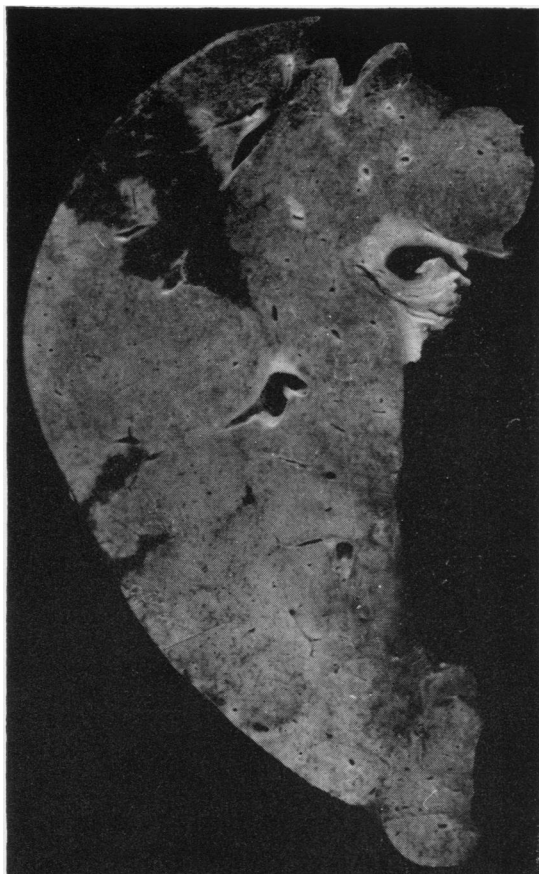


FIG. 4. *There is one large and two smaller dark-red areas in the liver. Thrombus can be seen in the right trunk of the portal vein (top right side of photograph).  $\times 0.5$ .*

by fibrous tissue. Polymorphonuclear leucocytes were not seen. There was proliferation of bile duct epithelium and spindle-shaped cells in the portal tracts.

#### DISCUSSION

The gross and histological appearances in the liver in all three cases are very similar, varying only in the degree of severity of the lesions. They all show extreme congestion of the sinusoids, most prominent at the centres of lobules, and atrophy of liver cells. In the most severely affected parts of the liver in cases 2 and 3, there is also necrosis of liver parenchymal cells. There is no evidence of necrosis of vessels and no resemblance to true infarction. The lesions are similar to those described by Zahn, with the additional feature of necrosis of the most severely affected liver cells. This point will be considered further when the pathogenesis of the lesions has been discussed.

The pathogenesis of Zahn's 'infarcts' has been the subject of considerable discussion in the past. Although the association with portal vein occlusion is well established the mechanism whereby this produces the lesions is not known. It seems probable, however, that an additional factor is required. Zahn (1897) recognized that the atrophy of the liver cells and the congestion of the sinusoids which followed portal vein occlusion only occurred in the presence of coincident arterial impairment and evidence has been put forward to support this by Popper and Schaffner (1957). There was no sign of atheroma, thrombosis, or embolism in the hepatic arteries in the present cases but there was systemic hypotension and anoxia which may well have similar effects. It is known that in dogs such conditions may cause constriction of the smooth muscle surrounding the hepatic veins and consequently venous congestion of the liver (Bauer, Dale, Poulsson, and Richards, 1932; MacLean, 1962). In addition a mechanism by which contraction of the larger hepatic veins in man can constrict the smaller tributaries to produce centrilobular stagnation has been described (Elias and Feller, 1931; Elias and Popper, 1955). The mechanism just suggested envisages an active obstruction to the venous drainage of the liver giving rise to the centrilobular congestion. An alternative theory has been put forward by Popper and Schaffner (1957). They suggest that there is passive stasis in the hepatic veins 'because of a lack of portal pressure after obstruction associated with a lowered hepatic artery pressure'.

The centrilobular necrosis in cases 2 and 3 is probably only a reflection of the severity of the centrilobular congestion in these cases and is comparable with that observed in severe chronic venous congestion. In case 3 there is evidence in the affected areas of progression to the type of fibrosis seen in longstanding congestive cardiac failure.

There is little evidence that portal vein occlusion alone will produce infarction although occasional cases have been reported (Zimmerman, 1930; Parker, 1955). In addition it has been suggested in a retrospective study (Woolling, Baggenstoss, and Weir, 1951) that portal vein occlusion combined with a general circulatory disturbance may cause infarction but there has been no general support for this theory.

In cases 1 and 2 the portal vein occlusion was due to embolism from thrombus in the splenic vein. In both these cases splenectomy had been performed during major surgical procedures, and the thrombus probably originated in the ligated splenic pedicle. This is a recognized complication of splenectomy in patients with a normal platelet count (Aird, 1949), and other factors, such as post-operative dehydra-

tion, increase the risk of thrombus formation. In case 2 the presence of local peritonitis may also have precipitated thrombosis. The cause of the portal vein thrombosis in case 3 is less clear. Stagnation of portal flow due to circulatory failure, dehydration from diuretic therapy, and a state of hypercoagulability evidence by deteriorating ischaemic heart disease might all have played a part.

Zahn's 'infarcts' do not appear to have specific clinical manifestations. Nevertheless the lesions had progressed to early fibrosis in case 3. Also, in the presence of severe hepatic arterial disease, portal vein occlusion identical with that seen in the cases described might result in catastrophic liver necrosis. An example of this was recorded by Losner, Volk, and Jacobi (1950). The risks of portal vein thrombosis

or embolism might be lessened by judicious anti-coagulant therapy, alterations of surgical technique, or attention to fluid balance.

## REFERENCES

- Aird, I. (1949). *A Companion in Surgical Studies*. Livingstone Edinburgh.
- Bauer, W., Dale, H. H., Poulsson, L. T., and Richards, D. W. (1932). *J. Physiol. (Lond.)*, **74**, 343.
- Elias, H., and Feller, A. (1931). *Z. ges. exp. Med.*, **77**, 538.
- and Popper, H. (1955). *Arch. Path.*, **59**, 332.
- Losner, S., Volk, B. N., and Jacobi, M. (1950). *Ibid.*, **49**, 461.
- MacLean, L. D. (1962). *Int. Abstr. Surg.*, **115**, 307.
- Parker, R. G. F. (1955). *J. Path. Bact.*, **70**, 521.
- Popper, H., and Schaffner, F. (1957). *Liver. Structure and Function*. McGraw-Hill, New York.
- Woolling, K. R., Baggenstoss, A. H., and Weir, J. F. (1951). *Gastroenterology*, **17**, 479.
- Zahn, F. W. (1897). *Verh. Dtsch. Naturf. Aertze*, **2**, 9.
- Zimmerman, H. M. (1930). *Arch. Path.*, **10**, 66.