



## Case Illustrated

## Disseminated cutaneous infection due to *Mycobacterium chelonae* following hematopoietic stem cell transplantation



C. Ferry<sup>a,\*</sup>, A. Saussine<sup>b</sup>, J.D. Bouaziz<sup>b</sup>, A. Xhaard<sup>a</sup>, R. Peffault de Latour<sup>a</sup>, P. Ribaud<sup>a</sup>, M. Robin<sup>a</sup>, E. Cambau<sup>c</sup>, G. Socié<sup>a</sup>

<sup>a</sup> Service hématologie greffe, AP-HP, Hôpital Saint-Louis, 1 avenue Claude Vellefaux, 75475 Paris Cedex 10, France

<sup>b</sup> Service de dermatologie, AP-HP, Hôpital Saint-Louis, 1 avenue Claude Vellefaux, 75475 Paris Cedex 10, France

<sup>c</sup> Département de bactériologie-virologie groupe hospitalier Lariboisière-Fernand Widal, Paris, France

## ARTICLE INFO

## Article history:

Received 29 June 2014

Accepted 2 July 2014

## Keywords:

*Mycobacterium chelonae*

Hematopoietic stem cell transplantation

Chronic graft versus host disease

## ABSTRACT

This report describes two cases of disseminated cutaneous *Mycobacterium chelonae* after hematopoietic stem cell transplantation (HSCT).

© 2014 Published by Elsevier Ltd. This is an open access article under the CC BY-NC-ND license (<http://creativecommons.org/licenses/by-nc-nd/3.0/>).

This report describes two cases of disseminated cutaneous *Mycobacterium chelonae* after hematopoietic stem cell transplantation (HSCT).

Both patients were 57-years-old and received an unrelated peripheral HSCT for malignant hematologic disease (follicular lymphoma and myelofibrosis). Both developed chronic graft-versus-host-disease (cGVHD) and received prolonged systemic steroids. They subsequently developed multiple erythematous subcutaneous nodules on legs and arms (eleven months after transplantation for patient #1 and eighteen months for patient #2; Fig. 1). Biopsies of subcutaneous nodules revealed a septal panniculitis with granulomatous components. The Ziehl-Neelsen stain (Fig. 2) was positive and culture identified *M. chelonae*. Hemocultures were negative.

Patient #1 was treated with a combination of clarithromycin, tobramycin and tigecycline. The nodules rapidly decreased. However he died three months later of cardiac failure in a context of uncontrolled cGVHD and *Enterococcus faecium* sepsis. Patient #2 responded well to treatment with azithromycin, imipenem and tobramycin was then given azithromycin alone.

*M. chelonae* is a rapidly growing non-tuberculous mycobacteria isolated from various environmental sources. Water is a major

source of contamination. *M. chelonae* infections are usually described in the setting of immunosuppression and particularly in patients receiving steroids therapy. After HSCT, *M. chelonae* infections are mostly due to central venous catheters or pulmonary infections, and skin involvement has not yet been described in previous reports.

In our two patients, prolonged steroid therapy led to skin atrophy with multiple lesions on limbs. Microbiological analyses of water of one hospital were performed and were positive for *M. chelonae*. As none of the patients had signs of disseminated infection, it can therefore be hypothesized

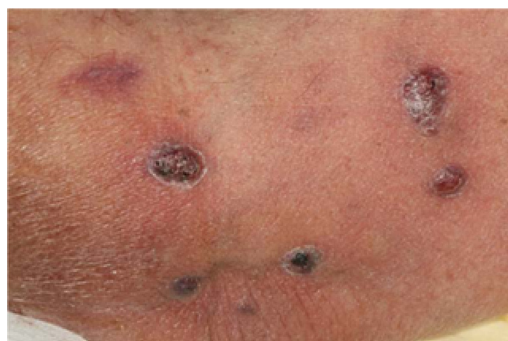

Fig. 1.

\* Corresponding author. Tel.: +33 1 40 50 59 82; fax: +33 1 40 50 53 34.  
E-mail address: [christele.ferry@fsef.net](mailto:christele.ferry@fsef.net) (C. Ferry).

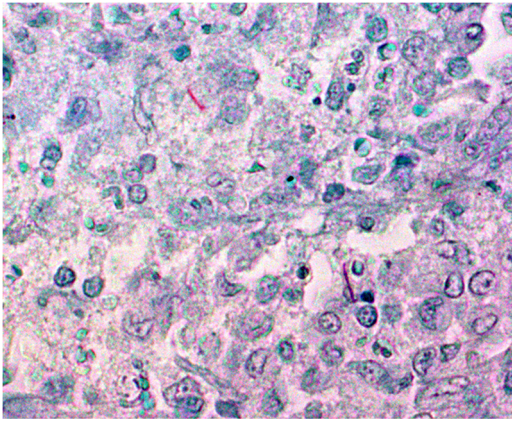


Fig. 2.

that a possible source of contamination in our patients was tap water used for washing.

In conclusion, cutaneous *M. chelonae* infection should be suspected in HSCT recipients developing isolated subcutaneous nodules in the context of cGVHD.

**Conflict of interest**

None.

**Author contributions**

All authors have contributed equally to the manuscript.