

# Mitral stenosis together with a giant cell myocarditis limited to the left atrium

I. GILLIE AND H. FOX

*From the Department of Pathology, Manchester University*

**SYNOPSIS** A case is described in which mitral stenosis was associated with a giant cell myocarditis; the latter lesion was, however, localized to the left atrium. A quite high proportion of reported cases of giant cell myocarditis have occurred in association with rheumatic heart disease. The nature of this relationship is discussed and it is concluded that, in such cases, the giant cell reaction may represent an unusual myocardial response to rheumatic fever.

Recently there have been two reports of giant cell myocarditis found in left atrial appendage biopsy specimens taken during mitral valvotomy (McCrea and Childers, 1964; Husband and Lannigan, 1965). A similar case is described in this paper in which, however, necropsy examination showed the unique feature of a giant cell myocarditis confined to the left atrium.

## CASE REPORT

In August 1967 a 60-year-old widow was admitted to Manchester Royal Infirmary for mitral valvotomy. She had a history of rheumatic fever 15 years previously. Mitral stenosis and aortic incompetence were first diagnosed four years later in 1956. In 1958 she developed paroxysmal nocturnal dyspnoea and atrial fibrillation and since that time her disease ran a steady downhill course. In 1963 there was one clinical episode of systemic embolism in the left popliteal artery which recovered with conservative treatment. On admission her temperature was 97.5°F, WBC 8,300, Hb 11.7 g/100 ml (80%), and her ESR (Wintrobe) was 27 mm/hr. Following the usual preoperative procedures a routine mitral valvotomy had been performed, during the course of which a left atrial appendage biopsy specimen was taken. Shortly after her return to the ward she collapsed and, despite resuscitatory attempts, died.

## ATRIAL APPENDAGE BIOPSY

The appendage appeared normal macroscopically and the lumen was free of thrombus. Histologically there was widespread patchy myocardial necrosis with a well-marked interstitial lymphocytic infiltration of the myocardium. In many areas interstitial

granulomata were also present in which lymphocytes, macrophages, many Langhans type giant cells, and occasional foreign body type giant cells were seen. There was no caseation and there were no Aschoff bodies or Anitschkow myocytes, but occasional cells were seen whose appearance suggested that they were myocardial cells in the process of transformation into giant cells. The surviving myocardial fibres were hypertrophied. The pericardium was normal but the endocardium showed a little fibrous thickening.

## NECROPSY

The body was that of a small, thin, elderly white woman. The heart was enlarged and weighed 390 g. The left atrial appendicular incision and the left ventriculotomy incision were well sutured. The ventricles were hypertrophied (the right ventricular wall measured 13 mm and the left 17 mm), but not dilated whilst both atria were greatly dilated but not hypertrophied. The mitral valve, which showed the typical macroscopic appearance of rheumatic stenosis, had been split so that it admitted the tips of two fingers. It was diffusely thickened up to 5 mm. The chordae tendinae were thickened and shortened. The aortic valve was thickened, up to 2 mm, and there were adhesions at the anterolateral commissure. The tricuspid and pulmonary valves were normal. The myocardium was macroscopically normal. The coronary arteries showed a trivial degree of non-stenosing atheroma. The right lung weighed 450 g and the left 280 g. The pulmonary arteries showed a moderate degree of atheroma. There were small old infarcts in the spleen, brain, and kidneys but otherwise all organs appeared normal.

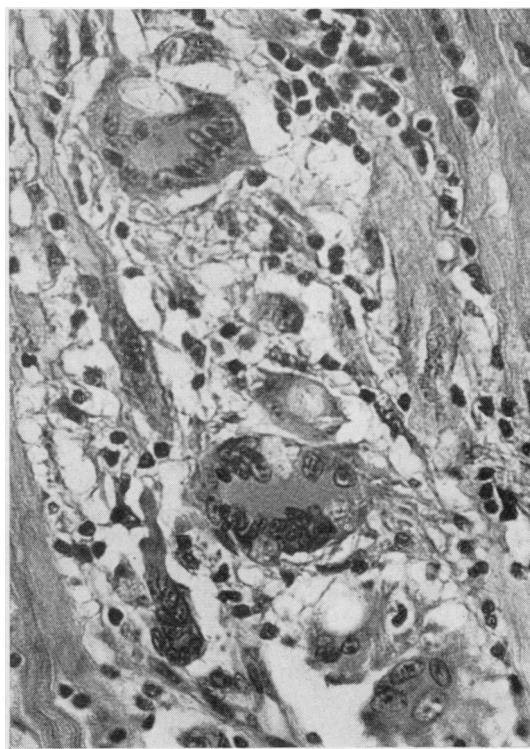
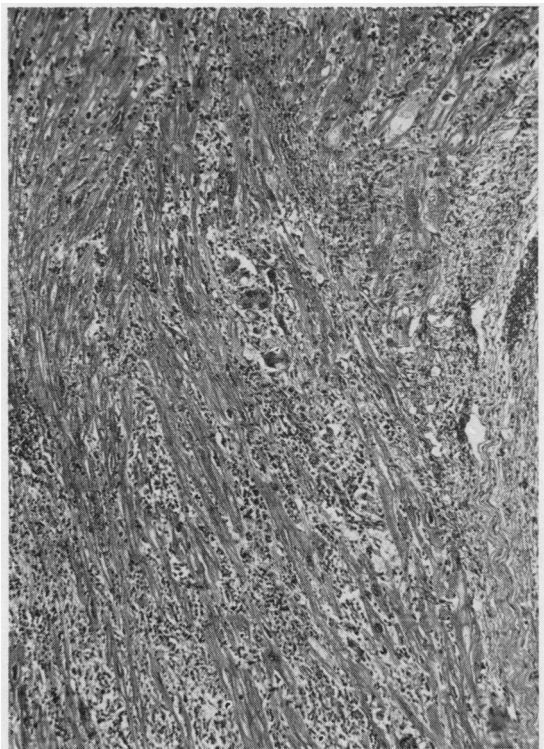


FIG. 1.

FIG. 1. Low-power view of atrial appendage biopsy showing granulomatous lesions. (H and E  $\times 70$ .)

FIG. 2.

FIG. 2. Higher power view showing giant cells. (H and E  $\times 400$ .)

Multiple blocks from the myocardium were studied histologically but only in those from the left atrium were changes similar to those in the appendicular biopsy seen. The giant cell granulomata were most numerous in that part of the atrium immediately adjacent to the atrial appendage and became fewer and smaller as the A-V ring was approached. In the ventricles, right atrium, and interventricular septum multiple blocks failed to reveal any evidence at all of an inflammatory lesion in the myocardium. No evidence of active rheumatism was seen but the mitral and aortic valves showed a diffuse fibrous thickening with hyalinization and occasional calcification in which no inflammatory cells were present.

The lungs showed some degree of alveolar wall fibrous thickening but were otherwise normal. There were no granulomatous lesions in any organ outside of the heart.

#### DISCUSSION

Giant cell myocarditis is rare; the cause is, in most

cases, unknown but a wide variety of possible aetiological factors have been suggested; these include viral or fungal infections, brucellosis, toxoplasmosis, tuberculosis, sarcoidosis, syphilis, vitamin deficiencies, coronary artery disease, amyloidosis, and hypersensitivity reactions (Kean and Hoekenga, 1952; Zschoch, 1961; McCrea and Childers, 1964; Whitehead, 1965; O'Donnell and Mann, 1966). Certainly the cardiac disease has, in many of the reported cases, been only a local manifestation of a generalized granulomatous disease insofar as granulomata were also present in the lungs and other organs (Tesluk, 1956; Long, 1961; O'Donnell and Mann, 1966). Heart lesions may occur in Wegener's granulomatosis (McCrea and Childers, 1964), whilst cardiac involvement in generalized sarcoidosis is well documented (Porter, 1960; Phinney, 1961; Forbes and Usher, 1962), sufficiently so to have led to the suggestion that all cases of isolated giant cell myocarditis are examples of localized sarcoid (Rab, Choudhury, and Choudhury, 1963; Johansen, 1966).

Considering the rarity of giant cell myocarditis

a surprisingly high proportion of the recorded cases have occurred in association with apparent rheumatic heart disease. Thorbjarnarson and Glenn (1956) reported a patient with chronic rheumatic heart disease who died during mitral valvotomy; at necropsy the presence of rheumatic disease was confirmed by the finding of Aschoff bodies in the heart, but a giant cell myocarditis was also present. Zschoch (1961) described a 15-year-old boy with a six-year history of rheumatic heart disease who died during an apparent reactivation of rheumatic fever; necropsy examination showed typical rheumatic disease of the aortic and mitral valves together with a widespread giant cell myocarditis. In recent years there have been reports of four cases in which giant cell granulomata were found in left atrial appendages removed during mitral valvotomy (McCrea and Childers, 1964; Husband and Lannigan, 1965); in these cases, only the left atrial appendage was available for study but it was assumed that the findings in this site reflected those elsewhere in the heart and this led to the suggestion that the valvular lesions were possibly not rheumatic but were related to the giant cell myocarditis (Husband and Lannigan, 1965).

The case described in this paper indicates, however, that the presence of giant cell granulomata in the atrial appendage cannot necessarily be taken as evidence of generalized myocardial disease, for in this case there was a striking localization to the left atrium. Nevertheless, there does appear to be a real, though rare, association between mitral stenosis and left atrial giant cell lesions. There are several possible explanations for this apparent relationship. First, it is possible that the granulomatous disease causes the valve lesions, and, to some extent, this theory is supported by the finding of fibrous thickening of the aortic and mitral valves in a case of giant cell myocarditis associated with extracardiac granulomata of unknown aetiology (O'Donnell and Mann, 1966). Against the hypothesis is the fact that granulomatous lesions have never been recorded in the affected valves and the presence, in the present case, of aortic valve disease despite the localization of the giant cell lesions to the left atrium. It is more probable, therefore, that the giant cell lesions are associated with true rheumatic heart disease. It could, however, be suggested that the association is coincidental and that any stress laid on a cardiac chamber, *eg*, on the left atrium in mitral stenosis,

may result in myocardial damage with a resulting non-specific giant cell reaction. That a giant cell reaction may simply be a result of non-specific muscle stress or damage is supported by the finding of a giant cell myocarditis limited to a left ventricular aneurysm (Zeeman, Templeton, Goldburgh, and Aponte, 1962) and by the observed transition of damaged myocardial cells into giant cells (Parrish, 1965). If, however, the giant cell reaction is simply a non-specific response to muscle stress the finding of similar lesions in the left ventricular myocardium of hypertensive patients would be expected and such a finding has not been reported. It is also possible that the stress exerted on the left atrium in cases of mitral stenosis predisposes to the localization of a hypothetical virus in that site but there is little evidence to support this suggestion. Hence, the most probable explanation of the association between mitral stenosis and giant cell myocarditis is that the latter is, in such cases, an unusual histological manifestation of rheumatic myocarditis. This being so, the localization of the lesions in the left atrium would not be unexpected insofar as this is the optimal site for the finding of typical rheumatic lesions, *ie*, Aschoff bodies. This is not to suggest, of course, that all cases of giant cell myocarditis are of rheumatic origin but rather that this type of lesion is a non-specific response to many factors, one of which is possibly rheumatic fever.

We wish to thank Mr H. F. M. Bassett for the clinical details, Professor A. C. P. Campbell in whose department this work was done, Miss L. Partington who typed the manuscript, and Mr G. Humberstone for the photomicrographs.

#### REFERENCES

- Forbes, G., and Usher, A. (1962). *Brit. med. J.*, 2, 771.  
 Husband, E. M., and Lannigan, R. (1965). *Brit. Heart J.*, 27, 269.  
 Johansen, A. (1966). *Acta path. microbiol. scand.*, 67, 15.  
 Kean, B. H., and Hoekenga, M. T. (1952). *Amer. J. Path.*, 28, 1095.  
 Long, W. H. (1961). *J. Amer. med. Ass.*, 177, 184.  
 McCrea, P. C., and Childers, R. W. (1964). *Brit. Heart J.*, 26, 490.  
 O'Donnell, W. M., and Mann, R. H. (1966). *Amer. Heart J.*, 72, 686.  
 Parrish, J. A. (1965). *Brit. Heart J.*, 27, 458.  
 Phinney, A. O., Jr (1961). *Amer. Heart J.*, 62, 270.  
 Porter, G. H. (1960). *New Engl. J. Med.*, 263, 1350.  
 Rab, S. M., Choudhury, G. M., and Choudhury, A. R. (1963). *Lancet*, 2, 172.  
 Tesluk, H. (1956). *Amer. J. clin. Path.*, 26, 1326.  
 Thorbjarnarson, B., and Glenn, F. (1956). *Arch. Surg.*, 73, 862.  
 Whitehead, R., Jr (1965). *Brit. Heart J.*, 27, 220.  
 Zeeman, S. E., Templeton, J. Y., Goldburgh, W. P., and Aponte, G. (1962). *Amer. Heart J.*, 63, 270.  
 Zschoch, H. (1961). *Zbl. allg. Path. Anat.*, 102, 132.