

Generalized herpes simplex in malnourished children

A. C. TEMPLETON

From the Department of Pathology, Makerere University College, Kampala, Uganda

SYNOPSIS Five cases of fatal generalized herpes simplex infection in malnourished children are described. This is almost certainly a much more common disease in underdeveloped communities than is at present appreciated. Only a greater awareness of the disease, coupled with full use of histological and cultural methods of diagnosis, will lead to knowledge of its true frequency.

A case of neonatal infection, the first recorded in an African, is also described. Reasons are suggested as to why this disease should be seen in malnourished infants in Africa but only very rarely in neonates.

Although infection with herpes simplex virus is very common, fatal generalized disease is apparently a rare phenomenon, and the first description of a case is usually accredited to Hass (1935). In cases reported from Europe and America it has occurred most frequently in the neonatal period, but in a few instances older children have been affected (Zuelzer and Stuhlberg, 1952). In Africa, however, most cases seem to occur in children between the ages of 2 and 26 months, and are most frequently associated with kwashiorkor or other forms of malnutrition. Many of these children have also had some other viral infection, such as measles, in the recent past. McKenzie and his coworkers (Becker, Naudé, Kipps, and MacKenzie, 1963; Kipps, Becker, Wainwright, and MacKenzie, 1967) have seen many cases at necropsy in Durban and Cape Town and state

that this disease has been seen frequently by their colleagues in South Africa. They record that generalized herpes in association with measles has been noted in Dakar, Senegal, but apparently not elsewhere. The South African group express the view 'we do not believe that these are the only cities where this disease is to be found'. Six cases seen in Kampala, Uganda, are here recorded.

Materials and Methods

A case of generalized herpes virus infection (case 6) was seen at necropsy at Mulago Hospital, Kampala, in March 1968. The diagnosis was confirmed by virus isolation. Since the histological features of the disease are often sufficiently

distinctive to make a firm diagnosis without culture, a search was made of the records of post-mortem examinations performed in the Department of Pathology, Makerere University Medical School, from 1962 to 1967. A total of 5,300 case reports was scrutinized and any in which necrosis of, or haemorrhage into, the liver or adrenal was mentioned, were re-examined. Fresh slides from these cases were cut and stained with haematoxylin and eosin, PAS, Feulgen, and methyl green pyronin methods. In those cases in which a firm diagnosis was possible, the clinical notes were examined. A total of six cases was found by these means.

Case Reports

Brief details of the history and findings at necropsy are given below.

CASE 1

A 4-year-old African male child was admitted with a history of two weeks' generalized oedema. On examination he was noted to have the classical signs of kwashiorkor. Haemoglobin on admission was noted as 9.2g%. He was treated with a special diet rich in protein. He appeared to be improving but after three weeks in hospital suddenly developed a sore mouth which was followed two days later by a generalized skin rash which appeared vesicular. He developed a high temperature and signs of pneumonia were noted and the haemoglobin had fallen to 6.0g%. He died two days later.

Postmortem examination showed an undernourished child with generalized oedema. A large number of small round ulcers were seen on arms, legs, scalp, and back. These were mostly located in the flexures. Ulcers were also found in the mouth and throat. Numerous small ulcers were seen in the small and large intestines but all the other organs were as usually found in a child with kwashiorkor. Microscopy showed typical lesions of herpes simplex in the mouth, tongue, small and large intestines and in the liver, spleen, and adrenals. The lungs showed the changes of bronchopneumonia. The brain was essentially normal.

CASE 2

An 18-month-old male infant from Burundi was admitted with severe kwashiorkor. He was noted to have generalized oedema and skin rash with ulceration, most marked in the flexures. His mouth was noted to be sore and after three days in hospital he was found to have ulcers on the lips and tongue. On the fourth hospital day, the temperature rose to 103°F and he had a convulsion; lumbar puncture was done and the cerebro-

spinal fluid was normal. The child died the next day.

At necropsy, the skin rash was found to have healed but ulcers were noted on the lips and tongue. The liver was pale and greasy and numerous small haemorrhages were seen under the capsule. Other organs appeared macroscopically normal. Microscopically typical lesions were found in the mouth and liver. The brain, lungs, and adrenal were normal.

CASE 3

A 20-month-old Banyaruanda child was admitted with signs of kwashiorkor. Three months previously he had been treated in hospital for kwashiorkor and hookworm anaemia. He was treated with a high-protein diet and oral iron and appeared to be improving. On the eighth day in hospital he became dyspnoeic and developed a cough; tuberculosis was suspected and the child was started on antituberculous therapy. The next day a vesicular rash developed in the groin and rapidly spread to involve the rest of the body. This was clinically diagnosed as chickenpox. The child died two days later as a result of pneumonia.

At necropsy the rash was found to be resolving but ulcers were noted in the mouth and throat. The lungs showed extensive tuberculosis and the liver contained fat. Microscopically, lesions highly suggestive of herpes simplex were found in the mouth, lung, liver, spleen, and adrenal. Extensive non-reactive caseating tuberculous bronchopneumonia was seen although organisms were scanty.

CASE 4

A 7-day-old Batoro infant, who had been born at home, was admitted with a history of two days of vomiting of blood and convulsions. The child died shortly after admission.

At necropsy there was no skin rash. Numerous small haemorrhages were found in the liver, kidney, bowel, and lung. A presumptive diagnosis of thrombocytopenia was made on the macroscopic appearances. In addition to the petechiae, ring-like haemorrhages, 3 or 4 mm in diameter, were noted under the capsule of the liver. Microscopically, areas of necrosis surrounded by cells containing the typical inclusions of herpes simplex were found in the liver parenchyma. The adrenals and spleen showed essentially similar lesions scattered through their substance. Petechial haemorrhages were seen in these organs, and also in the lung, bowel, and kidney.

CASE 5

A 12-month-old female Banyaruanda infant was admitted with severe kwashiorkor. On examination the child was pyrexial (100°F) and signs of bron-

chopneumonia were present. A few hours after admission the child had a convulsion and lumbar puncture showed a normal cerebrospinal fluid. She died two days later as a result of the pneumonia.

At necropsy no ulcers were found on the skin or in the mouth. The lungs showed extensive bronchitis and bronchopneumonia. The liver was fatty and pale in colour, and numerous small circular haemorrhages were seen on the cut surface. Microscopic examination showed inhalation pneumonia with no evidence of viral infection. The brain appeared normal but characteristic patches of necrosis were found in liver and adrenal.

CASE 6

A 14-month-old Ankole female infant was admitted with signs of kwashiorkor. She had numer-

ous ulcers all over the skin which had been present for two months. These were found mainly in the flexures of the groin, knee, and elbow. On admission the child was irritable and apathetic. Haemoglobin was 8.0g% and blood glucose was 100 mg%. During the next three days the rash became more ulcerated and on the sixth hospital day she had a convulsion. Lumbar puncture showed a normal cerebrospinal fluid and the blood glucose level was 19 mg%. The child died shortly afterwards.

At necropsy there were huge numbers of ulcers of the skin, most marked in the flexures, but no lesions were found in the mouth or pharynx. Culture of the skin ulcers grew a mixed bacterial flora, including staphylococci and *E. coli*. The brain appeared normal. The lungs were consolidated and the bronchi injected. The bowel appeared normal. The liver was generally pale and fatty but showed innumerable small circular haemorrhages throughout the parenchyma but best seen under the capsule. Minute spots could be seen in the cortex of the adrenals but other organs appeared normal. A portion of liver grew herpes simplex virus in tissue culture.

Microscopically typical necrotic lesions were seen in the liver and adrenal. The lung showed bronchopneumonia with none of the stigmata of viral infection. The spleen appeared normal. The skin rash was difficult to interpret because of the secondary infection but in a biopsy from the flexure of the elbow a few inclusion bodies were seen in the margin of an ulcer. The brain appeared normal microscopically, apart from minor changes in the neurones suggestive of hypoglycaemia, which was presumed to be a result of the extensive hepatic necrosis.

Microscopical Appearances

Histological diagnosis in generalized herpes simplex is usually straightforward. The organs frequently affected are the liver and adrenal though necrotic areas in the adrenal may be small and few in number (Fig. 1). The cortex is affected exclusively and the medulla is always normal. The areas of necrosis are spherical and seem to spare the outermost and innermost zones of the cortex. It is in the liver, however, that the most characteristic changes are seen. Macroscopically the capsular surface and cross sections of the organ show innumerable, tiny, whitish spheres each surrounded by a 'halo' of haemorrhage (Fig. 2). In kwashiorkor, when the remaining liver cells are distended with fat, the appearance is very striking. Microscopically these areas show a central zone of complete necrosis surrounded by an area in which the cells show the various stages of infection by herpes virus. Surrounding this is a zone of dilated vessels and extruded red cells; the absence of inflammatory

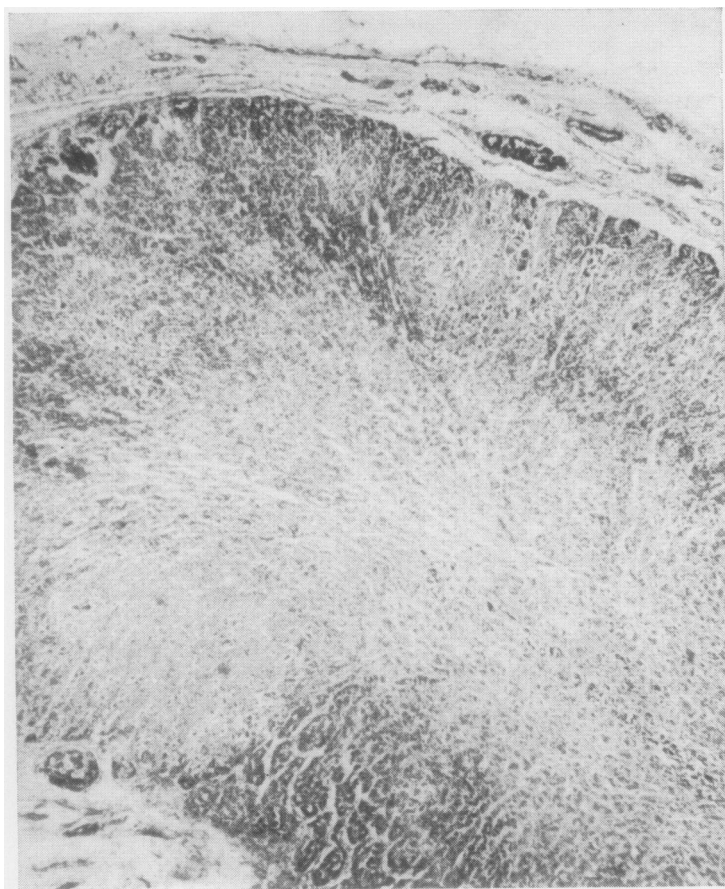


Fig. 1 Section of the adrenal (case 4) to show rounded areas of necrosis in the cortex (haematoxylin and eosin, $\times 50$).

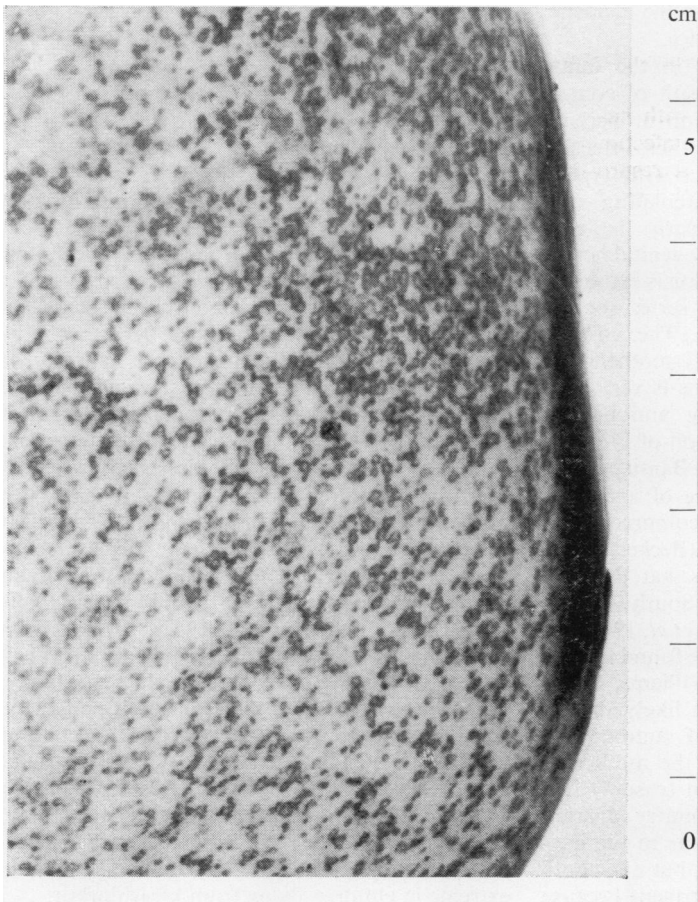

Fig. 2 Surface of the liver (case 6) showing how sharply the areas of necrosis and haemorrhage stand out in the fatty background ($\times 1.6$).

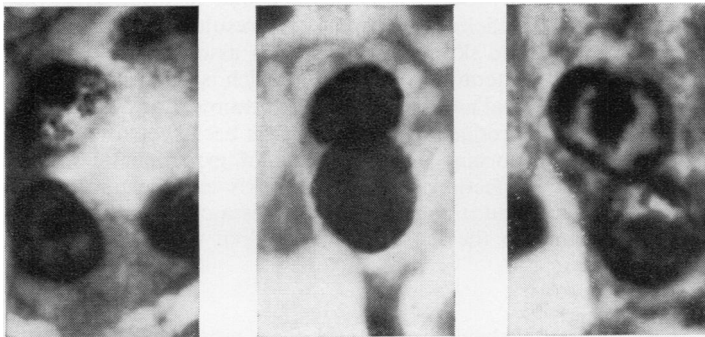


Fig. 3 Liver cells illustrating the development of the inclusion body: (left) a large nucleolus and B bodies; (centre) two nuclei filled with homogeneous A bodies; (right) the shrunken eosinophilic inclusion surrounded by clumped chromatin (H and E, $\times 1,200$).

cells in all areas is a striking feature. These patches of necrosis do not bear any constant relationship to the liver lobule. In the older children, the size of each area was considerably smaller than in the neonatal case and the descriptions and illustrations in published reports indicate that this is generally true. The characteristic feature of this infection is the change which occurs in the nuclei with the formation of an inclusion body. Similar changes take place in the nuclei of cells from different tissues from different species so that it is a property of the virus rather than the host cells that determines their formation. Most of the descriptions of the development and histochemistry of the changes in the nucleus have been on cells of tissue culture or eggs. However, the same changes may be seen in post-mortem material using haematoxylin and eosin, Feulgen, and methyl green pyronin stains (Fig. 3).

The first change noted is an enlargement of the nucleoli. In tissue culture, this has been shown to occur within 30 minutes of infection by virus (Love and Wildy, 1963). A little later, small, dark, circumscribed B bodies may be seen in the nucleoplasm, and these stain positively with haematoxylin and methyl green but not with Feulgen. After a few hours, large masses develop and coalesce until they entirely fill the nucleus (A bodies). These A bodies stain positively with both Feulgen and haematoxylin at first but as they become older they lose their affinity for both these stains and, becoming smaller, tend to shrink away from the nuclear membrane, eventually showing all the characteristics of the central eosinophilic Cowdry type A inclusions. During the early stage of the development of the A body, the B bodies migrate to the edge of the nucleus and on rare occasions may be seen in the cytoplasm of the cell. As the development of these inclusion bodies progresses, the nucleoli disappear and the chromatin material of the nucleus becomes progressively more clumped and is arranged around the periphery of the nucleus. Giant cell formation is rarely observed in the liver but appears more commonly in the adrenal cortex.

Epidemiology

It has recently been shown that two distinct antigenic types of herpes simplex virus exist: type 2 includes most of the viruses producing genital infections (Dowdle, Nahmias, Harwell, and Pauls, 1967) and type 1 produces many of the cases of herpes labialis. Serum raised against type 1 strain only partially neutralizes type 2 virus; this fact explains the apparent anomaly of neonatal herpes infection occurring in infants with circulating antibody. Most surveys of the incidence of herpes infection have been conducted using type 1 strains and serum, so that very little

information is as yet available as to the incidence of type 2 strains, especially in Africa.

Neonatal infection may occur in the infant of a non-immune mother as a result of contact with a person with herpes infection or perhaps from a primary infection in the mother. Infection may occur as a result of contact with type 2 strain even if the mother has circulating anti-type 1 antibody. This is particularly liable to happen if the mother has a primary genital herpes infection. In Africa neonatal infection is extremely rare, in fact case 4 in the present series appears to be the first recorded instance. The possible explanations of this are that all mothers are immune or that the causative virus is very rare. Coetsee (1955) found circulating antibody in 100% of the adult Bantu population of Pretoria. A survey in Cape Town showed the Bantu population to have the highest incidence of antibody, the white the lowest, and the Cape coloured group occupied an intermediate position (Becker, 1966). It is therefore of interest to note that the only fatal neonatal case seen by the South African workers was a white infant (Kipps *et al*, 1967). In Kampala 126 out of 130 adults were found to have circulating antibody (Woodall, Williams, Simpson, and Haddow, 1965) but it is likely that in rural districts the prevalence of antibody is lower; it may be significant that the mother of the infant with neonatal infection (case 4) had only recently arrived from a country district. There is no information available as to the incidence of type 2 strains in Uganda, but one could perhaps infer that they are not frequent because of the paucity of generalized disease in neonates. The rarity of neonatal infection with type 1 strains is probably a result of the universal presence of antibody in the adult population which would ensure protection during the early weeks of life.

In South Africa the incidence of fatal generalized herpes seems to be higher than elsewhere and it is interesting to speculate why this should be. It is possible that different strains of virus occur in these areas but experience suggests that this is not so (Becker *et al*, 1963). In Durban 38 cases of the disease were found in two years during which time 'well over a thousand postmortems were performed each year' (Kipps *et al*, 1967). In Kampala only six were found in a total of 5,300 necropsies. Although it is possible that cases were missed in Kampala the difference is a striking one. The Bantu population of Durban is urbanized and children tend to live with their parents in the town. In Kampala it is usual to send children home to the family shamba where they remain until they go to school, by which time malnutrition is no longer a problem. The only families actually living in crowded circumstances in the town are recent immigrants. It is of interest therefore that all five children with infection associated with malnutrition came from immigrant families and none were of the indigen-

ous Baganda tribe who show just as high an incidence of kwashiorkor.

Relation to Malnutrition

Infection with herpes simplex virus is an extremely common event. It has been estimated that 90% of infections are subclinical (Scott, 1957). Although viraemia occurring at the time of primary infection has only rarely been demonstrated (Dudgeon, 1950); Ruchman and Dodd, 1950), it probably occurs quite frequently. In the vast majority of cases this is of no significance apart from producing a transient malaise, but in some circumstances viraemia progresses to fatal generalized infection. Since the majority of such cases occur in malnourished children and neonates it has been assumed that there is some form of deficient immunological response in these subjects. Antibody production, serum levels of antibody, and turnover rates appear to be normal in kwashiorkor (Cohen and Hansen, 1962). It has been stated that interferon production is normal (WHO Expert Committee, 1965). It would seem likely, therefore, that delayed hypersensitivity might be deficient in same way. In support of this concept reaction to BCG is frequently defective (Harland and Brown, 1965) and Mantoux testing is unreliable in malnourished children (Lloyd, 1968). These reactions are mediated by thymic-dependent lymphocytes and certainly thymic atrophy is extreme in children dying from kwashiorkor.

In some cases reported fatal generalized infections occur in apparently well nourished children. For example, in children with eczema it has long been known that fatal generalized infection is a distinct hazard (Kaposi, 1895). Five of the 13 cases of generalized herpes infection occurring after measles seen in Senegal occurred in well nourished children (Armengoud quoted by Kipps *et al*, 1967). Chickenpox appeared to be associated in case 3. It is possible that in these cases the deficiency in response is a result of abnormality in the skin. Kwashiorkor is associated with gross alterations in the skin which is thinner than normal and flakes over the flexures. Local interferon production in the skin has been shown to be important in the healing of experimental herpes infection in mice (Sydiskis and Schultz, 1966) and it could be that this is a contributory factor to the sensitivity of children with kwashiorkor.

I should like to thank the clinicians and pathologists concerned with these patients for access to their records, and to Professor F. O. MacCallum of Oxford University, England; Professor D. MacKenzie of Cape Town, South Africa; and Professor M. S. R. Hutt, of Makerere, Uganda, for their help and advice. Dr B. Henderson, of the East African Virus Research Institute, Entebbe, Uganda, did the tissue culture.

References

- Becker, W. B. (1966). The epidemiology of herpes virus infection in three racial communities in Cape Town. *S. Afr. med. J.*, **40**, 109-111.
- Becker, W. B., Naudé, L. du T., Kipps, A., and MacKenzie, D. (1963). Virus studies in disseminated herpes simplex infections. *S. Afr. med. J.*, **37**, 74-76.
- Coetzee, J. N. (1955). The epidemiology of herpes simplex in the Pretoria Bantu population. *S. Afr. J. Lab. clin. Med.*, **1**, 52-56.
- Cohen, S., and Hansen, J. D. L. (1962). Metabolism of albumin and γ globulin in Kwashiorkor. *Proc. Nutr. Soc. Sth. Afr.*, **3**, 26-31.
- Dowdle, W. R., Nahmias, A. J., Harwell, R. W., and Pauls, F. P. (1967). Association of antigenic type of herpes virus hominis with site of viral recovery. *J. Immunol.*, **99**, 974-980.
- Dudgeon, J. A. (1950). A complement fixation test for herpes simplex infections. *J. clin. Path.*, **3**, 239-247.
- Harland, P. S. E. G., and Brown, R. E. (1965). Tuberculin sensitivity following B.C.G. vaccination in undernourished children. *E. Afr. med. J.*, **42**, 233-238.
- Hass, G. M. (1935). Hepato-adrenal necrosis with intranuclear inclusion bodies. *Amer. J. Path.*, **11**, 127-142.
- Kaposi, M. (1895). *Pathology and Treatment of Disease of the Skin*, p. 346. Wood, New York.
- Kipps, A., Becker, W., Wainwright, J., and MacKenzie, D. (1967). Fatal disseminated primary herpes virus infection in children: epidemiology based on 93 non-neonatal cases. *S. Afr. med. J.*, **41**, 647-651.
- Lloyd, A. P. C. (1968). Tuberculin test in malnourished children. *Brit. med. J.*, **3**, 529-531.
- Love, R., and Wildy, P. (1963). Cytochemical studies of the nucleoproteins of HeLa cells infected with herpes virus. *J. cell. Biol.*, **17**, 237-254.
- Ruchman, I., and Dodd, K. (1950). Recovery of herpes simplex virus from the blood of a patient with herpetic rhinitis. *J. Lab. clin. Med.*, **35**, 434-439.
- Scott, T. F. McN. (1957). Epidemiology of herpetic infections. *Amer. J. Ophthal.*, **43**, April, Part 2, 134-147.
- Sydiskis, R. J., and Schultz, I. (1966). Interferon and antibody production in mice with herpes simplex skin infections. *J. infect. Dis.*, **116**, 455-460.
- Woodall, J. P., Williams, M. C., Simpson, D. I. H., and Haddow, A. J. (1965). The isolation in mice of strains of herpes virus from Burkitt tumours. *Europ. J. Cancer*, **1**, 137-140.
- World Health Organisation Expert Committee (1965). Nutrition and infection. *Wld. Hlth. Org. Techn. Rep. Ser.*, **314**, 16.
- Zuelzer, W. W., and Stuhlberg, C. S. (1952). Herpes simplex virus as the cause of fulminating visceral disease and hepatitis in infancy. *Amer. J. dis. Child.*, **83**, 421-439.

Addendum

DEMONSTRATION OF HERPES SIMPLEX VIRAL ANTIGEN BY IMMUNOFLOUORESCENCE
As Sabin and Messori (1961) showed that indirect immunofluorescence will detect the antigen of herpes simplex virus in formalin-fixed tissue, this technique was applied to material from the cases described above, in the hope of getting

additional confirmation of the diagnosis. Since there is little information on stability of the antigen under prolonged storage, particularly in the tropics, the presence of herpes infection would not be excluded by a failure to show specific fluorescence in tissues which had been fixed for one to six years.

MATERIALS AND METHOD

Rabbit sera

Rabbits were immunized by repeated injections of RK 13 cells infected with a type 1 herpes simplex virus. Normal rabbit serum was used for the control staining. As a check on specificity further sections were stained with antiherpes rabbit serum which had been absorbed with either normal BHK 21 cells or herpes-infected BHK 21 cells. This latter absorption abolished the specific staining. Sera diluted 1:20 were applied to sections for one hour.

Anti-rabbit globulin

This, conjugated with fluorescein (Nordic Diagnostics, Holland), diluted 1:80, was applied for 20 minutes.

Microscopy

The preparations were examined on a Vickers Patholette microscope, with iodine-quartz lamp, Barr & Stroud interference filter as primary and Schott OG.515 as secondary filter.

RESULTS

Staining was considered specific if a cell, or group of cells, fluoresced with immune serum in the middle layer and did not fluoresce with normal serum, or antigen-adsorbed immune serum.

Case 1

No specific staining was seen in liver. In skin there were numerous vesicles, but no specific staining was observed.

Case 2

In liver scattered groups of cells showing specific staining, and in adrenal there were areas of diffuse specific staining in the cortex.

Case 3

No specific staining was seen in liver or adrenal.

Case 4

Many patches of liver cells showed specific staining, and in adrenal there were areas of necrosis with specifically stained cells at their edges in the cortex.

Case 5

In liver there were scattered groups of cells showing specific staining, mostly in portal tracts. In adrenal there were patches of clearly de-