

Detection of Epstein-Barr Virus DNA in Langerhans Cell Histiocytosis

Maliheh Khoddami,¹ Seyed Alireza Nadji,² Paria Dehghanian,^{3,*} Mahsa Vahdatinia,⁴ and Ahmad Reza Shamshiri⁵

¹Department of Pathology, Pediatric Pathology Research Center, Shahid Beheshti University of Medical Sciences, Tehran, IR Iran

²Virology Research Center, National Research Institute of Tuberculosis and Lung Diseases, Shahid Beheshti University of Medical Sciences, Tehran, IR Iran

³Department of Pathology, Pediatric Infectious Disease Research Center, Mofid Children's Hospital, Shahid Beheshti University of Medical Sciences, Tehran, IR Iran

⁴Department of Pathology, Shahid Beheshti University of Medical Sciences, Tehran, IR Iran

⁵Department of Community Oral Health, Dental Research Center, Dentistry Research Institute, School of Dentistry, Tehran University of Medical Sciences, Tehran, IR Iran

*Corresponding author: Paria Dehghanian, Department of Pathology, Pediatric Infectious Disease Research Center, Mofid Children's Hospital, Shahid Beheshti University of Medical Sciences, Tehran, IR Iran. Tel/Fax: +98-212227035, E-mail: Paria_email@yahoo.com

Received 2015 March 2; Revised 2015 June 12; Accepted 2015 July 11.

Abstract

Background: Langerhans cell histiocytosis (LCH) is a rare histiocytic proliferation of unknown etiology. It is characterized by granuloma-like proliferation of Langerhans-type dendritic cells and mainly affects young children. Although multiple investigators have suggested the possible role of viruses, such as Epstein-Barr virus (EBV), human herpesvirus-6 (HHV-6), Herpes simplex virus (HSV) types 1 and 2, and Cytomegalovirus (CMV) in the pathogenesis of LCH, it remains, however, debated.

Objectives: The EBV infection is reported to be associated with LCH. Nevertheless, no report could be found about involved Iranian children in English medical literature. In this study, we investigated the presence of EBV in Iranian children with LCH.

Patients and Methods: In this retrospective study, in which we investigated the prevalence of presence of EBV DNA in LCH, using paraffin-embedded tissue samples of 30 patients with LCH and 30 age and tissue-matched controls, who were operated for reasons other than infectious diseases (between the years 2002 and 2012), by real-time polymerase chain reaction (RT-PCR) method, in the department of pediatric pathology. No ethical issues arose in the study, because only the pathology reports were reviewed, retrospectively, and the patients were anonymous.

Results: There was a significant difference in prevalence of EBV presence between patients and controls. The EBV was found by RT-PCR in 19 (63.33%) out of 30 patients and only in eight (26.7%) of 30 control samples. The $P=0.004$, was calculated using chi-square test (OR: 4.75; 95% CI: 1.58–14.25).

Conclusions: Our study is the first investigation performed on patients with LCH and its possible association with EBV in Iran. Considering the $P=0.004$, which is statistically significant, the findings do support the hypothesis of a possible role for EBV in the pathogenesis of LCH. These results are in accordance with several previous investigations, with positive findings.

Keywords: Histiocytosis, Langerhans-Cell, Epstein-Barr Virus Infections, Polymerase Chain Reaction, Dendritic Cells, Cell Proliferation

1. Background

Clonal proliferation of histiocytes was first reported in Langerhans cell histiocytosis (LCH) by William et al., in 1994 (1). Langerhans cells are a type of non-lymphoid mononuclear cells that are involved in inflammatory responses and also, in neoplastic processes. They are immature dendritic cells, which express lysosomal enzymes, CD1a and S100 protein and, ultrastructurally, contain the racket shaped organelles of Birbeck granules (2). The etiology of LCH is unknown. However, in addition to other environmental factors, a possible etiologic link between viruses or vaccination and LCH has been proposed (3, 4). The Cytomegalovirus (CMV), which can infect dendritic cells and Langerhans cells (5-7), was detected in 30% of LCH patients by Kawakubo et al. (8), indicating that the

release of cytokines stimulates Langerhans cell growth and induction of LCH.

A series of studies, from various parts of the world, have reported the association of Epstein-Barr virus (EBV) infection with several malignancies and LCH, representing a possible etiologic role or contribution to its pathophysiology (3, 4, 9-12). However, other studies have failed to support these findings and the possible etiologic role of EBV and other viruses in LCH remains debated (13-16). The possible association of LCH and viruses has not been previously investigated in Iranian children.

2. Objectives

Considering the fact that vaccination or early diagnosis

and treatment of EBV, could be of importance in the management of LCH, we investigated the presence of EBV in Iranian children with LCH.

3. Patients and Methods

3.1. Patients and Controls

Formalin-fixed, paraffin-embedded (FFPE) tissue samples of 30 patients, with pathologic diagnosis of LCH, were extracted from the archive of the Pathology Department of Mofid Children's Hospital in Tehran, Iran, (one of the national referral centers) for a 10-year period (2002 – 2012). The diagnosis of LCH was made by a pediatric pathologist, using the histological criteria, mentioned in the pathology textbooks, i.e. granulomas composed of Langerhans cells with typical grooved nuclei, mixed with eosinophils and other inflammatory cells. The diagnoses were confirmed using immunohistochemical technique for CD1a, S100 protein and CD68, when available. After examination of the slides by light microscopy, the tissues with adequate amount of tumoral tissue were used in the study and tissues with too small tumors were excluded. All patients were Iranian and the age ranged between 2 months and 10 years. Thirty tissue samples, with non-LCH diagnosis, who were operated for reasons, other than infectious diseases, were also selected from the files of the Pathology Department (between the years 2002 and 2012), as controls (age and tissue-matched to LCH cases). These patients were operated for reasons such as hemangioma, cystic hygroma, osteochondroma, dermatitis, emphysema, pilonidal disease, soft tissue cysts, enlarged reactive nodes, anal fissure etc. The criterion for inclusion of tissue in control group was absence of clinical and microscopic evidence for LCH or any other tumor.

3.2. Paraffin-Embedded Tissue Section Preparation and DNA Extraction

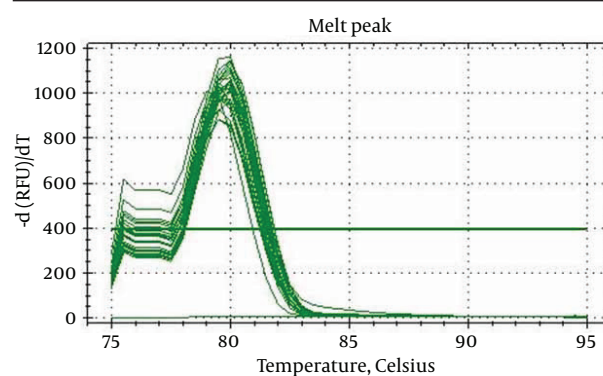
The 5 µm-thick tissue sections were cut from paraffin-embedded blocks, on a microtome, and put into sterile screw-cap tubes. It is necessary to completely remove the embedding material before DNA extraction. The xylene and alcohol solutions were used to deparaffinization and rehydration of the tissue sections. Then, the sections were lysed by a tissue lysis buffer and proteinase K. The samples were subjected to DNA extraction, when the tissues were dissolved. The DNA was extracted from lysed-tissue sample, according to the company's instructions (RTP® DNA/ RNA Virus Mini Kit procedure; Stratec Molecular GmbH, Berlin, Germany). The extracted nucleic acids were stored at -20°C, until they were tested by polymerase chain reaction (PCR).

3.3. Polymerase Chain Reaction

After quality control of the extracted DNA, by using SybrGreen Real-Time PCR (RT-PCR)-Melting curve for beta globin gene (Figure 1), the TaqMan method was applied

to detect EBV genome, as qualitative RT-PCR (Figure 2). To detect EBV, RT-PCR was performed using BamHIW EBV sequence primer sets, amplifying 84 bp gene region of the virus genome (ebv-f ; 5'-GCAGCCGCCAGTCTCT-3'), (ebv-r; 5'-ACAGACAGTGCACAGGAGCCT-3'), with an internal probe (ebv-p; 5'-FAM- AAAAGCTGGCGCCCTTGCCCTG -BHQ1-3') (17). The amplification was performed in reaction volumes of 20 µL, under the following conditions: first, the samples underwent denaturation at 94°C, for 10 minutes, followed by denaturation at 94°C, for 10 seconds, followed by annealing and extension at 60°C, for one minute, repeated for 50 cycles. The RT-PCR System CFX-96 (Bio-Rad Laboratories, Hercules, CA, USA) with HS Prime Taq Premix TaqMan reagent (Genetbio, Chungcheongnam-Do, South Korea) was used in RT-PCR assay. The limit detection of 15 genome copies of EBV, per reaction, was determined by the RT-PCR assay, using the serial dilutions of AmpliRun® EBV DNA control (Vircell S.L., Granada, Spain).

Figure 1. Beta-Globin Gene SybrGreen Real-Time Polymerase Chain Reaction-Melting Curve



The graph shows that the melting temperature of Beta-globin PCR product is around 80°C.

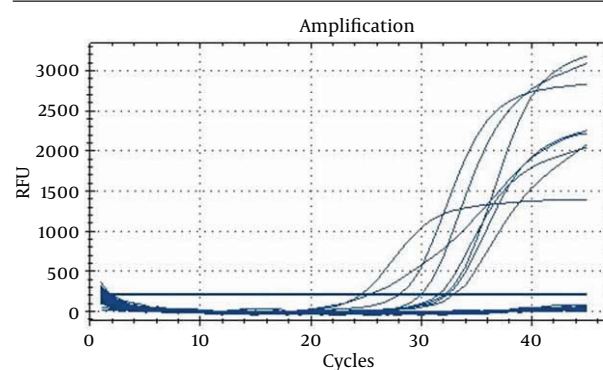


Figure 2. Epstein-Barr Virus Real-Time Polymerase Chain Reaction Using BamHIW Sequence Primer Sets

3.4. Statistical and Ethical Considerations

The achieved data were compared by using Chi-Square or Fisher's exact test. A $P < 0.05$ was considered to indi-

cate statistical significance. In this study, no ethical issues were involved. Only the pathology reports were reviewed, retrospectively, and the patients were anonymous. The articles used as references are valid and the data taken are reported unchanged.

4. Results

Thirty patients with a pathologic diagnosis of LCH were included in this study. All patients were Iranian (16 male and 14 female) and the age ranged between 2 months and 10 years. Age, sex and biopsy site of all patients are shown in Table 1. Thirty tissue samples, with non LCH diagnosis, were also selected, as controls (age and tissue-matched to LCH cases). The EBV DNA was detected qualitatively, in 19 LCH patients (63.33%) out of 30 cases (positive results in 63.33% and negative results in 36.67%). In the control group, we detected EBV in eight (26.7%) samples, out of a total of 30 (positive results in 26.7% and negative results in 73.3% of controls) with an OR: 4.75; 95%CI: 1.58 – 14.25 and $P = 0.004$, which shows a significant difference of EBV prevalence results between LCH patients and controls. The LCH patients, with positive result for EBV presence, included 11 male and eight female patients (Table 1).

Table 1. Age, Sex and Biopsy Site of Patients

Age	Gender	Clinic /Biopsy Site	EBV
2, y	Female	Lymph node	+
2, y	Male	Mediastinal and neck mass	+
10, mo	Male	Skin	-
1, y	Male	Soft tissue, scalp mass	+
2, y	Male	Frontal bone	+
11, mo	Male	Mastoid bone	+
1, y	Female	Skin, chest wall	+
3, y	Male	Iliac bone	+
6, y	Female	Proximal tibia	+
10, y	Male	Skull and soft tissue	-
2, y	Female	Parietal bone and soft tissue	-
2, y	Male	Skin	+
8, y	Male	Soft tissue scalp	+
2, y	Female	Soft tissue submandibular	-
2, y	Male	Vertebral bone	+
7, y	Male	Clavicle and soft tissue	+
15, mo	Male	Abdominal mass	-
4, y	Female	Base of skull	+
2.5, y	Female	Right lobe of lung	+
8, y	Female	Skin, abdomen	-
2, mo	Female	Soft tissue	+
2, y	Male	Soft tissue scalp	+
3, y	Female	Frontal bone and soft tissue	-
3, y	Female	Soft tissue scalp	-
2, y	Female	Metatarsal bone	-
16, mo	Male	Skin	+
4, mo	Female	Skin	+
1, y	Female	skin	+
1.5, y	Male	Soft tissue scalp	-
7, y	Male	Soft tissue perianal	-

5. Discussion

Considering the fact that LCH could have an etiologic association with viruses, as suggested by previous studies (3, 4, 8, 10), this study was conducted due to the lack of information about such a possible link in Iranian children, in English medical literature. The LCH, a clonal proliferation of histiocytes, is a rare disease, mostly affecting children younger than five years and presents as three overlapping clinical syndromes (Letterer-Siwe disease, Hand-Schüller-Christian disease and solitary eosinophilic granuloma) (2). Histological findings are the same, in various tissues, characterized by granulomas composed of a mixture of Langerhans cells, macrophages, eosinophils, multinucleated giant cells and lymphocytes (18, 19). The prognosis of LCH is influenced by the involved organs and the age. Most adult patients, with lung involvement, usually have an indolent course of regress, whereas children need to be treated by steroids and chemotherapy (20-23).

Although the etiology is still unknown, however, environmental agents and viruses, especially EBV, or vaccination, have been proposed to play a role in the pathogenesis of LCH (3, 4). The role of EBV, as the etiologic agent of several malignancies is known and Herpes viruses are shown to be responsible for persistent infection (9, 11, 12). In addition, EBV and CMV are considered to be responsible for the hemophagocytic syndromes in human, with several inherited immunodeficiencies (24, 25). The EBV is shown to invade monocytes and Langerhans cells, during the course of infection (26, 27).

Kawakubo et al. (8) detected CMV in lesional Langerhans cells, in 30% of 29 patients, by immunocytochemistry (IHC), in situ hybridization (ISH), and PCR and suggested that release of cytokines could stimulate proliferation of Langerhans cells and induce LCH. The associations of EBV infection with LCH have been investigated in different reports, suggesting a possible etiologic role or contribution to its pathophysiology (3, 4, 10). McClain et al. (14) findings, however, did not support the etiologic role for adenovirus, CMV, EBV, HSV, HHV-6, HIV, human T-cell leukemia virus types I and II and parvovirus, in 56 cases of LCH, using ISH and PCR technique. Jeziorski et al. (13) also failed to find evidence of EBV, CMV, or HHV-6 in the pathogenesis of LCH. The possible etiologic role of EBV and other viruses, in LCH, is still to be proved.

We detected EBV DNA in 19 (63.33%) out of 30 patients with LCH. The positive result in eight of the control samples (26.7%) could be attributed to a coincidence. The $P = 0.004$ and OR: 4.75; 95%CI: 1.58 – 14.25 support the hypothesis of a possible role for EBV in the pathogenesis of LCH disease, which is in concordance with several other results, reported in the literature (3, 4, 10). In previous studies (3, 4, 10, 14, 15) authors declared no limitations and the methods used included serology, IHC, ISH, and PCR. However, IHC and ISH for EBV were not available to be employed in our study and the patients were not checked for

the evidence of EBV infection, serologically (limitations in our study).

The importance of our study is that it is the first study performed in Iran, on this subject. Although we have not confirmed the presence of EBV in the Langerhans cells, by other methods, and the etiologic role of EBV cannot be proved definitively, previous positive results reported in the literature (3, 4, 10), as well as our results, with 63.33% positivity, highly support the possible contribution of EBV in development of LCH. The positive results in previous studies and our study could be of importance, because vaccination or an early diagnosis and treatment of EBV infection could prevent developing LCH in the future.

Acknowledgments

This study was conducted as a dissertation by Dr. Paria Dehghanian, under the supervision of Dr. Maliheh Khoddami, to fulfill the requirements for Pediatric Pathology Fellowship at Shahid Beheshti University of Medical Sciences, Tehran, Iran. We thank Ms. Leila Poos-Ashkan and Pooneh Tavakoli for performing the PCR and Mojgan Shohadai for technical assistance.

Footnotes

Authors' Contribution: Maliheh Khoddami: conception and design, critical revision of the manuscript for important intellectual content, supervision, revision of the manuscript; Seyed Alireza Nadji: supervising and performing PCR tests, revision of the "Materials and Methods"; Paria Dehghanian: corresponding author and drafting of the manuscript; Mahsa Vahdatinia: acquisition of data; Ahmad Reza Shamshiri: statistical analysis of data.

Funding/Support: This study was financially supported by the Pediatric Infectious Disease Research Center, Mofid Children's Hospital, Shahid Beheshti University of Medical Sciences, Tehran, Iran.

References

- Willman CL, Busque L, Griffith BB, Favara BE, McClain KL, Duncan MH, et al. Langerhans' cell histiocytosis (histiocytosis X)-a clonal proliferative disease. *N Engl J Med*. 1994;**331**(3):154-60. doi: 10.1056/NEJM199407213310303. [PubMed: 8008029]
- Weiss L. *Histiocytic and dendritic cell proliferations. Neoplastic hematopathology*. 2001. 2nd ed. Philadelphia: Lippincott Williams & Wilkins; 2001. pp. 1815-45.
- Chen CJ, Ho TY, Lu JJ, Sheu LF, Lee SY, Tien CH, et al. Identical twin brothers concordant for Langerhans' cell histiocytosis and discordant for Epstein-Barr virus-associated haemophagocytic syndrome. *Eur J Pediatr*. 2004;**163**(9):536-9. doi: 10.1007/s00431-004-1493-y. [PubMed: 15243808]
- Sakata N, Toguchi N, Kimura M, Nakayama M, Kawa K, Takemura T. Development of Langerhans cell histiocytosis associated with chronic active Epstein-Barr virus infection. *Pediatr Blood Cancer*. 2008;**50**(4):924-7. doi: 10.1002/pbc.21249. [PubMed: 17474115]
- Hertel L, Lacaille VG, Strobl H, Mellins ED, Mocarski ES. Susceptibility of immature and mature Langerhans cell-type dendritic cells to infection and immunomodulation by human cytomegalovirus. *J Virol*. 2003;**77**(13):7563-74. [PubMed: 12805456]
- Lee AW, Hertel L, Louie RK, Burster T, Lacaille V, Pashine A, et al.

- Human cytomegalovirus alters localization of MHC class II and dendrite morphology in mature Langerhans cells. *J Immunol*. 2006;**177**(6):3960-71. [PubMed: 16951359]
- Senechal B, Boruchov AM, Reagan JL, Hart DN, Young JW. Infection of mature monocyte-derived dendritic cells with human cytomegalovirus inhibits stimulation of T-cell proliferation via the release of soluble CD83. *Blood*. 2004;**103**(11):4207-15. doi: 10.1182/blood-2003-12-4350. [PubMed: 14962896]
- Kawakubo Y, Kishimoto H, Sato Y, Yanagimoto K, Tsuruta T, Ogawa Y, et al. Human cytomegalovirus infection in foci of Langerhans cell histiocytosis. *Virchows Arch*. 1999;**434**(2):109-15. [PubMed: 10071244]
- Ashraf MJ, Makarempour A, Monabati A, Azarpira N, Khademi B, Hakimzadeh A, et al. Comparison between presence of Epstein-Barr virus in nodal and extra nodal diffuse large B cell lymphoma of head and neck, an Iranian experience. *Iran Red Crescent Med J*. 2012;**14**(12):764-70. doi: 10.5812/ircmj.1302. [PubMed: 23482890]
- Shimakage M, Sasagawa T, Kimura M, Shimakage T, Seto S, Kodama K, et al. Expression of Epstein-Barr virus in Langerhans' cell histiocytosis. *Hum Pathol*. 2004;**35**(7):862-8. [PubMed: 15257550]
- Purtillo DT. Epstein-Barr-virus-induced oncogenesis in immunodeficient individuals. *Lancet*. 1980;**3**(8163):300-3. [PubMed: 6101750]
- Young LS, Rickinson AB. Epstein-Barr virus: 40 years on. *Nat Rev Cancer*. 2004;**4**(10):757-68. doi: 10.1038/nrc1452. [PubMed: 15510157]
- Jeziorski E, Senechal B, Molina TJ, Deveze F, Luerue-Ville M, Morand P, et al. Herpes-virus infection in patients with Langerhans cell histiocytosis: a case-controlled sero-epidemiological study, and in situ analysis. *PLoS One*. 2008;**3**(9):e3262. doi: 10.1371/journal.pone.0003262. [PubMed: 18810271]
- McClain K, Jin H, Gresik V, Favara B. Langerhans cell histiocytosis: lack of a viral etiology. *Am J Hematol*. 1994;**47**(1):16-20. [PubMed: 8042610]
- Schenka AA, De Angelo Andrade LA, Amstalden EM, Cintra ML, Vassallo J, Cardinali IA, et al. Langerhans cell histiocytosis and its relationship with Epstein-Barr virus. *Hum Pathol*. 2006;**37**(11):1508-9. doi: 10.1016/j.humpath.2006.07.008. [PubMed: 17027063]
- Brousset P. Epstein-Barr virus and Langerhans cell histiocytosis. *Hum Pathol*. 2004;**35**(12):1573-4. [PubMed: 15619220]
- Fan H, Kim SC, Chima CO, Israel BF, Lawless KM, Eagan PA, et al. Epstein-Barr viral load as a marker of lymphoma in AIDS patients. *J Med Virol*. 2005;**75**(1):59-69. doi: 10.1002/jmv.20238. [PubMed: 15543571]
- Lichtenstein L. Histiocytosis X; integration of eosinophilic granuloma of bone, Letterer-Siwe disease, and Schuller-Christian disease as related manifestations of a single nosologic entity. *AMA Arch Pathol*. 1953;**56**(1):84-102. [PubMed: 13057466]
- A multicentre retrospective survey of Langerhans' cell histiocytosis: 348 cases observed between 1983 and 1993. The French Langerhans' Cell Histiocytosis Study Group. *Arch Dis Child*. 1996;**75**(1):17-24. [PubMed: 8813865]
- Ladisch S. Langerhans cell histiocytosis. *Curr Opin Hematol*. 1998;**5**(1):54-8. [PubMed: 9515204]
- Laman JD, Leenen PJ, Annels NE, Hogendoorn PC, Egeler RM. Langerhans-cell histiocytosis 'insight into DC biology'. *Trends Immunol*. 2003;**24**(4):190-6. [PubMed: 12697451]
- Ninaber M, Dik H, Peters E. Complete pathological resolution of pulmonary Langerhans cell histiocytosis. *Respir Case Rep*. 2014;**2**(2):76-8. doi: 10.1002/rccr.2.54. [PubMed: 25473573]
- Berber I, Erkurt MA, Kuku I, Koroglu M, Kaya E, Unlu S. A rare disease in adult: Langerhans cell histiocytosis. *World J Oncology*. 2013;**4**(3):165-8. doi: 10.4021/wjon663w.
- Menasche G, Feldmann J, Fischer A, de Saint Basile G. Primary hemophagocytic syndromes point to a direct link between lymphocyte cytotoxicity and homeostasis. *Immunol Rev*. 2005;**203**:165-79. doi: 10.1111/j.0105-2896.2005.00224.x. [PubMed: 15661029]
- Rigaud S, Fondaneche MC, Lambert N, Pasquier B, Mateo V, Soulas P, et al. XIAP deficiency in humans causes an X-linked lymphoproliferative syndrome. *Nature*. 2006;**444**(7115):110-4. doi: 10.1038/nature05257. [PubMed: 17080092]

26. Tugizov S, Herrera R, Velupillai P, Greenspan J, Greenspan D, Palefsky JM. Epstein-Barr virus (EBV)-infected monocytes facilitate dissemination of EBV within the oral mucosal epithelium. *J Virol*. 2007;**81**(11):5484-96. doi: 10.1128/JVI.00171-07. [PubMed: 17376918]
27. Walling DM, Ray AJ, Nichols JE, Flaitz CM, Nichols CM. Epstein-Barr virus infection of Langerhans cell precursors as a mechanism of oral epithelial entry, persistence, and reactivation. *J Virol*. 2007;**81**(13):7249-68. doi: 10.1128/JVI.02754-06. [PubMed: 17376908]