

# Spontaneous Iliopsoas Tendon Tear: A Rare Cause of Hip Pain in the Elderly

Geriatric Orthopaedic Surgery  
& Rehabilitation  
2016, Vol. 7(1) 30-32  
© The Author(s) 2016  
Reprints and permission:  
sagepub.com/journalsPermissions.nav  
DOI: 10.1177/2151458515627309  
gos.sagepub.com



Manolo Rubio, MD<sup>1</sup>, Mary Rodriguez, MD<sup>1</sup>,  
Soumya Patnaik, MD<sup>1</sup>, and Peter Wang, MD<sup>2</sup>

## Abstract

Hip pain is one of the most common reasons for the elderly to present to the emergency department, and the differential diagnosis spectrum is vast. Iliopsoas injury is a relatively uncommon condition that may present with hip or groin pain. It is usually seen in athletes due to trauma, particularly flexion injuries. However, spontaneous iliopsoas tendon tear is extremely rare, and only a small number of cases have been reported; it has an estimated prevalence of 0.66% in individuals from 7 to 95 years. Risk factors include aging, use of steroids, and chronic diseases. Magnetic resonance imaging (MRI) using its high soft-tissue contrast resolution remains the most valuable imaging modality. A prompt diagnosis and treatment, which is usually conservative, is important to improve the quality of life in this group of patients. We describe a case of spontaneous iliopsoas tendon tear in an elderly woman.

## Keywords

hip pain, iliopsoas, elderly, geriatrics, tendon rupture, MRI

## Background

Hip pain is one of the most common reasons for the elderly to present to the emergency department, and the differential diagnosis spectrum is vast.<sup>1</sup> The most common etiologies of hip pain encompass degenerative joint disease and bone lesions, such as fractures of the pelvic bones and femoral neck, and these conditions are usually diagnosed by conventional radiographs.<sup>2</sup> However, there are other less common and even rare conditions that can present with hip pain, such as iliopsoas tendon (IPT) injury. The IPT is a myotendinous complex composed of a tendon arising from the psoas major muscle, a smaller accessory tendon and the proper muscle fibers, both arising from the medial and the lateral fibers of the iliacus muscle, respectively.<sup>3</sup> Iliopsoas injury is a relatively uncommon condition; it may present with hip or groin pain, inability to bear weight, and weakness of hip flexion.<sup>4</sup> This condition is usually seen in athletes as a consequence of trauma.<sup>5</sup> Spontaneous IPT tear is extremely rare, and only a small number of cases have been reported.<sup>4</sup> We describe a case of spontaneous IPT tear in an elderly African American female.

## Reported Case

An 84-year-old African American female presented to the emergency department complaining of severe (5/10) and sharp left hip pain for the past 3 days prior to admission; the pain was radiated to the left groin. The hip pain was severe enough to impair her ambulation. Additionally, the patient complained of

generalized weakness and fatigue, and these symptoms were associated with hyporexia. Her medical history is significant for hypertension, atrial fibrillation (not in anticoagulation due to risk of fall), end-stage renal disease on hemodialysis, and hyperlipidemia. She denies any use of alcohol, tobacco, or drug abuse. Physical examination was remarkable for decreased mobility in the left lower extremity with consequent ambulatory dysfunction; both sensation and pulses were intact in such extremity.

As part of the initial workup, the patient underwent several imaging studies, including a Doppler ultrasound in the left lower extremity and pelvic X-ray series. Both studies did not show any pathologic finding that could explain the hip pain.

The patient was admitted for further workup. A computed tomography of the pelvis was performed, demonstrating an asymmetric soft-tissue edema in the left pelvis and thigh and also involvement of the superficial deep fascia and enlargement of the iliopsoas muscle. These findings raised the suspicion of a less common musculoskeletal pathology; for this reason orthopedic surgery was consulted and a recommendation for a more specific imaging study was made. Thus, a left lower extremity magnetic resonance (MRI) was performed (Figure 1 A-C),

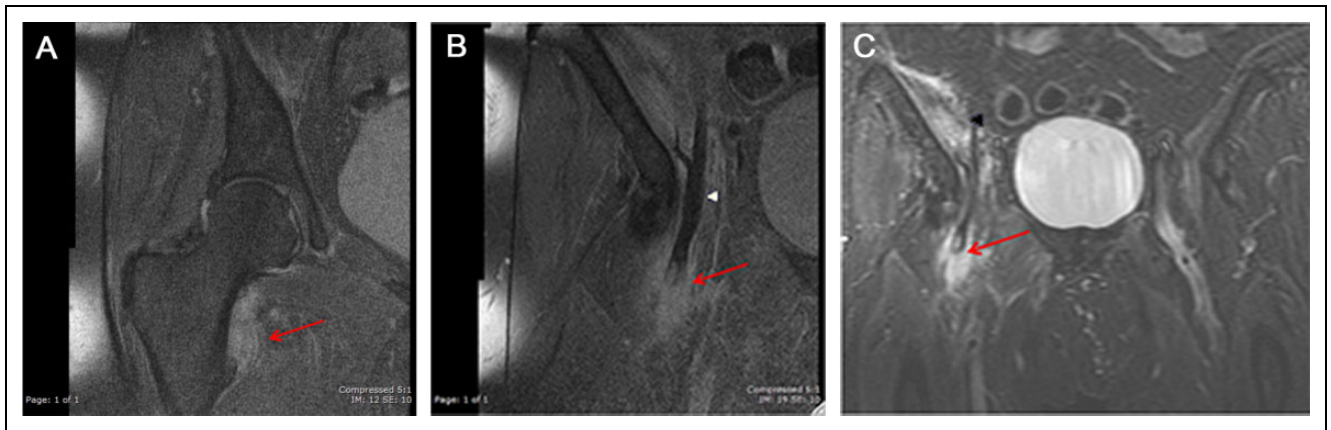
<sup>1</sup> Department of Medicine, Einstein Medical Center, Philadelphia, PA, USA

<sup>2</sup> Department of Radiology, Einstein Medical Center, Philadelphia, PA, USA

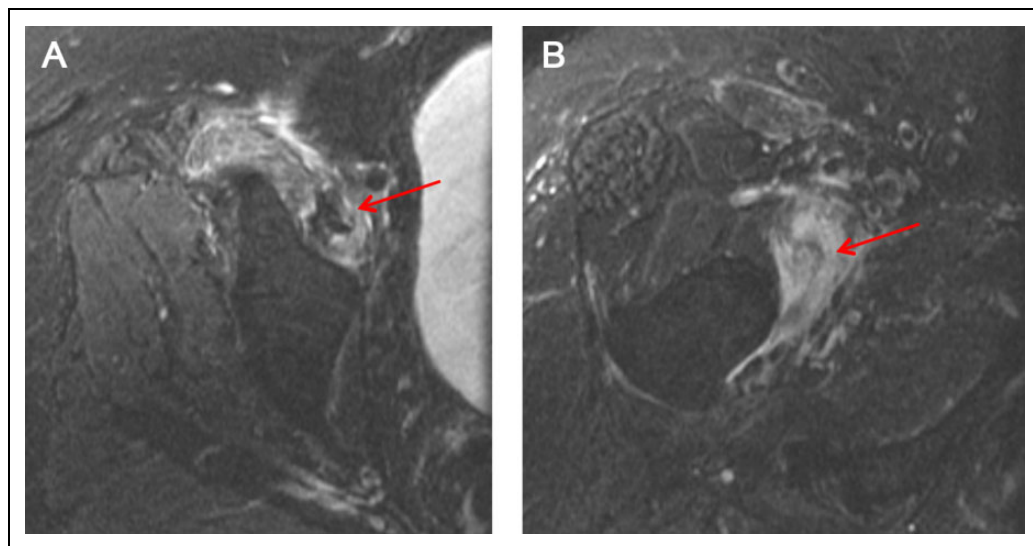
## Corresponding Author:

Manolo Rubio, Department of Medicine, Einstein Medical Center, 5501 Old York Rd, Philadelphia, PA 19141, USA.

Email: rubiomano@einstein.edu



**Figure 1.** MRI of hip and pelvis. A, Torn iliopsoas tendon (high signal edema), no dark signal tendon at lesser trochanter. B, Coronal proton density fat sat shows torn distal end of tendon with edema (arrow). Intact portion of tendon is dark signal (arrowhead). C, Coronal STIR shows torn distal end of tendon with edema (arrow). Edema in iliacus from tear and strain (arrowhead). 228 × 69 mm (72 × 72 DPI). MRI indicates magnetic resonance imaging; STIR, short tau inversion recovery.



**Figure 2.** MRI of hip and pelvis. A, Axial STIR, edema in iliacus. B, Axial STIR, edema and torn iliopsoas tendon at lesser trochanter. 146 × 74mm (72 × 72 DPI). MRI indicates magnetic resonance imaging; STIR, short tau inversion recovery.

demonstrating a torn iliopsoas tendon at lesser trochanter (Figure 2A and B). With these findings, a diagnosis of spontaneous IPT tear was made. A careful, individualized, and multidisciplinary approach was performed, and a conservative management was found to be the most appropriate choice for our patient. Such management included physical rehabilitation and adequate pain control in an effort to improve her quality of life. It is important to mention that no surgical intervention was recommended. With this therapeutic approach, the patient experienced an improvement in ambulation and a progressive resolution of pain.

## Discussion

Spontaneous tear of IPT is a rare condition, and only a small number of cases have been reported.<sup>4,6</sup> Only IPT injuries

including traumatic and atraumatic etiologies have an estimated prevalence of 0.66%; this was found in a study including 32 individuals with ages ranging between 7 and 95 years.<sup>7</sup> The risk factors predisposing to IPT injuries include aging, chronic use of steroids, chronic diseases, and metastatic bone disease.<sup>8</sup> Women older than 65 years are at higher risk of spontaneous complete IPT tear.<sup>9</sup> Magnetic resonance imaging using high soft-tissue contrast resolution remains the most valuable imaging modality (after radiographs) to evaluate osseous structures and soft tissues in this clinical scenario. A complete IPT tear is diagnosed when there is interruption of the tendon fibers and muscle attachments; other important findings include proximal muscle swelling and edema. However, MRI is not routinely performed, and therefore this condition is often undiagnosed.<sup>10</sup> The evidence available suggests the treatment of spontaneous IPT tear to be conservative, and it includes physical

rehabilitation and pain control without the need for surgical intervention.<sup>4,7,11</sup> The prognosis is favorable, with a significant improvement in symptoms and functions. We encourage a high degree of suspicion for spontaneous IPT tear in elderly patients presenting with hip or groin pain in the context of a chronic disease. If an initial imaging evaluation (including conventional radiographs and ultrasound) fails to demonstrate a clear etiology for the pain, an MRI should be performed. If there is a contraindication for an MRI, ultrasound imaging could be used.<sup>11</sup> This is particularly important if there is a suspicion for IPT tear, since prompt diagnosis and treatment are important to increase the odds of recovery and improve the quality of life in this group of patients.<sup>4,11</sup>

### Declaration of Conflicting Interests

The author(s) declared no potential conflicts of interest with respect to the research, authorship, and/or publication of this article.

### Funding

The author(s) received no financial support for the research, authorship, and/or publication of this article.

### References

1. Kohaus H, Peters P, Strunk E. Rupture of the iliopsoas muscle. Symptoms and differential diagnosis (author's transl) [Article in German]. *Unfallheilkunde*. 1980;83(3):127-129.
2. Afra R, Boardman DL, Kabo JM, Eckardt JJ. Avulsion fracture of the lesser trochanter as a result of a preliminary malignant tumor of bone. A report of four cases. *J Bone Joint Surg Am*. 1999;81(9):1299-1304.
3. Hanson P, Aagaard P, Magnusson SP. Biomechanical properties of isolated fascicles of the Iliopsoas and Achilles tendons in African American and Caucasian men. *Ann Anat*. 2012;194(5):457-460.
4. Lecouvet FE, Demondion X, Leemrijse T, Vande Berg BC, Devogelaer JP, Malghem J. Spontaneous rupture of the distal iliopsoas tendon: clinical and imaging findings, with anatomic correlations. *Eur Radiol*. 2005;15(11):2341-2346.
5. Blankenbaker DG, De Smet AA. Hip injuries in athletes. *Radiol Clin North Am*. 2010;48(6):1155-1178.
6. Bui KL, Sundaram M. Radiologic case study: iliopsoas tendon rupture. *Orthopedics*. 2008;31(10).
7. Bui KL, Ilaslan H, Recht M, Sundaram M. Iliopsoas injury: an MRI study of patterns and prevalence correlated with clinical findings. *Skeletal radiology*. 2008;37(3):245-249.
8. James SL, Davies AM. Atraumatic avulsion of the lesser trochanter as an indicator of tumour infiltration. *Eur Radiol*. 2006;16(2):512-514.
9. Wilson JJ, Furukawa M. Evaluation of the patient with hip pain. *Am Fam Physician*. 2014;89(1):27-34.
10. Verbeeten KM, Hermann KL, Hasselqvist M, et al. The advantages of MRI in the detection of occult hip fractures. *Eur Radiol*. 2005;15(1):165-169.
11. Emam M, Farmakidis C, Lee SW, Wainapel SF. Spontaneous iliopsoas tendon rupture: an uncommon cause of hip pain in elderly patients. *PM R*. 2015;s1934-s1482(15)00916-8.