

Case reports

A commentary on the following two case reports appears on pages 1222-3.

Treatment of adenoviral pneumonitis with intravenous ribavirin and immunoglobulin

I Sabroe, J McHale, D R Tait,
W A Lynn, K N Ward, S Shaunak

Abstract

A 67 year old woman developed a severe adenoviral pneumonitis whilst receiving immunosuppressive therapy. She showed clinical and radiological evidence of a response to treatment with nebulised and intravenous ribavirin and intravenous pooled normal human immunoglobulin. To our knowledge this is the first time that such a therapeutic approach has been used in the treatment of a condition which normally carries a very high mortality.

(*Thorax* 1995;50:1219-1220)

Keywords: pneumonitis, ribavirin, adenovirus.

A 67 year old woman with mixed essential cryoglobulinaemia and an associated glomerulonephritis was started on immunosuppressive therapy with prednisolone 30 mg daily and cyclophosphamide 100 mg daily. Following a good clinical response she became leukopenic (white cell count $2.8 \times 10^9/l$), at

which time cyclophosphamide was discontinued. Prednisolone was continued at a dose of 30 mg/day.

Two weeks later she presented with generalised malaise, mild shortness of breath, a dry cough, and intermittent fevers up to 40°C. Scanty crepitations were heard at both lung bases. Despite a normal chest radiograph she was hypoxaemic with a P_{aO_2} of 8.5 kPa breathing air. A clinical diagnosis of a pneumonitis was made and bronchoalveolar lavage performed. Rapid immunofluorescence for respiratory viruses and *Pneumocystis carinii* was negative, as was a Gram stain and an auramine stain. Microbiological cultures showed no growth. In the absence of an identifiable pathogen it was decided to monitor her closely and not to start antibiotic or antiviral treatment. Forty eight hours later she was profoundly hypoxaemic with an oxygen saturation of 54% breathing air. The chest radiograph showed extensive alveolar shadowing in keeping with a severe pneumonitis (fig 1). She required ventilation with an F_{iO_2} of 95%, 10 cm positive end expiratory pressure (PEEP), and cardiovascular support with adrenaline. Treatment with high dose erythromycin and imipenem was started. At this time the presence of a cytopathic effect suggestive of adenovirus was noted in the viral tissue cultures which had been inoculated with the bronchoalveolar fluid. The same cytopathic effect was also seen in tissue cultures inoculated with a throat swab taken on the same day that the bronchoscopy was performed. The presence of an adenovirus was confirmed by electron microscopy.

She was commenced on continuous nebulised ribavirin (20 mg/ml ribavirin via small particle generating nebuliser) but remained critically ill. Twenty four hours later intravenous ribavirin (20 mg/kg loading dose fol-

Department of
Infectious Diseases
and Bacteriology,
Royal Postgraduate
Medical School

I Sabroe
W A Lynn
S Shaunak

Division of
Respiratory Medicine
I Sabroe

Division of
Rheumatology
J McHale

Department of
Virology, Royal
Postgraduate Medical
School
D R Tait
K N Ward

Hammersmith
Hospital,
London W12 0NN,
UK

Reprint requests to:
Dr I Sabroe, Department of
Applied Pharmacology,
National Heart and Lung
Institute, Dovehouse Street,
London SW3 6LX, UK.

Received 11 October 1994
Returned to authors
24 November 1994
Revised version received
12 January 1995
Accepted for publication
16 January 1995

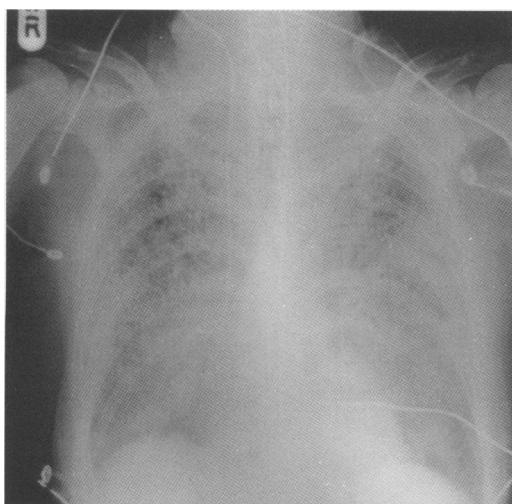


Figure 1 Chest radiograph showing diffuse alveolar shadowing consistent with severe pneumonitis.

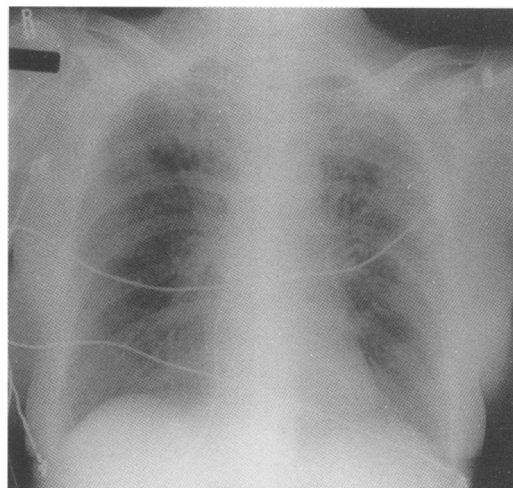


Figure 2 Chest radiograph after treatment with intravenous and nebulised ribavirin showing significant clearing of the pneumonitis.

lowed by 35 mg/kg/day in divided doses for four days and 25 mg/kg/day for two days) and pooled normal human immunoglobulin (total dose 100 g over seven days) were added to her treatment. The nebuliser circuit was continuously monitored for any precipitation of ribavirin, and the circuit filters were changed frequently in accordance with standard recommendations. Her clinical condition and chest radiograph then started to improve rapidly (fig 2) and by day 7 of her admission to the ITU she required only 35% inspired oxygen. She was extubated three days later. Ribavirin was administered for a total of six days intravenously and for seven days via the nebuliser. Multiple microbiological cultures of tracheal aspirate and blood showed no growth. A direct fluorescent antibody stain for *Legionella* on the tracheal aspirate was negative. Erythromycin and imipenem were discontinued after five days. Cultures of bronchoalveolar lavage fluid performed four days after she left the ITU failed to demonstrate the presence of an adenovirus. No adverse effects which could be directly attributed to either intravenous or nebulised ribavirin were recorded during her treatment (for example, decreased haematocrit or thrombocythaemia). In view of her cryoglobulinaemia and subsequent immunosuppression, serological assays for adenovirus were not performed.

Discussion

Viral pneumonitis in immunocompetent patients can be caused by many viruses including respiratory syncytial virus, herpes zoster, cytomegalovirus, influenza A and B, and parainfluenza.¹ Adenovirus infections with a significant mortality ($\leq 15\%$) have been described in military recruits,² but otherwise fatalities from adenoviral infection in the immunocompetent host are rare.

In immunocompromised patients adenoviruses are known to cause several serious syndromes, including haemorrhagic cystitis in bone marrow and renal transplant recipients, hepatitis in liver transplant recipients, and colitis, hepatitis, and meningoencephalitis in patients with AIDS.³ The mortality from adenoviral pneumonitis in these groups is estimated to be 60%.³

Little is known about the treatment of severe adenoviral infections in either the immunocompetent or the immunocompromised host. Isolated case reports suggest a role for nebulised ribavirin in adenoviral pneumonitis,⁴ and in bone marrow transplant recipients adenoviral haemorrhagic cystitis has been reported to respond to intravenous ribavirin.⁵

Ribavirin is a broad spectrum agent which is active in vitro against a number of DNA and RNA viruses including adenovirus.⁶ In the nebulised form it has proven effectiveness in vivo

against respiratory syncytial virus, influenza, and parainfluenza.⁷ Intravenously, ribavirin has been used for the treatment of lassa fever and epidemic haemorrhagic fever with renal syndrome.⁷ Few side effects to ribavirin have been reported when it is administered via either the nebulised or intravenous routes.⁷ When it is nebulised via a ventilator, care must be taken to monitor for drug precipitation in the ventilator circuit and the valve connecting the nebuliser to the inspiratory limb of the circuit. The circuit itself should be filtered in accordance with the recommendations supplied with the ribavirin small particle nebuliser.

Pooled normal human immunoglobulin has been postulated to be a rational therapy for the treatment of adenovirus infections because most adults carry antibodies to multiple serotypes of adenovirus. However, there are case reports to both support and refute the effectiveness of immunoglobulin in this setting.^{8,9}

In our case the patient's outlook was so poor that we decided to treat her with intravenous and nebulised ribavirin therapy as well as with immunoglobulin. Following the start of combination therapy there was a rapid improvement in her oxygenation and in the appearance of the chest radiograph. Although it is possible that her recovery was due to spontaneous resolution of the adenoviral pneumonitis, we believe that the speed and timing of her improvement suggest that this is unlikely. No other pathogen other than adenovirus was found despite extensive investigation, lending support to the idea that this was the point of successful clinical intervention. We believe we have shown that an aggressive approach to the diagnosis of pneumonitis in immunocompromised patients is worthwhile. The administration of ribavirin intravenously and via a nebuliser, with or without immunoglobulin, to patients with adenoviral pneumonitis deserves further evaluation because the mortality without treatment is very high.

- Greenberg SB. Viral pneumonia. *Infect Dis Clin North Am* 1991;5:603-21.
- Dudding BA, Wagner SC, Zeller JA, Gmelich JT, French GR, Top FH Jr. Fatal pneumonia associated with adenovirus type 7 in three military trainees. *N Engl J Med* 1972;286:1289-92.
- Hierholzer JC. Adenoviruses in the immunocompromised host. *Clin Microbiol Rev* 1992;5:262-74.
- Buchdahl RM, Taylor P, Warner JO. Nebulised ribavirin for adenovirus pneumonia (letter). *Lancet* 1985;ii:1070-1.
- Cassano WF. Intravenous ribavirin therapy for adenovirus cystitis after allogeneic bone marrow transplantation. *Bone Marrow Transplant* 1991;7:247-8.
- Sidwell RW, Huffman JH, Khare GP, Allen LB, Witkowski JT, Robins RK. Broad spectrum antiviral activity of virazole: 1- β -D-ribofuranosyl-1,2,4,-triazole-3-carboxamide. *Science* 1972;177:705-6.
- Dollery CT, ed. *Therapeutic drugs*. Volume 2. London: Churchill Livingstone, 1991:R16-20.
- Dagan R, Schwartz RH, Insel RA, Menegus MA. Severe diffuse adenovirus 7a pneumonia in a child with combined immunodeficiency: possible therapeutic effect of human immune serum globulin containing specific neutralising antibody. *Paediatr Infect Dis* 1984;3:246-51.
- Wigger HJ, Blanc WA. Fatal hepatic and bronchial necrosis in adenovirus infection with thymic aplasia. *N Engl J Med* 1966;275:870-4.